CiSE

# Clinics in Shoulder and Elbow

Volume 26

Number 4

December 2023

Editorial

Clavicle midshaft fractures should not be considered an easy surgery: reduction and prebending

Original Articles

Use of custom glenoid components for reverse total shoulder arthroplasty

Inpatient or outpatient total elbow arthroplasty: a comparison of patient populations and 30-day surgical outcomes from the American College of Surgeons National Surgical Quality Improvement Program

Concomitant open distal clavicle excision is associated with greater improvement in range of motion without increased risk of acromial stress fracture after reverse total shoulder arthroplasty: a retrospective cohort study

Classification system for partial distal biceps tendon tears: a descriptive 3-Tesla magnetic resonance imaging study of tear morphology

Effect of cigarette smoking on the maintenance of reduction after treatment of acute acromioclavicular joint dislocation with hook plate fixation

Anatomic total shoulder arthroplasty with a nonspherical humeral head and inlay glenoid: 90-day complication profile in the inpatient versus outpatient setting

Glenohumeral versus subacromial steroid injections for impingement syndrome with mild stiffness: a randomized controlled trial

Plate prebending using a three-dimensional–printed model affords effective anatomical reduction in clavicular shaft fractures

Radiologic and clinical outcomes of an arthroscopic bridging graft for irreparable rotator cuff tears with a modified Mason-Allen stitch using a plantaris tendon autograft: a case series with minimum 2-year outcomes

The impact of modern airport security protocols on patients with total shoulder replacements

Review

Radiofrequency in arthroscopic shoulder surgery: a systematic review

Current Concepts

Superior capsular reconstruction for irreparable rotator cuff tear: a review of current methods

Arthroscopic Latarjet procedure: current concepts and surgical techniques

Improving visualization in shoulder arthroscopy

Case Report

Anterior interosseous nerve palsy in the early postoperative period after open capsular release for elbow stiffness: a case report

eISSN : 2288-8721

www.cisejournal.org

www.cisejournal.org

eISSN 2288-8721

# CiSE
# Clinics in Shoulder and Elbow

Volume 26 • Number 4 • December 2023

## Aims and Scope

*Clinics in Shoulder and Elbow* (Clin Shoulder Elbow, CiSE; eISSN: 2288-8721;pISSN: 2383-8337 till 2018) is the official journal of the Korean Shoulder and Elbow Society. The *Clinics in Shoulder and elbow* was first launched in 1998 and was formerly known as the Journal of the Korean Shoulder and Elbow Society until June 2010 (volume 13). It was published semiannually until 2013 and has been published quarterly on the first day of March, June, September, and December since 2014. Articles have been published in English only since 2014, and the journal has been published online only since 2019.

It aims: first, to contribute to the management and education of shoulder and elbow topics; second, to share the latest scientific information among international societies; and finally, to promote communications on shoulder/elbow problems and patient care.

Its scope includes basic and clinical research, focusing on the etiology and epidemiology, biomechanics and pathogenesis, management and surgery, complication and prognosis for the disease of shoulder and elbow. Its regional scope is mainly Asia but it welcomes submissions from researchers all over the world.

Its main publication types are original articles, case reports, invited review articles, editorials, and letters to the editor. Other types are negotiable also with editor-in-chief. All submissions are processed online. The editior-in-chief determines the fate of the submitted manuscripts after hearing from peer reviewers, who are experts in their specific fields of shoulder and elbow.

Articles published in this journal can be obtained freely from the official website of the journal. (https://www.cisejournal.org) including contents, abstracts, and full-text PDF files according to the Creative Commons license (CC-BY-NC).

*Clinics in Shoulder and Elbow* is indexed/tracked/covered by PubMed, PubMed Central (PMC), Korea Citation Index (KCI), KoreaMed, KoMCI, CrossRef, and Google Scholar.

For subscription, submission, or any other information, please contact the editorial office below.

## Open Access

This is an Open Access article distributed under the terms of the Creative Commons Attribution Non-Commercial License (http://creativecommons.org/licenses/by-nc/4.0/) which permits unrestricted non-commercial use, distribution, and reproduction in any medium, provided the original work is properly cited.

**Publisher** Korean Shoulder and Elbow Society
**Editor-In-Chief** Hyung Bin Park

**Editorial office**
Korean Shoulder and Elbow Society
#6603, 101 Daehak-ro, Jongno-gu, Seoul 03080, Korea
Tel: +82-2-3410-1854 Fax: +82-2-3410-0061 E-mail: journal@cisejournal.org

**Printing office**
M2PI
#805, 26 Sangwon 1-gil, Seongdong-gu, Seoul 04779, Korea
Tel: +82-2-6966-4930 Fax: +82-2-6966-4945 E-mail: support@m2-pi.com

Published on December 1, 2023

© 2023 by Korean Shoulder and Elbow Society.

eISSN 2288-8721

CiSE
Clinics in Shoulder and Elbow

# Editorial Board


## Editor-In-Chief
Hyung Bin Park — *Gyeongsang National University, Korea*

## Deputy Editor-in-Chief
Hyun-Seok Song — *The Catholic University of Korea, Korea*

## Editor-in-Chief Emeritus
Sung-Jae Kim — *Yonsei University, Korea*

## Board of Advisory Editors
### *Advisory Ethical Editor*
Young-Kyu Kim — *Gachon University, Korea*

### *Advirosy Research Editor*
Soo Young Kim — *Hallym University, Korea*

### *Advisory Statistical Editor*
Won Kee Lee — *Department of Biostatistics, Kyungpook National University, Korea*

## Associate Editors
Sang-Hun Ko — *University of Ulsan, Korea*
Joong-Bae Seo — *Dankook University, Korea*
Jae Chul Yoo — *Sungkyunkwan University, Korea*

## Managing Editor
Jong Pil Yoon — *Kyungpook National University, Korea*

## Editorial Board
George Athwal — *Western University, London, Ontario, Canada*
Kerem Bilsel — *Bezmialem Vakif Universitesi, Turkey*
Emilio Calvo — *Fundacion Jimenez Diaz, Spain*
Bancha Chernchujit — *Thammasat University, Thailand*
Nam-Su Cho — *Cheil Orthopedic Hospital, Korea*
Yong-Min Chun — *Yonsei University, Korea*
Philippe Collin — *American Hospital of Paris, France*
Eugene T. EK — *Monash University, Australia*
Jim Fitzsimmons — *Mayo Clinic, USA*
Michael Hantes — *University of Thessaly, Greece*
Teo Seow Hui — *University of Malaya, Malaysia*
Jung-Taek Hwang — *Hallym University, Korea*
Jong-Hun Ji — *The Catholic University of Korea, Korea*
Chunyan Jiang — *Beijing Jishuitan Hospital, China*
Chris H. Jo — *Seoul National University, Korea*
Kyu-Hak Jung — *Gachon University, Korea*
Sae-Hoon Kim — *Seoul National University, Korea*
Doo-Sup Kim — *Yonsei University, Korea*
Myung-Sun Kim — *Chonnam National University, Korea*
Jörn Kircher — *ATOS Clinic Hamburg, Germany*
Liang-Tseng Kuo — *Chang Gung Memorial Hospital, Taiwan*
Alexandre Laedermann — *La Tour hospital, Switzerland*
Bong Gun Lee — *Hanyang University, Korea*
William Levine — *Columbia University, USA*
Ofer Levy — *Reading shoulder unit, UK*
*Ben-Gurion University, Israel*
Tae Kang Lim — *Eulji University, Korea*
Ian K.Y. Lo — *University of Calgary; Calgary, Alberta, Canada*
Andri Maruli Tua Lubis — *University of Indonesia, Indonesia*
Edward McFarland — *Johns-Hopkins University, USA*
Teruhisa Mihata — *Osaka Medical College, Japan*
Tomoyuki Mochizuki — *Tokyo Medical and Dental University, Japan*
Sam-Guk Park — *Yeungnam University, Korea*
Pietro S. Randelli — *University of Milan, Italy*
W. Jaap Willems — *Lairesse Kliniek, Netherlands*
Raymond Yeak — *Universiti Putra Malaysia, Malaysia*
Jin woong Yi — *Konyang University, Korea*

## English Editors
Becker, Alza — *eWorldEditing, USA*
Houston, Julia — *eWorldEditing, USA*
Bowen, Sue — *eWorldEditing, USA*

## Statistical Editors
Kyu-Hak Jung — *Gachon University, Korea*
Du Han Kim — *Keimyung University, Korea*

## Manuscript Editor
Mi-Joo Chung — *Infolumi, Korea*

## Web site and XML producing engineer
Jeonghee Im — *M2PI, Korea*

eISSN 2288-8721

CiSE
Clinics in Shoulder and Elbow

# Contents

Volume 26 · Number 4 · December 2023

## Editorial

**341** Clavicle midshaft fractures should not be considered an easy surgery: reduction and prebending
Young-Hoon Jo, Bong Gun Lee

## Original Articles

**343** Use of custom glenoid components for reverse total shoulder arthroplasty
Punyawat Apiwatanakul, Prashant Meshram, Andrew B. Harris, Joel Bervell, Piotr Łukasiewicz, Ridge Maxson, Matthew J. Best, Edward G. McFarland

**351** Inpatient or outpatient total elbow arthroplasty: a comparison of patient populations and 30-day surgical outcomes from the American College of Surgeons National Surgical Quality Improvement Program
David Momtaz, Farhan Ahmad, Aaron Singh, Emilie Song, Dean Slocum, Abdullah Ghali, Adham Abdelfattah

**357** Concomitant open distal clavicle excision is associated with greater improvement in range of motion without increased risk of acromial stress fracture after reverse total shoulder arthroplasty: a retrospective cohort study
Ajay C. Kanakamedala, Dhruv S. Shankar, Neil Gambhir, Matthew R. Boylan, Michael Boin, Matthew G. Alben, Mandeep S. Virk, Young W. Kwon

**366** Classification system for partial distal biceps tendon tears: a descriptive 3-Tesla magnetic resonance imaging study of tear morphology
Alex B Boyle, Simon BM MacLean

**373** Effect of cigarette smoking on the maintenance of reduction after treatment of acute acromioclavicular joint dislocation with hook plate fixation
Jee-Hoon Choi, Yong-Min Chun, Tae-Hwan Yoon

**380** Anatomic total shoulder arthroplasty with a nonspherical humeral head and inlay glenoid: 90-day complication profile in the inpatient versus outpatient setting
Andrew D. Posner, Michael C. Kuna, Jeremy D. Carroll, Eric M. Perloff, Matthew J. Anderson, Ian D. Hutchinson, Joseph P. Zimmerman

**390** Glenohumeral versus subacromial steroid injections for impingement syndrome with mild stiffness: a randomized controlled trial
Yong-Tae Kim, Tae-Yeong Kim, Jun-Beom Lee, Jung-Taek Hwang

**397** Plate prebending using a three-dimensional–printed model affords effective anatomical reduction in clavicular shaft fractures
Hyungsuk Kim, Younsung Jung, Hyun Seok Song

**406** Radiologic and clinical outcomes of an arthroscopic bridging graft for irreparable rotator cuff tears with a modified Mason-Allen stitch using a plantaris tendon autograft: a case series with minimum 2-year outcomes
Hyun-Gyu Seok, Sam-Guk Park

**416** The impact of modern airport security protocols on patients with total shoulder replacements
Michael D. Scheidt, Neal Sethi, Matthew Ballard, Michael Wesolowski, Dane Salazar, Nickolas Garbis

eISSN 2288-8721

CiSE
Clinics in Shoulder and Elbow

# Contents

Volume 26 · Number 4 · December 2023

## Review

423 Radiofrequency in arthroscopic shoulder surgery: a systematic review
Neeraj Vij, Joseph N. Liu, Nirav Amin

## Current Concepts

438 Superior capsular reconstruction for irreparable rotator cuff tear: a review of current methods
Seok Won Chung, Dong-Hyun Kim, Hyun Joo Lee, Won Ki Hong, Seung Ho Chung, Jong Pil Yoon

445 Arthroscopic Latarjet procedure: current concepts and surgical techniques
Sang-Jin Shin, Jae Hyung Kim, Jonghyun Ahn

455 Improving visualization in shoulder arthroscopy
Emily R. McDermott, David J. Tennent, Daniel J. Song

## Case Report

462 Anterior interosseous nerve palsy in the early postoperative period after open capsular release for elbow stiffness: a case report
Christopher A. Colasanti, Michael Boin, Jacques Hacquebord, Mandeep S. Virk

Editorial

Clin Shoulder Elbow 2023;26(4):341-342
https://doi.org/10.5397/cise.2023.00976

CiSE
Clinics in Shoulder and Elbow

eISSN 2288-8721

# Clavicle midshaft fractures should not be considered an easy surgery: reduction and prebending

**Young-Hoon Jo[1], Bong Gun Lee[2]**

[1]*Department of Orthopaedic Surgery, Hanyang University Guri Hospital, Guri, Korea*
[2]*Department of Orthopaedic Surgery, Hanyang University Seoul Hospital, Seoul, Korea*

Clavicle midshaft fractures are common, often requiring surgical fixation when displaced [1]. While this operation seems straightforward due to the thin soft tissue coverage and easy surgical approach, clavicle midshaft fracture surgery presents several challenges [2].

First, fracture reduction is typically difficult as the lateral fragment is displaced downward by the weight of the arm, and the medial fragment is displaced upward due to the action of the sternocleidomastoid muscle. These force vectors must be carefully considered during reduction. Second, soft tissue dissection must be minimized to promote fracture healing, limiting the field of view to one side of the clavicle and assessment of the angulation of the fracture. Last, the shape of the metal plate does not always match the shape of the clavicle as the curve and the dimension of the clavicle vary by patient; in addition, the location of the fracture is variable. Therefore, optimal placement of the plate can be challenging [3-5].

To address these issues, prebending the plate before surgery can be beneficial. Kim et al. [6] reported prebending the plate using a three-dimensional (3D) printed model based on a mirror image of the contralateral uninjured clavicle. That study appears to have been conducted with a deep understanding of the unique characteristics of clavicle midshaft fractures. I agree with the results of the study, suggesting that a preoperatively prebent plate based on a 3D-printed model that matches the clavicle shape can be beneficial for fracture reduction in terms of operative time and clinical outcome.

In a study conducted by Leroux et al. [7], secondary surgery was performed in 24.6% of operatively repaired clavicles. The majority of these reoperations were for implant removal, with a higher removal rate in women compared to men. The study hypothesized that skin irritation, caused by undergarments crossing the clavicle plate and the overlying skin incision, could be a contributing factor. The higher rate of implant removal in women may support this hypothesis. The prebending method proposed by the authors may reduce skin irritation from the plates and patient discomfort, potentially reducing the need for implant removal surgeries [8].

The image reported as an axial image of the clavicle in the study is not a true axial image. A "true axial image" is a 90° vertical image compared to the anterior view. In the study of interest, the axial image is actually a cephalad image [9,10]. The study's strength is that it provides radiologic parameters (clavicle length and clavicle angle) using bilateral clavicles to evaluate the appropriateness of clavicle midshaft fracture reduction. Additionally, it offers clinical evidence of the cost-effective utility of preoperative prebending using a 3D-printed model [6]. Considering these strengths, I believe the results of the study can greatly benefit surgeons performing clavicle midshaft fracture surgery.

Received: November 6, 2023 Revised: November 11, 2023 Accepted: November 13, 2023
Correspondence to: Bong Gun Lee
Department of Orthopaedic Surgery, Hanyang University Seoul Hospital, 222-1 Wangsimni-ro, Seongdong-gu, Seoul 04763, Korea
Tel: +82-2-2290-8493, E-mail: orthdr@naver.com, ORCID: https://orcid.org/0000-0002-4003-5529

Copyright© 2023 Korean Shoulder and Elbow Society.
This is an Open Access article distributed under the terms of the Creative Commons Attribution Non-Commercial License (http://creativecommons.org/licenses/by-nc/4.0/) which permits unrestricted non-commercial use, distribution, and reproduction in any medium, provided the original work is properly cited.

# NOTES


## ORCID

Young-Hoon Jo https://orcid.org/0000-0002-4299-2496
Bong Gun Lee https://orcid.org/0000-0002-4003-5529


## Author contributions

Conceptualization: YHJ. Writing – original draft: BGL. Writing – review & editing: YHJ.

## Conflict of interest

Bong Gun Lee is an editorial board member of the journal but was not involved in the peer reviewer selection, evaluation, or decision process of this article. No other potential conflict of interest relevant to this article was reported.


## Funding

None.


## Data availability

None.


## Acknowledgments

None.


# REFERENCES


1. Ahmed AF, Salameh M, AlKhatib N, Elmhiregh A, Ahmed GO. Open reduction and internal fixation versus nonsurgical treatment in displaced midshaft clavicle fractures: a meta-analysis. J Orthop Trauma 2018;32:e276–83.
2. van der Meijden OA, Gaskill TR, Millett PJ. Treatment of clavicle fractures: current concepts review. J Shoulder Elbow Surg 2012;21:423–9.
3. Daruwalla ZJ, Courtis P, Fitzpatrick C, Fitzpatrick D, Mullett H. Anatomic variation of the clavicle: a novel three-dimensional study. Clin Anat 2010;23:199–209.
4. Bernat A, Huysmans T, Van Glabbeek F, Sijbers J, Gielen J, Van Tongel A. The anatomy of the clavicle: a three-dimensional cadaveric study. Clin Anat 2014;27:712–23.
5. King PR, Scheepers S, Ikram A. Anatomy of the clavicle and its medullary canal: a computed tomography study. Eur J Orthop Surg Traumatol 2014;24:37–42.
6. Kim H, Jung Y, Song HS. Plate prebending using a three-dimensional–printed model affords effective anatomical reduction in clavicular shaft fractures. Clin Shoulder Elb 2023;26:397-405.
7. Leroux T, Wasserstein D, Henry P, et al. Rate of and risk factors for reoperations after open reduction and internal fixation of midshaft clavicle fractures: a population-based study in Ontario, Canada. J Bone Joint Surg Am 2014;96:1119–25.
8. Wolf S, Chitnis AS, Manoranjith A, et al. Surgical treatment, complications, reoperations, and healthcare costs among patients with clavicle fracture in England. BMC Musculoskelet Disord 2022;23:135.
9. Sharr JR, Mohammed KD. Optimizing the radiographic technique in clavicular fractures. J Shoulder Elbow Surg 2003;12:170–2.
10. Kim HN, Liu XN, Noh KC. Use of a real-size 3D-printed model as a preoperative and intraoperative tool for minimally invasive plating of comminuted midshaft clavicle fractures. J Orthop Surg Res 2015;10:91.



https://doi.org/10.5397/cise.2023.00976

Original Article

Clin Shoulder Elbow 2023;26(4):343-350
https://doi.org/10.5397/cise.2023.00563

CiSE
Clinics in Shoulder and Elbow

eISSN 2288-8721

# Use of custom glenoid components for reverse total shoulder arthroplasty

**Punyawat Apiwatanakul, Prashant Meshram, Andrew B. Harris, Joel Bervell, Piotr Łukasiewicz, Ridge Maxson, Matthew J. Best, Edward G. McFarland**

*Division of Shoulder and Elbow Surgery, Department of Orthopaedic Surgery, The Johns Hopkins University, Baltimore, MD, USA*

**Background:** Our purpose was to evaluate a custom reverse total shoulder arthroplasty glenoid baseplate for severe glenoid deficiency, emphasizing the challenges with this approach, including short-term clinical and radiographic outcomes and complications.
**Methods:** This was a single-institution, retrospective series of 29 patients between January 2017 and December 2022 for whom a custom glenoid component was created for extensive glenoid bone loss. Patients were evaluated preoperatively and at intervals for up to 5 years. All received preoperative physical examinations, plain radiographs, and computed tomography (CT). Intra- and postoperative complications are reported.
**Results:** Of 29 patients, delays resulted in only undergoing surgery, and in three of those, the implant did not match the glenoid. For those three, the time from CT scan to implantation averaged 7.6 months (range, 6.1–10.7 months), compared with 5.5 months (range, 2–8.6 months) for those whose implants fit. In patients with at least 2-year follow-up (n=9), no failures occurred. Significant improvements were observed in all patient-reported outcome measures in those nine patients (American Shoulder and Elbow Score, P<0.01; Simple Shoulder Test, P=0.02; Single Assessment Numeric Evaluation, P<0.01; Western Ontario Osteoarthritis of the Shoulder Index, P<0.01). Range of motion improved for forward flexion and abduction (P=0.03 for both) and internal rotation up the back (P=0.02). Pain and satisfaction also improved (P<0.01 for both).
**Conclusions:** Prolonged time (>6 months) from CT scan to device implantation resulted in bone loss that rendered the implants unusable. Satisfactory short-term radiographic and clinical follow-up can be achieved with a well-fitting device.
**Level of evidence:** III.

**Keywords:** Arthroplasty; Treatment outcomes; Glenoid bone loss; Reverse; Shoulder

## INTRODUCTION

Glenoid bone loss, primary or due to failed arthroplasty, is a problem encountered during reverse total shoulder arthroplasty (RTSA) procedures [1,2]. Management of glenoid bone loss in these situations is challenging, particularly when eccentric glenoid wear is present. Bone grafting for such defects has been reported for primary shoulder arthroplasty, as well as after bone loss from infection, glenoid component failure in anatomic shoulder arthroplasty, and revision of a failed RTSA [1-4]. However, bone grafting for large glenoid defects has been reported to have a high failure rate when used for those indications because the bone stock might not be adequate for conventional implants to gain adequate purchase [4].

Received: June 28, 2023 Revised: August 20, 2023 Accepted: September 2, 2023
Correspondence to: Edward G. McFarland
Division of Shoulder and Elbow Surgery, Department of Orthopaedic Surgery, The Johns Hopkins University, 2360 West Joppa Rd, Suite 306, 10753 Falls Rd, Lutherville, MD 21093, USA
Tel: +1-410-583-2851 E-mail: emcfarl1@jhmi.edu, ORCID: https://orcid.org/0000-0002-1193-4672

Copyright© 2023 Korean Shoulder and Elbow Society.
This is an Open Access article distributed under the terms of the Creative Commons Attribution Non-Commercial License (http://creativecommons.org/licenses/by-nc/4.0/) which permits unrestricted non-commercial use, distribution, and reproduction in any medium, provided the original work is properly cited.

Recently, the use of custom glenoid components has been shown to provide short-term success in treating large glenoid bone defects [5-8]. These components are manufactured to fill a bone defect with a metallic glenoid component that includes a baseplate that mirrors the bone surface and provides bone fixation with multiple screws. Several previous studies have reported short-term success with custom glenoid components in RTSA, but those studies have typically involved multiple surgeons, and only one of them reported any intraoperative or postoperative complications (Table 1) [5-9].

Our goals in this study were to report the preoperative assessment of patients undergoing RTSA with a custom glenoid component, describe intraoperative complications associated with the use of these devices, and report the short-term clinical and radiographic results and complications from using custom glenoid components.

## METHODS

This study was approved by the Institutional Review Board of Johns Hopkins Medicine (No. 00279172). The requirement for informed consent was waived.

We used our institutional shoulder arthroplasty registry to identify patients who underwent shoulder replacement with a custom glenoid prosthesis between January 2017 and September 2022. The inclusion criterion was loss of glenoid bone to the extent that computer modeling predicted inadequate bone coverage of the glenoid baseplate when using conventional or augmented baseplates—this process is performed for all preoperative patients undergoing RTSA. Inadequate bone was defined as coverage of less than 50% of the baseplate on computer modeling [9].

During this period, 1303 RTSAs were performed by the senior author (EGM); of them, 29 (2.2%) were eligible for custom glenoid vault components (Fig. 1). The glenoid vault deformities were classified using the criteria of Walch [10,11], Antuna [12], Hamada [13], Sirveaux [14], and Frankle [15]. Of the 29 eligible patients, COVID pandemic-related delays made four ineligible for surgery for medical reasons, and one of those four patients died. That left 25 patients who underwent reconstruction using a custom glenoid vault designed for their individual glenoid morphologies (Comprehensive Vault Reconstruction System, Zimmer Biomet). At the time of surgery, three implants did not fit the glenoid, and as a last resort, all of those patients received standard manufactured baseplates and available RTSA components from a different implant system (ReUnion RSA; Stryker) despite less-than-optimal glenoid coverage by the baseplate. Median follow-up was 18 months (range, 1–60 months) in the remaining 22 patients, nine of whom had >2 years of follow-up (range, 24–60 months) (Fig. 2).

All patients underwent a preoperative assessment (plain radiographs, computed tomography (CT) scans, and a thorough physical examination) within 1 month of surgery. All patients deemed to require a custom glenoid component received thin-cut CT scans in line with a protocol that enables three-dimensional (3D) modeling (Fig. 3). All patients underwent computer modeling of the glenoid by engineers from the company to determine the trajectory and length for each screw that provided the best orientation to reach the most substantial bone [8]. This analysis was

**Table 1.** Previous publications about the use of custom glenoid implants

| Study | System used (manufacturer) | Setting | N | No. (%) | | Follw-up (mo), mean (range) | No. (%) and type of complications |
|---|---|---|---|---|---|---|---|
| | | | | Primary | Revision | | |
| Dines et al. (2017) [7] | Glenoid vault reconstruction system (VRS; Zimmer Biomet) | 1 Surgeon | 2 | 0 | 2 (100) | 33 (18–48) | 0 |
| Debeer et al. (2019) [6] | Glenius Glenoid Reconstruction System (Materialise NV) | 5 Centers | 10 | 4 (40) | 6 (60) | 31 (15–44) | 1 (10%): Instability |
| Rangarajan et al. (2020) [8] | Glenoid vault reconstruction system (VRS; Zimmer Biomet) | 1 Surgeon | 19 | 9 (47) | 10 (52) | 18 (12–27) | 4 (21%): 1 Each of nondisplaced GT fracture, intraoperative cortical perforation, recurrent instability and hematoma, early periprosthetic infection |
| Bodendorfer et al. (2021) [5] | Glenoid vault reconstruction system (VRS; Zimmer Biomet) | 4 Surgeons in 3 centers | 12 | 7 (58) | 5 (42) | 30 (24–52) | 0 |
| Porcellini et al. (2021) [9] | ProMade (LimaCorporate) | 2 Centers | 6 | 2 (33) | 4 (67) | 32 (25–38) | 1 (16%): Partial dislocation |

VRS: Comprehensive Vault Reconstruction System, GT: greater tuberosity.


https://doi.org/10.5397/cise.2023.00563

**Fig. 1.** Example patient who previously sustained an anatomic total shoulder arthroplasty and underwent antibiotic spacer placement for prosthetic joint infection. Preoperative radiographs (A-C) show the antibiotic spacer and severe glenoid bone loss. Computed tomography scan images (D-F) highlight the severity of bone loss due to osteolysis and previous glenoid screws.

performed for the central non-locking screw and four peripheral locking screws.

Visual analog scale (VAS) scores for pain and several patient-reported outcome measures (PROMs) were collected from each patient: the shoulder score from the American Shoulder and Elbow Score (ASES) [16], the Simple Shoulder Test (SST) [17], the Single Assessment Numeric Evaluation (SANE) [18], and the Western Ontario Osteoarthritis of the Shoulder Index (WOOS) [19]. The minimal clinically important differences (MCIDs) for the PROMs and ranges of motion (ROMs) [20] were used to determine clinically meaningful improvement after surgery. Preoperative clinical outcome scores were gathered within 1 month preoperatively and at 3 months, 6 months, 1 year, and then annually postoperatively.

The preoperative and postoperative physical examinations were performed by one of two observers (the senior author [EGM] or senior author's physician assistant, who had 12 years of experience) to minimize inter-observer variability [21]. The examination included ROM; strength testing in abduction; external rotation with the arm at the side; and lag signs, particularly the external rotation lag sign [22], the dropping sign [23,24], and the lift-off lag sign [25]. Plain radiographs were taken from an anterior-posterior view in internal rotation, a true anterior-posterior view (Grashey view) [26], and an axillary view. The mean interval from the CT scan to the day of surgery for patients who successfully received a custom glenoid implant was 5.7 months (range, 1–10.7 months). For patients who had a custom glenoid made that did not fit intraoperatively, the mean duration was 7.8 months (range, 5.9–10.7 months). Three-dimensional imaging and physical models were made available during the preoperative and intraoperative periods to assist in planning implant orientation, screw trajectory, and optimal fixation. Postoperatively, the patients underwent only plain radiography at each subsequent office visit. All radiographs were read by independent observers for implant movement, loosening of the baseplate or screws, and scapular notching.

## Operative Technique

After an administration of antibiotics and the induction of general anesthesia, all patients were placed in the beach-chair posi-




**Fig. 2.** Flow diagram for the 29 cases of custom glenoid replacement for significant glenoid bone loss.

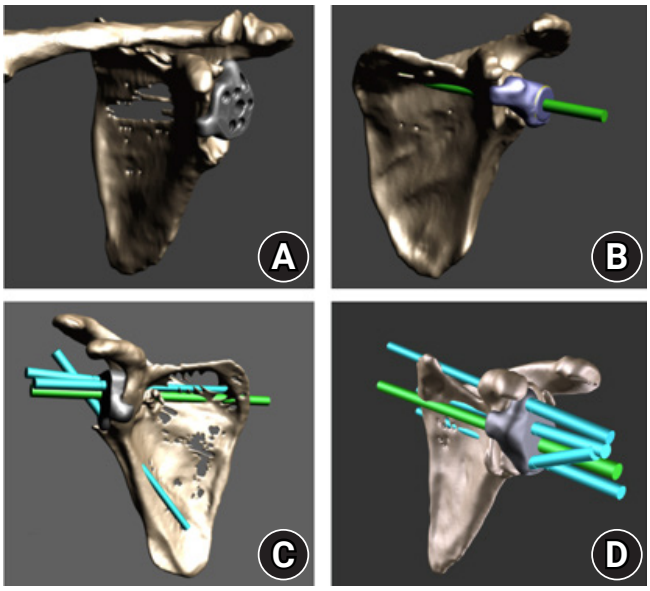


**Fig. 3.** (A-D) Three-dimensional modeling demonstrating the planned position for the custom glenoid component and the central screw (green) and peripheral locking screw (blue) trajectories.

tion. A deltopectoral approach was used to develop an interval down to the clavipectoral fascia. After arthrotomy was performed, the proximal humerus was exposed, and a freehand transverse cut was made with an oscillating saw in approximately 30° of retroversion and 135° of inclination after marking the planned cut with a cutting guide. The glenoid was then carefully and thoroughly exposed such that the entire glenoid rim and vault could be completely visualized using a posterior-inferior Hohman retractor, posterior glenoid access retractor, and superior Hohman retractor. The glenoid defect was then compared to the scapular model, and the glenoid component was placed in the glenoid using the handle. If the implant could not be fitted exactly to the surface of the glenoid, it was deemed to toggle, which was interpreted to mean that the interface between the component and the glenoid surface was inexact due to either excess bone or soft tissue interposition. A 6.5-mm central screw was then placed in the central hole and inserted. In several instances, the screw did not provide compression. In such cases, the screw was deemed a spinner, meaning that it provided no compression and did not have firm fixation. Peripheral locking 4.75-mm screws were then placed according to the depth-guide-measured depth.

In the three patients whose implants did not fit the glenoid at all, the glenoid was reamed to a flat surface, and a different implant system (Stryker ReUnion Stryker) with a central screw and two peripheral screws was used as a last resort. In all three of those cases, less than 50% of the glenoid bone remained, but a hemiarthroplasty was not performed out of concern about subsequent instability of the prosthesis.

### Outcomes and Data Analysis

The demographic and clinical findings are summarized with descriptive statistics. Preoperative clinical outcomes (SST, ASES, WOOS, VAS), ROM values, and patient satisfaction were compared with the patient's most recent postoperative visit using the Wilcoxson signed-rank test. Radiographs were evaluated by two fellowship-trained shoulder surgeons for any signs of loosening, osteolysis, or subsidence. To determine differences in treatment outcomes, a subgroup analysis between primary and revision cases was conducted using the Mann-Whitney U-test.

## RESULTS

The mean time from the index CT scan to the day of surgery (regardless of whether a custom glenoid was ultimately placed) was 5.7 months (range, 1–10.7 months). For patients who had a custom glenoid made that did not fit intraoperatively, the mean duration was 7.8 months, whereas those who received a custom glenoid had a mean duration of 4.8 months. The mean follow-up was 2.8 ± 0.5 years.

Intraoperative fracture occurred in seven cases (31.8%), in-


https://doi.org/10.5397/cise.2023.00563

cluding one of the scapular spine (4.5%), one of the medial calcar of the proximal humerus (4.5%), five of the greater tuberosity (22.7%), and one of the greater tuberosity with a simultaneous fracture of the proximal humeral shaft (4.5%). The central screw was deemed a spinner in eight cases (36.4%), and an unexpected positive culture (*Cutibacterium acnes*) was found in six (27.2%). Two other complications, implant toggling and completely missed screw trajectory, occurred in four (18.1%) and two cases (9.1%), respectively. At final follow-up, none of the patients in the study had suffered baseplate failure or dislocation necessitating reoperation.

Of the 22 patients who had a custom glenoid component implanted, the baseplate toggled at the time of surgery in four (18%). In two patients (9%), one peripheral screw did not contact bone, and one screw contacted the cortical bone and was therefore left in place. In a third patient, the screw had no contact with bone and as a result was not used. The nine patients (5 primary, 4 revision) who had a minimum 2 years of follow-up were five females and four males (mean age, 74.3 ± 5.3 years; body mass index, 28.2 ± 5.5 kg/m$^2$). The etiologies in the five primary cases were degenerative arthritis in one, cuff tear arthropathy in two, and posttraumatic arthritis in two. The four patients who underwent revision had each had at least two prior arthroplasty surgeries (Table 2).

Table 3 compares the ROMs, clinical outcomes, pain, and satisfaction before and after the RTSA with a custom implant. Significant improvements were observed in all PROMs in the nine patients with a minimum of 2 years of follow-up (ASES, $P < 0.01$; SST, $P = 0.02$; SANE, $P < 0.01$; WOOS, $P < 0.01$). ROM improved significantly for forward flexion and abduction ($P = 0.03$ for both) and internal rotation up the back ($P = 0.02$). Pain and satisfaction were also significantly improved ($P < 0.01$ for both) (Table 3).

## DISCUSSION

Our results show that a custom glenoid implant is a viable option for severe glenoid bone loss in both primary and revision RTSA. However, our results also demonstrate that these implants should be implanted within a few months of construction, that imperfect fit of the implant can occur, and that complications typical of cases with complex glenoid bone loss can occur. Nonetheless, custom glenoid components used for RTSA can, at early follow-up, provide statistically and clinically significant Preoperative to postoperative improvements in pain relief, PROMs, ROM, and patient satisfaction, with patients experiencing improvement in pain and functional outcomes that met the criteria for MCID [20]. This study also highlights special considerations in Preoperative planning, intraoperative positioning of the implant, and postoperative follow-up for these patients.

Keeping the time from the index CT scan used for modeling and manufacturing the custom glenoid prosthesis to the time of implantation in the patient to a minimum is important. Indeed,

**Table 2.** Characteristics of nine patients with minimum 2-year follow-up after RTSA

| Patient No. | Age (yr) | Sex | Follow-up (mo) | Prior arthroplasty | Presence of implants | Indication for surgery | Defect classification |
|---|---|---|---|---|---|---|---|
| 1 | 78.0 | F | 60 | 2 | Hemiarthroplasty | Failed RTSA | Antuna, severe combined central and posterior |
| 2 | 68.6 | M | 51 | 2 | Hemiarthroplasty | Failed TSA | Antuna, severe combined central and anterior |
| 3 | 65.2 | F | 48 | 0 | None | Dislocation arthropathy | Walch, A2 |
| 4 | 80.3 | F | 24 | 0 | None | Chronic anterior fracture dislocation | Walch, D |
| 5 | 80.1 | M | 42 | 0 | None | Cuff tear arthropathy | Favard E3; Walch A2; Hamada IIB; Frankle superior erosion |
| 6 | 74.5 | F | 40 | 0 | None | Degenerative arthritis | Walch, C |
| 7 | 71.4 | M | 30 | 3 | Hemiarthroplasty | Failed TSA | Antuna, severe combined anterior, central, and posterior |
| 8 | 72.3 | M | 31 | 4 | Antibiotic cement spacer | Infected RTSA | Antuna, severe combined anterior, central, and posterior |
| 9 | 78.3 | F | 27 | 0 | None | Cuff tear arthropathy | Favard E1; Walch D; Hamada IIB; Frankle anterior erosion |

RTSA: reverse total shoulder arthroplasty, TSA: anatomic total shoulder arthroplasty.

**Table 3.** Ranges of motion, clinical outcomes, and pain before and after RTSA with custom implant in nine patients with minimum 2 years of follow-up

| Outcome | Preoperative | Postoperative | P-value |
|---|---|---|---|
| Range of motion (°) | | | |
| Abduction | 73.9 ± 33.1 | 95.6 ± 39.7 | 0.03† |
| Flexion | 73.9 ± 33.1 | 100.0 ± 40.3 | 0.03† |
| External rotation | 46.7 ± 16.6 | 60.0 ± 20.2 | 0.05 |
| External rotation (arm at side) | 10.6 ± 23.8 | 20.0 ± 21.7 | 0.24 |
| Internal rotation | 17 ± 15.8 | 6.1 ± 31.6 | 0.39 |
| Internal rotation (hand behind back)* | Buttock | L4/L5 | 0.02† |
| Functional outcome | | | |
| ASES score | 26.6 ± 22.6 | 68.1 ± 26.6 | < 0.01† |
| SST | 4.0 ± 3.0 | 8.0 ± 2.8 | 0.02† |
| SANE | 34.7 ± 22.0 | 69.6 ± 27.3 | < 0.01† |
| WOOS | 32.7 ± 22.2 | 64.1 ± 27.3 | < 0.01† |
| Pain (visual analog scale) | 8.2 ± 1.3 | 1.5 ± 2.3 | < 0.01† |
| Report satisfaction | 1.6 (1–2) | 3.7 (2–5) | < 0.01† |

Values are presented as mean ± standard deviation or median (interquartile range).
RTSA: reverse total shoulder arthroplasty, ASES: American Shoulder and Elbow Surgeons, SST: Simple Shoulder Test, SANE: Single Assessment Numeric Evaluation, WOOS: Western Ontario Osteoarthritis of the Shoulder Index.
*Internal rotation rated ordinally as follows: 1, T10/T11; 2, T12/L1; 3, L2/L3; 4, L4/L5; 5, sacrum; 6, buttock; 7, hip/lateral thigh; †Significant value ($P < 0.05$).

the manufacturer suggests that this time be as short as possible because the glenoid bone topography can change if the interval from the CT scan to insertion is too long [27]. In this study, the mean interval in cases with severe mismatch was 7.8 months (range 5.9–10.7 months). Rangarajan et al. [8] noted that manufacture of these devices typically takes a minimum of 8 weeks, and subtle changes in glenoid bone morphology can occur even during that short period. When the custom glenoid component interfaced well with native bone, we found the fit to be nearly perfect, which can rarely be obtained with off-the shelf glenoid components in patients with severe glenoid bone loss. We are not aware of published literature that compares the manufacturing time for custom glenoid implants between implant companies; however, that could be an important topic for future studies.

Our results also highlight the importance of telling patients that the implant might not fit and having a surgical backup plan should the implant not fit at all. In our study, eccentric reaming of the glenoid was performed to the best of our ability in three cases with >50% glenoid bone loss when the custom glenoid implant did not fit adequately. Although none of our patients required revision surgery within the current follow-up period, longer follow-up is needed to determine whether the three patients whose custom implants did not fit have durable long-term results. Another option in these circumstances would be to place a hemiarthroplasty with no glenoid component, but the inability of the custom implant to fit reinforces the importance of having a backup system available for all the possible options in this situation.

This study is the first to present RTSA cases using a custom baseplate with a minimum 2 years of follow-up. Dines et al. [7] reported two patients with failed previous shoulder arthroplasty who were treated with patient-specific implants using a vault reconstruction system. At 18 months' follow-up, those patients had increased ROM and satisfaction with the surgery. In their multicenter report of experience using a custom glenoid for treatment of severe glenoid deficiency, Debeer et al. [6] found that patients reported high satisfaction, low pain, and good functional outcomes postoperatively. Bodendorfer et al. [5] reported short-term outcomes of custom glenoid placement in 12 shoulders of 11 patients. At a mean follow-up of 30 months, the patients had no complications or any signs of implant loosening. Rangarajan et al. [8] reported on 18 patients with a minimum 1 year of follow-up (mean, 18.2 months). They also reported no failures, with no signs of notching, humeral or baseplate loosening, or implant failure.

The complications seen in this study are comparable to those reported in the literature for custom glenoid components and revision shoulder arthroplasty, with the relatively high rate of complications reflecting the challenging nature of complex revision surgeries [8]. Complications such as greater tuberosity fracture in both primary and revision cases were recently reported by Wixted et al. [28] and Dolci et al. [29]. Our complications when using a custom glenoid component are similar to those reported by Rangarajan et al. [8], who reported four complications (21%): one greater tuberosity fracture; one humeral perforation requir-


https://doi.org/10.5397/cise.2023.00563

ing a fibular strut graft; one hematoma requiring removal and replacement of the humeral component; and one infection, with removal of the implants and placement of an antibiotic spacer.

Several limitations need to be considered when interpreting the results of this study or considering performing this procedure. First, although the follow-up is the longest reported to date for this type of glenoid implant, the number of patients with at least 2 years of follow-up is small, and the results here might represent a type II error. Second, the mass of metal in these implants and irregular surfaces make it difficult to detect the degree of contact between the implant and the glenoid surface. Our experience with toggling of the implant at the time of surgery, with two patients in whom one of the four peripheral screws missed the glenoid bone entirely and a lack of compression of the central screw in eight patients, suggests that the fit of the implants can be less than ideal.

## CONCLUSIONS

The short-term outcomes indicate that RTSA with a custom glenoid baseplate gave patients excellent pain relief and functional outcomes after a minimum of 2 years of follow-up. Although custom glenoid components show promise for the treatment of substantial glenoid bone loss, they are not without challenges. This study showed that a prolonged time (more than 6 months) between CT scanning and device implantation resulted in bone loss that rendered the implants unusable. However, when the device does fit the glenoid, satisfactory short-term results can be achieved.

## NOTES

### ORCID


| | |
|---|---|
| Punyawat Apiwatanakul | https://orcid.org/0000-0002-9545-144X |
| Prashant Meshram | https://orcid.org/0000-0003-4537-5052 |
| Andrew B. Harris | https://orcid.org/0000-0002-8158-4364 |
| Joel Bervell | https://orcid.org/0000-0002-5828-2640 |
| Piotr Łukasiewicz | https://orcid.org/0000-0003-3826-7221 |
| Ridge Maxson | https://orcid.org/0000-0001-8224-2836 |
| Matthew J. Best | https://orcid.org/0000-0002-4401-2834 |
| Edward G. McFarland | https://orcid.org/0000-0002-1193-4672 |


### Author contributions

Conceptualization: PA, PM, ABH, JB, PL, RM, MJB. Data curation: PM, ABH, JB, PL, RM, MJB. Formal analysis: PA, ABH, JB, PL, EGM. Funding acquisition: EGM. Investigation: PA, MJB, EGM. Methodology: PA, PM, ABH, JB, PL, RM, MJB. Project administration: RM. Resources: PM, ABH, JB, PL. Supervision: PM, ABH, PL, MJB. Validation: PM, PL, MJB, EGM. Visualization: EGM. Writing – original draft: PA, PM, ABH, JB, PL, RM, MJB, EGM. Writing – review & editing: PA, PM, ABH, JB, PL, RM, MJB, EGM.

### Conflict of interest

EGM is a consultant for Stryker Corporation, outside of this work. All authors declare that they, their immediate family, and any research foundation with which they are affiliated received no financial payments or other benefits from any commercial entity related to the subject of this article.


### Funding

The authors disclose receipt of the following financial or material support for the research, authorship, and/or publication of this article: The Donna and William Marriott Research Fund. This funding source had no role in the design, execution, analyses, interpretation of the data, or decision to submit results.


### Data availability

Contact the corresponding author for data availability.


### Acknowledgments

For editorial assistance, we thank Denise Di Salvo, MS, and Rachel Walden, MS, in the Editorial Services group of the Johns Hopkins Department of Orthopedic Surgery. We also thank the senior author's physician assistant, Marcy Beard, PA-C, Johns Hopkins Medicine, for her involvement in patient examinations.


## REFERENCES


1. Chalmers PN, Boileau P, Romeo AA, Tashjian RZ. Revision reverse shoulder arthroplasty. J Am Acad Orthop Surg 2019;27:426–36.
2. Malhas A, Rashid A, Copas D, Bale S, Trail I. Glenoid bone loss in primary and revision shoulder arthroplasty. Shoulder Elbow 2016;8:229–40.
3. Garrigues GE, Zmistowski B, Cooper AM, Green A; ICM Shoulder Group. Proceedings from the 2018 International Consensus Meeting on Orthopedic Infections: the definition of periprosthetic shoulder infection. J Shoulder Elbow Surg 2019;28(6S):S8–12.
4. Malahias MA, Chytas D, Kostretzis L, et al. Bone grafting in primary and revision reverse total shoulder arthroplasty for the management of glenoid bone loss: a systematic review. J Orthop 2019;20:78–86.

5. Bodendorfer BM, Loughran GJ, Looney AM, et al. Short-term outcomes of reverse shoulder arthroplasty using a custom baseplate for severe glenoid deficiency. J Shoulder Elbow Surg 2021;30:1060–7.
6. Debeer P, Berghs B, Pouliart N, Van den Bogaert G, Verhaegen F, Nijs S. Treatment of severe glenoid deficiencies in reverse shoulder arthroplasty: the Glenius Glenoid Reconstruction System experience. J Shoulder Elbow Surg 2019;28:1601–8.
7. Dines DM, Gulotta L, Craig EV, Dines JS. Novel solution for massive glenoid defects in shoulder arthroplasty: a patient-specific glenoid vault reconstruction system. Am J Orthop (Belle Mead NJ) 2017;46:104–8.
8. Rangarajan R, Blout CK, Patel VV, Bastian SA, Lee BK, Itamura JM. Early results of reverse total shoulder arthroplasty using a patient-matched glenoid implant for severe glenoid bone deficiency. J Shoulder Elbow Surg 2020;29(7S):S139–48.
9. Porcellini G, Micheloni GM, Tarallo L, Paladini P, Merolla G, Catani F. Custom-made reverse shoulder arthroplasty for severe glenoid bone loss: review of the literature and our preliminary results. J Orthop Traumatol 2021;22:2.
10. Bercik MJ, Kruse K 2nd, Yalizis M, Gauci MO, Chaoui J, Walch G. A modification to the Walch classification of the glenoid in primary glenohumeral osteoarthritis using three-dimensional imaging. J Shoulder Elbow Surg 2016;25:1601–6.
11. Walch G, Badet R, Boulahia A, Khoury A. Morphologic study of the glenoid in primary glenohumeral osteoarthritis. J Arthroplasty 1999;14:756–60.
12. Antuna SA, Sperling JW, Cofield RH, Rowland CM. Glenoid revision surgery after total shoulder arthroplasty. J Shoulder Elbow Surg 2001;10:217–24.
13. Hamada K, Fukuda H, Mikasa M, Kobayashi Y. Roentgenographic findings in massive rotator cuff tears: a long-term observation. Clin Orthop Relat Res 1990;(254):92–6.
14. Sirveaux F, Favard L, Oudet D, Huquet D, Walch G, Molé D. Grammont inverted total shoulder arthroplasty in the treatment of glenohumeral osteoarthritis with massive rupture of the cuff: results of a multicentre study of 80 shoulders. J Bone Joint Surg Br 2004;86:388–95.
15. Frankle MA, Teramoto A, Luo ZP, Levy JC, Pupello D. Glenoid morphology in reverse shoulder arthroplasty: classification and surgical implications. J Shoulder Elbow Surg 2009;18:874–85.
16. Richards RR, An KN, Bigliani LU, et al. A standardized method for the assessment of shoulder function. J Shoulder Elbow Surg 1994;3:347–52.
17. Lippitt S, Harryman D, Matsen FA. A practical tool for evaluating function: the simple shoulder test. In: Matsen FA, Fu FH, Hawkins R, eds. The shoulder: a balance of mobility and stability. American Academy of Orthopaedic Surgeons; 1993. p. 501-18.
18. Gowd AK, Charles MD, Liu JN, et al. Single Assessment Numeric Evaluation (SANE) is a reliable metric to measure clinically significant improvements following shoulder arthroplasty. J Shoulder Elbow Surg 2019;28:2238–46.
19. Lo IK, Griffin S, Kirkley A. The development of a disease-specific quality of life measurement tool for osteoarthritis of the shoulder: the Western Ontario Osteoarthritis of the Shoulder (WOOS) index. Osteoarthritis Cartilage 2001;9:771–8.
20. Simovitch R, Flurin PH, Wright T, Zuckerman JD, Roche CP. Quantifying success after total shoulder arthroplasty: the minimal clinically important difference. J Shoulder Elbow Surg 2018;27:298–305.
21. Boon AJ, Smith J. Manual scapular stabilization: its effect on shoulder rotational range of motion. Arch Phys Med Rehabil 2000;81:978–83.
22. Hertel R, Ballmer FT, Lombert SM, Gerber C. Lag signs in the diagnosis of rotator cuff rupture. J Shoulder Elbow Surg 1996;5:307–13.
23. Codman EA. The shoulder: rupture of the supraspinatus tendon and other lesions in or about the subacromial bursa. Thomas Todd; 1934.
24. Park HB, Yokota A, Gill HS, El Rassi G, McFarland EG. Diagnostic accuracy of clinical tests for the different degrees of subacromial impingement syndrome. J Bone Joint Surg Am 2005;87:1446–55.
25. Gerber C, Krushell RJ. Isolated rupture of the tendon of the subscapularis muscle: clinical features in 16 cases. J Bone Joint Surg Br 1991;73:389–94.
26. Sanders TG, Jersey SL. Conventional radiography of the shoulder. Semin Roentgenol 2005;40:207–22.
27. Zimmer Biomet. Comprehensive vault reconstruction system: surgical technique. Zimmer Biomet; 2021 [cited 2023 Jul 1]. Available from: https://www.zimmerbiomet.com/content/dam/zb-corporate/en/education-resources/surgical-techniques/specialties/shoulder/comprehensive-valult/0469.4-GLBL-en%20Comprehensive%20Vault%20Reconstruction%20System%20SurgTech-Digital1.pdf
28. Wixted CM, Goltz DE, Wickman JR, et al. Intraoperative fractures in shoulder arthroplasty: risk factors and outcomes. JSES Int 2021;5:1021–6.
29. Dolci A, Melis B, Verona M, Capone A, Marongiu G. Complications and intraoperative fractures in reverse shoulder arthroplasty: a systematic review. Geriatr Orthop Surg Rehabil 2021;12:21514593211059865.


https://doi.org/10.5397/cise.2023.00563

Original Article

Clin Shoulder Elbow 2023;26(4):351-356
https://doi.org/10.5397/cise.2023.00486

CiSE
Clinics in Shoulder and Elbow

eISSN 2288-8721

# Inpatient or outpatient total elbow arthroplasty: a comparison of patient populations and 30-day surgical outcomes from the American College of Surgeons National Surgical Quality Improvement Program

**David Momtaz[1], Farhan Ahmad[2], Aaron Singh[1], Emilie Song[3], Dean Slocum[1], Abdullah Ghali[3], Adham Abdelfattah[4]**

[1]*Department of Orthopaedics, UT Health San Antonio, San Antonio, TX, USA*
[2]*Department of Orthopedics, Rush University Medical Center, Chicago, IL, USA*
[3]*Department of Orthopedics, Baylor College of Medicine, Houston, TX, USA*
[4]*Institute of Orthopaedic Special Surgery, San Antonio, TX, USA*

**Background:** Total elbow arthroplasty (TEA) is uncommon, but growing in incidence. Traditionally an inpatient operation, a growing number are performed outpatient, consistent with general trends in orthopedic surgery. The aim of this study was to compare TEA outcomes between inpatient and outpatient surgical settings. Secondarily, we sought to identify patient characteristics that predict the operative setting.
**Methods:** Patient data were collected from the American College of Surgeons National Quality Improvement Program. Preoperative variables, including patient demographics and comorbidities, were recorded, and baseline differences were assessed via multivariate regression to predict operative setting. Multivariate regression was also used to compare postoperative complications within 30 days.
**Results:** A total of 468 patients, 303 inpatient and 165 outpatient procedures, were identified for inclusion. Hypoalbuminemia (odds ratio [OR], 2.5; P=0.029), history of chronic obstructive pulmonary disorder or pneumonia (OR, 2.4; P=0.029), and diabetes mellitus (OR, 2.5; P=0.001) were significantly associated with inpatient TEA, as were greater odds of any complication (OR, 4.1; P<0.001) or adverse discharge (OR, 4.5; P<0.001) and decreased odds of reoperation (OR, 0.4; P=0.037).
**Conclusions:** Patients undergoing inpatient TEA are generally more comorbid, and inpatient surgery is associated with greater odds of complications and adverse discharge. However, we found higher rates of reoperation in outpatient TEA. Our findings suggest outpatient TEA is safe, although patients with a higher comorbidity burden may require inpatient surgery.
**Level of evidence:** III.

**Keywords:** Inpatients; Outpatients; Elbow surgery; Upper extremity; Arthroplasty

## INTRODUCTION

Total elbow arthroplasty (TEA) is a relatively uncommon and complicated surgery. Although it was first designed to treat rheumatoid arthritis of the elbow, indications for TEA have since expanded to include inflammatory arthritis, osteoarthritis, and

Received: June 18, 2023 Revised: July 24, 2023 Accepted: August 4, 2023
Correspondence to: Abdullah Ghali
Department of Orthopedics, Baylor College of Medicine, 1 Baylor Plaza, Houston, TX 77030, USA
Tel: +1-71-3798-4951, E-mail: abdullah.ghali@bcm.edu, ORCID: https://orcid.org/0000-0002-0438-6532

Copyright© 2023 Korean Shoulder and Elbow Society.
This is an Open Access article distributed under the terms of the Creative Commons Attribution Non-Commercial License (http://creativecommons.org/licenses/by-nc/4.0/) which permits unrestricted non-commercial use, distribution, and reproduction in any medium, provided the original work is properly cited.

post-traumatic arthritis, as well as complex, unreconstructable distal humerus fractures [1].While far less common than total knee and hip arthroplasties, the number of TEA procedures performed in the United States continues to increase each year, placing a greater burden on the healthcare system [2].

One method of minimizing this increasing burden is transitioning to an outpatient setting. Studies have documented significant reductions in cost with outpatient total joint arthroplasties [3,4]. Total hip, knee, and shoulder arthroplasties have all proven safe and feasible in this setting [5,6], and projections predict that over half will be outpatient procedures by 2026 [7]. Moreover, recent data on TEA show that outpatient surgery results in decreased costs for patients [8]. While the majority of TEA procedures remain inpatient, from 2010 to 2017, the proportion of TEAs performed outpatient increased from 2.4% to 34.5% [9].

As the proportion of outpatient TEA procedures increases, it is important to monitor the outcomes resulting from this new practice pattern. The aim of this study is twofold: to characterize the patient populations undergoing inpatient and outpatient TEA, respectively, and to compare 30-day outcomes between operative settings. We hypothesize that there will be no apparent differences in these aspects of TEA between inpatient and outpatient settings.

## METHODS

This study did not require institutional review board review nor informed consent as ACS NSQIP is a pre-existing, deidentified dataset and is not considered human subjects research.

### Data Source and Collection

Data were drawn via a retrospective analysis of the American College of Surgeons (ACS) National Surgical Quality Improvement Program (NSQIP) database. The ACS NSQIP is a multi-institution, multi-center database that collects >270 patient variables from procedures performed at >500 hospitals. Trained clinical reviewers at each site input preoperative, intraoperative, 30-day postoperative, and discharge data based on the patient's Current Procedural Terminology (CPT) code. This dataset is subject to routine audits for quality assurance. We used CPT codes to identify all adults (patients >18 years of age) who underwent TEA between 2016 and 2020. Patients with incomplete records or with concurrent procedures were excluded.

To isolate the impact of surgical setting, we collected a number of preoperative variables to account for any baseline differences in the two patient populations. We collected the following patient characteristics: demographics, including age, sex, race, and ethnicity; smoking history; American Society of Anesthesiologists class; and common comorbidities such as liver disease, chronic obstructive pulmonary disorder (COPD), diabetes, congestive heart failure, hypertension, and dialysis-dependent kidney disease. Body mass index (BMI) was calculated from patient height and weight.

To assess outcomes, we collected postoperative medical complications within 30 days, including pneumonia, pulmonary embolism, cerebrovascular accidents, deep vein thrombosis, acute renal failure, urinary tract infection, cardiac arrest, and myocardial infarction. We also collected information on both superficial and deep surgical site infections, wound class, blood transfusions, reoperation within 30 days, operation time, hospital length of stay, and discharge disposition. Adverse discharge was defined as patient discharge to any location or facility other than their home.

### Statistical Analysis

Patients were stratified based on procedure setting (inpatient or outpatient). Data were analyzed to ensure assumptions were met for statistical analysis. For normally distributed data, independent sample t-tests were performed, while the Wilcoxon rank-sum test was used for non-normally distributed data. Categorical variables were assessed with Fisher's exact test or chi-square with Kendall tau test. Multiple linear and logistic regression models were also analyzed to ensure criteria were met. Perioperative outcomes with $P < 0.05$ after multivariate regression were considered significant, and results were reported as adjusted odds ratio (OR) and 95% confidence interval (CI).

Statistical analysis was performed with the IBM SPSS ver. 28.0.1.0 (IBM Corp.). Power analysis was conducted with the University of California Los Angeles' Advanced Research Computing Statistical Methods and Data Analysis G*Power Statistics tool. CIs were set at 95%, with $P = 0.05$ being considered statistically significant.

## RESULTS

### Demographics

A total of 468 patients, representing 303 inpatient and 165 outpatient procedures, was included in our analysis. In the entire study sample, the average patient age was 67 ± 13 years, with a mean BMI of 29.64 ± 7.18 kg/m$^2$. A total of 379 patients (79.1%) were female, 25 (5.3%) were Black, and 55 (11.8%) were Hispanic. There was no significant difference in mean age ($P = 0.908$) or BMI ($P = 0.870$). The mean length of stay for the inpatient cohort was 3.5 days (standard error [SE], 0.24 days), while the outpatient


https://doi.org/10.5397/cise.2023.00486

cohort had a mean length of stay, by definition, of 1 day. The mean operation time was not significantly different at 163 minutes (SE, 3.83 minutes) for the inpatient cohort compared to 160.7 minutes (SE, 5.04 minutes) for the outpatient cohort (P = 0.708).

### Postoperative Outcomes

After controlling for age, sex, ethnicity, race, and BMI through multivariate regression, we found those undergoing an inpatient procedure to be more likely to have a complication (OR, 4.1; 95% CI, 1.7–9.9; P < 0.001) or an adverse discharge disposition (OR, 4.5; 95% CI, 2.2–9.2; P < 0.001) but less likely to require reoperation (OR, 0.4; 95% CI, 0.1–0.9; P = 0.037) compared to patients undergoing an outpatient procedure. These results can be seen in Figs. 1 and 2.

### Preoperative Factors Associated with Inpatient Status

At baseline, those undergoing an inpatient procedure were more comorbid; specifically, we found that patients undergoing an inpatient procedure were more likely to have hypoalbuminemia (OR, 2.5; 95% CI, 1.0–6.2; P = 0.029), history of COPD or pneumonia (OR, 2.4; 95% CI, 1.0–5.6; P = 0.029), or diabetes (OR, 2.5; 95% CI, 1.4–4.5; P = 0.001) relative to patients undergoing outpatient procedures. These results can be seen in Figs. 1 and 2.

## DISCUSSION

We found that hypoalbuminemia, a history of COPD or pneumonia, and a diagnosis of diabetes mellitus were more prevalent in the inpatient TEA population. We also found that inpatient TEA is associated with increased odds of both complications within 30 days and adverse discharge but lower odds of reopera-

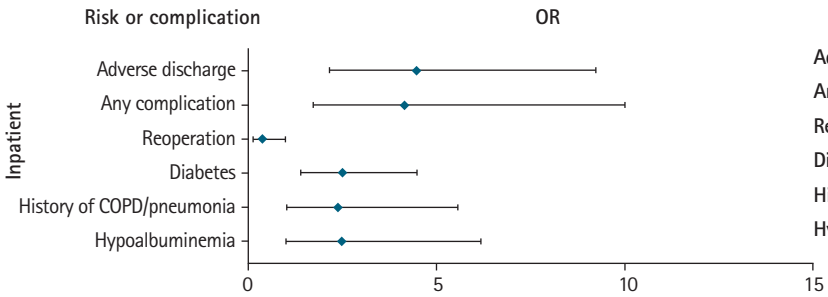


| | OR | 95% CI lower | 95% CI upper |
|---|---|---|---|
| Adverse discharge | 4.459 | 2.154 | 9.231 |
| Any complication | 4.147 | 1.722 | 9.989 |
| Reoperation | 0.367 | 0.137 | 0.982 |
| Diabetes | 2.494 | 1.390 | 4.475 |
| History of COPD/pneumonia | 2.389 | 1.023 | 5.580 |
| Hypoalbuminemia | 2.487 | 1.002 | 6.172 |

**Fig. 1.** Forest plot, odds ratios (ORs), and 95% confidence intervals (CIs) of selected outcomes or preoperative patient characteristics in the inpatient total elbow arthroplasty population. COPD: chronic obstructive pulmonary disorder.

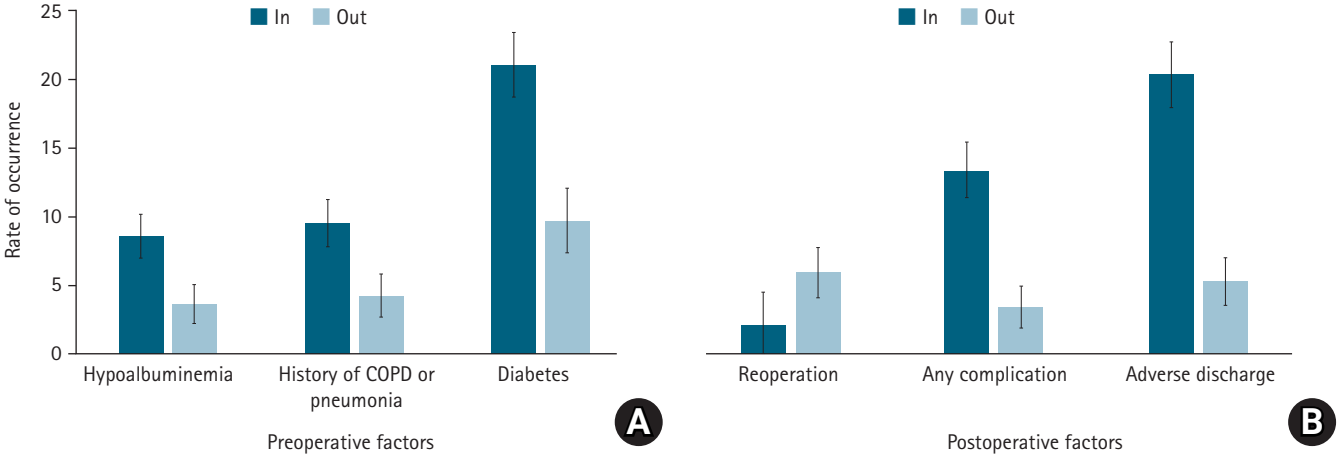


**Fig. 2.** (A, B) Bar graph representing comparative risk of selected outcomes or odds of diagnosed comorbidity in the inpatient versus outpatient total elbow arthroplasty populations. COPD: chronic obstructive pulmonary disorder.

tion. These data can aid surgeons in selecting both the operative setting and patients by providing a greater understanding of the risks involved.

Increased rates of both complications and adverse discharge in the inpatient population have been reported previously in TEA-specific studies [10] and studies on other total joint operations [5] alike. Our study provides further evidence of this trend. Furthermore, we identified specific patient characteristics and comorbidities that significantly increased the odds of an inpatient TEA procedure, which, to our knowledge, has not been done previously.

While Furman et al. [10] found no difference in TEA reoperation rates, increased reoperation rates in outpatient total joint arthroplasty have been reported [11]. Arshi et al. [12] obtained similar findings for shoulder arthroplasties—that is, reoperation rates are higher following outpatient procedures, typically due to postoperative infections. Although outpatient surgery is typically associated with significant savings, the increased rate of reoperations could make it a less cost-effective option [8,13]. Better patient selection, guided by studies such as our own, may also minimize the disparity in reoperation rates.

While Arshi et al. [12] found that reoperation due to surgical site infection was more common in the outpatient population, other studies suggest that infection rates are not significantly different between surgical settings [14]. TEA-specific studies have reported relatively high reoperation rates (up to 41%), often attributed to complications such as component loosening and periprosthetic fracture [15-17]. However, in these studies, the average time to reoperation ranged from 1.8 to >7 years. As our analysis was restricted to 30 days postoperatively, our results suggest that this discrepancy in reoperation rates is due to acute complications, such as wound infection. Therefore, better infection control may mitigate these observed differences. However, further research comparing longitudinal reoperation rates is warranted.

With respect to complications, generally, outpatient TEA has proven to be safe and produce reliable outcomes; however, we recorded significantly more complications resulting from inpatient surgery. Several studies found no difference in inpatient and outpatient complication rates; however, those studies had limitations [10,18,19]. Stone et al. [18], although they tracked complications out to 90 days, enrolled only 28 patients. The study by Albert et al. [19] was restricted to procedures performed by a single surgeon with changing practice patterns over the 18 years of perioperative data included in the study, limiting the generalizability of its findings. However, Furman et al. [10] reported results consistent with our own: greater surgical and medical complications in the inpatient setting. However, while their study had a sample size comparable to our own and a robust statistical analysis, our study drew data from more recent years; therefore, these differences are likely the result of changes over time.

We also found that the inpatient cohort had a significantly greater comorbidity burden. Specifically, our results indicate that hypoalbuminemia, COPD or pneumonia, and diabetes mellitus are associated with increased odds of an inpatient TEA procedure. Hypoalbuminemia, a sign of malnutrition, has been found to predict postoperative complications, longer hospital stays, and mortality after hip fracture repair [20]. It is also associated with postoperative complications and mortality after outpatient surgery [21]. In a related study on total shoulder arthroplasty, Mehta et al. [22] found that patients undergoing outpatient procedures were less likely to have hypoalbuminemia, further supporting this association. COPD is also associated with postoperative complications after both total hip and knee arthroplasty [23,24]; specifically, COPD patients were at increased odds of developing pneumonia, undergoing unplanned intubation, and requiring ventilator support for >48 hours within 30 days of the arthroplasty procedure.

With respect to diabetes mellitus, Jämsen et al. [25] found hemoglobin A1c (HbA1c) concentration to be an accurate predictor of perioperative hyperglycemia; nearly all patients with an HbA1c concentration ≥6.5% (a level indicating diabetes) in their study experienced hyperglycemia after hip and knee arthroplasty. Post-arthroplasty hyperglycemia is associated with increased wound complications and mortality [26]. Brophy et al. [27] found that diabetes was associated with postoperative infection in the outpatient setting; our findings indicate that surgeons are more likely to opt for an inpatient procedure with these patients. While A1c and blood sugar are important considerations when selecting candidates for outpatient surgery, proper glycemic control in diabetic patients can bring postoperative complication rates in line with those among patients without diabetes [28].

All of these characteristics are associated with increased complications and mortality after total knee and hip arthroplasty. Hypoalbuminemia, history of COPD, and uncontrolled diabetes are all considered possible exclusion criteria for outpatient total hip and knee arthroplasty [29]. Our results show that surgeons are also wisely electing to perform TEA in a setting where these patients can benefit from close postoperative monitoring. This represents the existence of a significant patient population that is limited in its access to outpatient total joint arthroplasty due to the inherent risk of complications. Future research into pre- and post-arthroplasty risk mitigation for patients with these characteristics would improve patient safety and eventually open the door for cost-saving outpatient arthroplasty.


https://doi.org/10.5397/cise.2023.00486

Our findings of greater comorbidity burden in the inpatient population are consistent with findings by Guareschi et al. [30], who found that patients undergoing inpatient shoulder arthroplasty had higher American Society of Anesthesiologists class scores relative to those undergoing outpatient procedures. These higher-risk patients with more comorbidities tend to require the more intense postoperative care offered in an inpatient setting. However, our results suggest that optimizing pre-operational patient nutrition status, identifying pulmonary function parameters that predict postoperative complications, and ensuring proper glycemic control could expand eligibility for outpatient TEA, allowing a subgroup of this traditionally inpatient population to potentially transition safely to outpatient arthroplasty.

Our study benefits from including a far larger sample size than most other extant studies. The ACS NSQIP provides cross-country sampling, allowing us to draw conclusions that should be generalizable across the United States. Additionally, we had access to numerous patient variables and demographic information, allowing us to control for key factors (common comorbidities, age, race, and BMI) that can influence outcomes. These data are important for surgeons to appropriately select candidates for outpatient surgery.

As with any study, ours has several limitations. First, this was a retrospective study, not a randomized controlled trial. Second, the ACS NSQIP, while it allows for an exceptionally large sample size representative of the country, lacks several key variables, such as patient-reported outcomes, functional outcomes, long-term outcomes, and complications beyond 30 days. We also lacked information on variables and complications specific to TEA procedures, such as aseptic loosening, ulnar neuropathy, or the different forms of prosthesis wear and failure, and were unable to account for important patient characteristics like insurance and socioeconomic status, which may have significant impacts on outcomes. Further research on these orthopedic-specific outcomes and complications is warranted.

## CONCLUSIONS

Hypoalbuminemia, COPD or pneumonia, and diabetes mellitus are significantly more prevalent in the inpatient TEA population. These patients are more comorbid and warrant the increased level of care offered with inpatient surgery. Notably, while inpatient TEA is associated with greater odds of complications and adverse discharge, it lowers the odds of reoperation. Our findings suggest that outpatient TEA is generally safe and a viable option; however, patients with a greater comorbidity burden are preferentially treated in the inpatient setting. Further research is warranted to optimize patient selection in the outpatient setting and potentially to realize significant cost savings.

## NOTES

**ORCID**

| | |
|---|---|
| David Momtaz | https://orcid.org/0000-0003-2086-5717 |
| Farhan Ahmad | https://orcid.org/0000-0001-7974-8641 |
| Aaron Singh | https://orcid.org/0000-0003-3806-3464 |
| Emilie Song | https://orcid.org/0009-0000-0960-9005 |
| Dean Slocum | https://orcid.org/0009-0008-7627-5816 |
| Abdullah Ghali | https://orcid.org/0000-0002-0438-6532 |
| Adham Abdelfattah | https://orcid.org/0000-0002-2550-9781 |


**Author contributions**

Conceptualization: FA, AG, AA. Data curation: DM. Formal analysis: DM. Investigation: FA, AS, ES, DS, AA. Methodology: DM. Project administration: AS, ES, AG. Supervision: AA. Visualization: DM, ES. Writing – original draft: FA, AS, ES, DS, AG. Writing – review & editing: DM, FA, AS, ES, DS, AG, AA.

**Conflict of interest**

None.

**Funding**

None.

**Data availability**

Contact the corresponding author for data availability.

**Acknowledgments**

None.

## REFERENCES

1. Zhang D, Chen N. Total elbow arthroplasty. J Hand Surg Am 2019;44:487–95.
2. Zhou H, Orvets ND, Merlin G, et al. Total elbow arthroplasty in the United States: evaluation of cost, patient demographics, and complication rates. Orthop Rev (Pavia) 2016;8:6113.
3. Gibon E, Parvataneni HK, Prieto HA, Photos LL, Stone WZ, Gray CF. Outpatient total knee arthroplasty: is it economically feasible in the hospital setting. Arthroplast Today 2020;6:231–5.
4. Gregory JM, Wetzig AM, Wayne CD, Bailey L, Warth RJ. Quantification of patient-level costs in outpatient total shoulder arthroplasty. J Shoulder Elbow Surg 2019;28:1066–73.
5. Erickson BJ, Shishani Y, Jones S, et al. Outpatient vs. inpatient

reverse total shoulder arthroplasty: outcomes and complications. J Shoulder Elbow Surg 2020;29:1115–20.
6. Shah RR, Cipparrone NE, Gordon AC, Raab DJ, Bresch JR, Shah NA. Is it safe? Outpatient total joint arthroplasty with discharge to home at a freestanding ambulatory surgical center. Arthroplast Today 2018;4:484–7.
7. DeCook CA. Outpatient joint arthroplasty: transitioning to the ambulatory surgery center. J Arthroplasty 2019;34:S48–50.
8. Baxter NB, Davis ES, Chen JS, Lawton JN, Chung KC. Utilization, complications, and costs of inpatient versus outpatient total elbow arthroplasty. Hand (N Y) 2023;18:509–15.
9. Pasternack JB, Mahmood B, Martins AS, Choueka J. The transition of total elbow arthroplasty into the outpatient theater. JSES Int 2020;4:44–8.
10. Furman AA, Sherman AE, Plantz MA, Marra G, Saltzman MD. Differences in 30-day outcomes between inpatient and outpatient total elbow arthroplasty (TEA). J Shoulder Elbow Surg 2020;29:2640–5.
11. Basques BA, Tetreault MW, Della Valle CJ. Same-day discharge compared with inpatient hospitalization following hip and knee arthroplasty. J Bone Joint Surg Am 2017;99:1969–77.
12. Arshi A, Leong NL, Wang C, et al. Relative complications and trends of outpatient total shoulder arthroplasty. Orthopedics 2018;41:e400–9.
13. Lovald ST, Ong KL, Malkani AL, et al. Complications, mortality, and costs for outpatient and short-stay total knee arthroplasty patients in comparison to standard-stay patients. J Arthroplasty 2014;29:510–5.
14. Lands H, Harm R, Hill M, Patel K, Spanyer J. Outpatient total hip and knee arthroplasty exhibit similar early complication rates to inpatient procedures. J Orthop 2021;27:69–73.
15. Perretta D, van Leeuwen WF, Dyer G, Ring D, Chen N. Risk factors for reoperation after total elbow arthroplasty. J Shoulder Elbow Surg 2017;26:824–9.
16. Park JG, Cho NS, Song JH, Lee DS, Rhee YG. Clinical outcomes of semiconstrained total elbow arthroplasty in patients who were forty years of age or younger. J Bone Joint Surg Am 2015;97:1781–91.
17. Celli A, Morrey BF. Total elbow arthroplasty in patients forty years of age or less. J Bone Joint Surg Am 2009;91:1414–8.
18. Stone MA, Singh P, Rosario SL, Omid R. Outpatient total elbow arthroplasty: 90-day outcomes. J Shoulder Elbow Surg 2018;27:1311–6.
19. Albert BM, Lee A, McLendon TW, Devereaux RS, Odum CC, Foulkes GD. Is total elbow arthroplasty safe as an outpatient procedure. J Surg Orthop Adv 2017;26:25–8.
20. Aldebeyan S, Nooh A, Aoude A, Weber MH, Harvey EJ. Hypoalbuminaemia: a marker of malnutrition and predictor of postoperative complications and mortality after hip fractures. Injury 2017;48:436–40.
21. Curran S, Apruzzese P, Kendall MC, De Oliveira G. The impact of hypoalbuminemia on postoperative outcomes after outpatient surgery: a national analysis of the NSQIP database. Can J Anaesth 2022;69:1099–106.
22. Mehta N, Bohl DD, Cohn MR, et al. Trends in outpatient versus inpatient total shoulder arthroplasty over time. JSES Int 2022;6:7–14.
23. Yakubek GA, Curtis GL, Sodhi N, et al. Chronic obstructive pulmonary disease is associated with short-term complications following total hip arthroplasty. J Arthroplasty 2018;33:1926–9.
24. Yakubek GA, Curtis GL, Khlopas A, et al. Chronic obstructive pulmonary disease is associated with short-term complications following total knee arthroplasty. J Arthroplasty 2018;33:2623–6.
25. Jämsen E, Nevalainen PI, Eskelinen A, Kalliovalkama J, Moilanen T. Risk factors for perioperative hyperglycemia in primary hip and knee replacements. Acta Orthop 2015;86:175–82.
26. Stryker LS, Abdel MP, Morrey ME, Morrow MM, Kor DJ, Morrey BF. Elevated postoperative blood glucose and preoperative hemoglobin A1C are associated with increased wound complications following total joint arthroplasty. J Bone Joint Surg Am 2013;95:808–S2.
27. Brophy RH, Bansal A, Rogalski BL, et al. Risk factors for surgical site infections after orthopaedic surgery in the ambulatory surgical center setting. J Am Acad Orthop Surg 2019;27:e928–34.
28. Wukich DK. Diabetes and its negative impact on outcomes in orthopaedic surgery. World J Orthop 2015;6:331–9.
29. Ardon AE. Safety considerations for outpatient arthroplasty. Clin Sports Med 2022;41:281–9.
30. Guareschi AS, Eichinger JK, Friedman RJ. Patient outcomes after revision total shoulder arthroplasty in an inpatient vs. outpatient setting. J Shoulder Elbow Surg 2023;32:82–8.


https://doi.org/10.5397/cise.2023.00486

Original Article

Clin Shoulder Elbow 2023;26(4):357-365
https://doi.org/10.5397/cise.2023.00465

CiSE
Clinics in Shoulder and Elbow

eISSN 2288-8721

# Concomitant open distal clavicle excision is associated with greater improvement in range of motion without increased risk of acromial stress fracture after reverse total shoulder arthroplasty: a retrospective cohort study

**Ajay C. Kanakamedala*, Dhruv S. Shankar*, Neil Gambhir*, Matthew R. Boylan*, Michael Boin*, Matthew G. Alben*, Mandeep S. Virk, Young W. Kwon**

*Department of Orthopedic Surgery, New York University Langone Health, New York, NY, USA*

**Background:** The purpose of this study was to evaluate the effect of concomitant open distal clavicle excision (DCE) on postoperative clinical outcomes and incidence of acromial and scapular stress fractures (ASFs) in patients with symptomatic acromioclavicular joint osteoarthritis (ACJ OA) undergoing reverse total shoulder arthroplasty (RTSA).

**Methods:** A single-surgeon retrospective cohort study was conducted including patients who underwent primary elective RTSA with or without DCE from 2015 to 2019 with a minimum 6-month follow-up period. Shoulder active range of motion (AROM) and visual analog scale (VAS) pain were recorded preoperatively and postoperatively. ASFs and other adverse events were identified using postoperative notes and/or radiographs. Characteristics and outcomes were compared between the RTSA and RTSA-DCE groups.

**Results:** Forty-six RTSA patients (mean age, 67.9±8.7 years; 60.9% male; mean follow-up, 24.9±16.6 months) and 70 RTSA-DCE patients (mean age, 70.2±8.9 years; 20.0% male; mean follow-up, 22.7±12.9 months) were included. There were no significant intergroup differences in rates of ASF (RTSA, 0.0% vs. RTSA-DCE, 1.4%; P=1.00), stress reactions (RTSA, 8.7% vs. RTSA-DCE, 11.4%; P=0.76), reoperation, revision, or infection (all P>0.05), or in pre-to-postoperative reduction in VAS pain (P=0.17) at latest follow-up. However, the RTSA-DCE group had greater pre-to-postoperative improvement in flexion AROM (RTSA, 43.7°±38.5° vs. RTSA-DCE, 59.5°±33.4°; P=0.03) and internal rotation (IR) AROM (P=0.02) at latest follow-up.

**Conclusions:** Concomitant DCE in RTSA improves shoulder flexion and IR AROM, alleviates shoulder pain, and does not increase the risk of ASFs.

**Level of evidence:** III.

**Keywords:** Arthroplasty, Replacement, Shoulder; Osteoarthritis; Acromioclavicular joint; Rotator cuff tear arthropathy

Received: June 14, 2023 Revised: August 21, 2023 Accepted: August 30, 2023te

Correspondence to: Young W. Kwon
Department of Orthopedic Surgery, New York University Langone Health, 333 East 38th St, 4th Floor, New York, NY 10016, USA
Tel: +1-646-501-7223, E-mail: Young.Kwon@nyulangone.org, ORCID: https://orcid.org/0000-0001-6048-2548

*Current affiliation
Ajay C. Kanakamedala: The Steadman Clinic, Vail, CO, USA
Dhruv S. Shankar: Department of Orthopaedics and Sports Medicine, University of Washington School of Medicine, Seattle, WA, USA
Neil Gambhir: Department of Medicine, Lenox Hill Hospital, New York, NY, USA
Matthew R. Boylan: Orlin & Cohen Orthopedic Group, Port Jefferson, NY, USA
Michael Boin: North Kansas City Hospital, North Kansas City, MO, USA
Matthew G. Alben: Department of Orthopedics and Sports Medicine, Jacobs School of Medicine and Biomedical Sciences, University at Buffalo, Buffalo, NY, USA

Copyright© 2023 Korean Shoulder and Elbow Society.
This is an Open Access article distributed under the terms of the Creative Commons Attribution Non-Commercial License (http://creativecommons.org/licenses/by-nc/4.0/) which permits unrestricted non-commercial use, distribution, and reproduction in any medium, provided the original work is properly cited.

# INTRODUCTION

Acromioclavicular joint (ACJ) osteoarthritis (OA) is common in patients with rotator cuff disorders, which accounts for a large proportion of patients undergoing reverse total shoulder arthroplasty (RTSA) [1,2]. Severe ACJ OA with ankylosis is a potential risk factor for acromial and scapular stress fractures (ASFs) after RTSA [3]. ACJ OA may increase the risk of ASFs after RTSA due to loss of motion through the ACJ and compensatory motion through the glenohumeral joint. This could, in turn, lead to increased compensatory deltoid muscle activity and increased stress at the acromion and scapular spine [3,4]. Even in the absence of ACJ OA, ASFs can occur after RTSA due to the increased demand placed on the deltoid as well as the presence of certain risk factors such as female sex, osteoporosis, and inflammatory arthritis [5-7].

Patients undergoing RTSA who have comorbid symptomatic ACJ OA may benefit from concomitant distal clavicle excision (DCE), which can relieve ACJ-related pain and improve shoulder function [8]. By reducing ACJ stiffness, concomitant DCE could restore scapulothoracic motion and reduce the risk of postoperative ASF. In the setting of RTSA, however, the coracoacromial (CA) ligament is frequently transected to assist in exposure, which may increase stress on the acromion and scapula and increase the risk of postoperative ASF [9,10]. In CA ligament deficiency, DCE could further disrupt the scapular ring and theoretically predispose patients to greater scapular and acromial stresses and increased risk of ASF. There are few published data comparing outcomes between patients who underwent RTSA with DCE versus those who underwent RTSA alone, and the effect of concomitant DCE on clinical outcomes after RTSA is not well understood.

The purpose of this study was to evaluate the effect of concomitant open DCE on postoperative clinical outcomes and incidence of ASFs in patients with symptomatic ACJ OA undergoing RTSA. We hypothesized that there would be no differences in clinical outcomes or incidence of ASFs between patients undergoing RTSA with versus without DCE based on anecdotal evidence from the senior author (YWK)'s experience performing the concomitant DCE procedure without observing any increased incidence of ASFs or other adverse events.

# METHODS

This study was conducted in compliance with the principles of the Declaration of Helsinki. The study's protocol was reviewed and approved by the Institutional Review Board of New York University Langone Health (No. 21-01089). The requirement for informed consent was waived.

### Study Design

A single-center, single-surgeon retrospective cohort study was conducted.

### Eligibility Criteria and Cohort Selection

Patients who underwent primary RTSA with a shoulder and elbow fellowship-trained orthopedic surgeon (YWK) at a single urban academic medical center between February 1, 2015 and December 31, 2019 were identified using the senior author's institutional database. Subjects were included in the cohort if they were ≥18 years of age at the time of surgery, underwent elective primary RTSA for the indication of cuff tear arthropathy, massive irreparable cuff tear, or primary glenohumeral OA (see "Diagnostic Criteria and Surgical Indications"), and had minimum follow-up of 6 months. This minimum follow-up time was based on prior studies of ASF incidence after RTSA with minimum 3-month follow-up but found that a significant number of ASFs took place between 3 and 6 months postoperatively [5,6,11]. Subjects were excluded from the cohort if they had a prior history of proximal humerus fracture and/or glenoid fracture, underwent revision RTSA, or underwent RTSA for the indication of proximal humerus fracture, glenoid fracture, rheumatoid arthritis, or avascular necrosis of the humeral head.

### Diagnostic Criteria and Surgical Indications

The primary indications for RTSA among the study cohort were (1) symptomatic cuff tear arthropathy, (2) massive irreparable cuff tear associated with pain, pseudoparalysis, and/or range of motion (ROM) limitations, and (3) primary glenohumeral OA in patients ≥70 years old and/or with rotator cuff insufficiency identified intraoperatively. RTSA was preferred over other surgical interventions (e.g., anatomic TSA) in patients ≥70 years old with low functional demand, adequate glenoid bone stock, and intact deltoid muscle function. RTSA was contraindicated in patients with a non-functional deltoid.

Cuff tear arthropathy and massive cuff tears were diagnosed based on a combination of clinical and radiographic findings. Presenting symptoms included shoulder pain with motion, pain at night (particularly when sleeping on the affected shoulder), and/or reduced ROM. Physical exam findings included supraspinatus/infraspinatus atrophy and/or pseudoparalysis. Superior migration of the humeral head (defined as an acromiohumeral interval <7 mm) with or without acetabularization of the acromial undersurface on plain radiographs in the setting of a chron-


https://doi.org/10.5397/cise.2023.00465

ic rotator cuff tear was considered to be evidence of cuff tear arthropathy. Rotator cuff tears were identified on magnetic resonance imaging (MRI) and confirmed intraoperatively. Computed tomography (CT) imaging was not routinely obtained since all patients had MRI scans available, which were suitable for both prosthetic planning and identification of soft tissue pathology.

DCE was indicated in patients with symptomatic ACJ OA. The diagnosis of ACJ OA was made on the basis of findings on an anteroposterior radiograph of the shoulder (i.e., joint space narrowing, subchondral sclerosis and cysts, osteophyte formation) and on physical exam (i.e. focal tenderness to palpation over the ACJ, positive scarf test, positive resisted ACJ extension test, positive O'Brien's test) and was confirmed intraoperatively. DCE was not performed in patients with radiographic evidence of ACJ OA without positive physical exam findings.

### Operative Technique and Postoperative Rehabilitation

All RTSA procedures were performed using a deltopectoral approach without violating the CA ligament. The DJO Altivate Reverse Total Shoulder Prosthesis system (DJO Global) with a lateralized glenosphere and an inlay humeral stem was used for all cases. If the subscapularis was present, a subscapularis tenotomy was performed to achieve adequate exposure of the glenohumeral joint; the tendon was repaired at the end of the case.

All DCE procedures were performed after insertion of the prostheses. The CA ligament was resected, the distal clavicle and ACJ were identified in the superior portion of the wound, and approximately 10 mm of the distal clavicle was resected using a high-speed burr and small osteotomes. The CA ligament was preserved in all RTSA cases and was resected in all RTSA-DCE cases. Drains were used in all cases and removed on postoperative day 1.

Regardless of procedure (RTSA or RTSA-DCE), all patients followed the same postoperative protocol. Patients were immobilized in a sling for up to 4 weeks. Passive shoulder ROM exercises including forward flexion as tolerated in the plane of the scapula and external rotation (ER) to 20° past neutral and isometric deltoid strengthening exercises were started on postoperative day 1. Active-assisted and active ROM (AROM) exercises and isometric ER exercises were started at 4 to 6 weeks postoperatively.

### Demographic and Preoperative Data

Demographic information was obtained via chart review and included age at time of surgery, sex, body mass index (BMI) at time of surgery, American Society of Anesthesiologists (ASA) physical status classification, and smoking history. Prior medical history was also obtained from chart review including primary indication for RTSA and history of diabetes mellitus, chronic kidney disease, rheumatological disease, and/or osteoporosis. Subjects reported their preoperative level of shoulder pain on a 10-point visual analog scale (VAS) with zero indicating no pain and 10 indicating the worst possible pain.

### Radiographic Data

Severity of cuff tear arthropathy, glenohumeral OA, and ACJ OA were assessed on plain radiographs. Cuff tear arthropathy was graded using the Hamada classification system [12]. Glenohumeral OA and ACJ OA were graded using the Kellgren-Lawrence classification system [13].

### Active ROM Measurement

Shoulder AROM for flexion, ER, and internal rotation (IR) were measured preoperatively and at latest follow-up. Flexion and ER AROM were measured in degrees (°). IR AROM was reported on an 8-point scale previously described by Flurin et al. [14] and Mollon et al. [15] based on the highest vertical distance that the subject could reach behind their back (e.g., hip, buttock, sacrum, vertebral level) during the physical exam (Table 1).

### Outcomes Measured

The primary outcome measured was the incidence of ASFs. For the purposes of this study, ASFs were defined as ASFs visualized on plain radiographs in the presence or absence of associated symptoms (focal pain or tenderness to palpation over the acromion or scapular spine). Secondary outcomes included the incidence of other postoperative adverse events (acromial stress reactions, all-cause reoperations, all-cause revisions, non-infectious revisions, prosthetic joint infections), pre-to-postoperative change in VAS pain, and pre-to-postoperative change in flexion,

**Table 1.** Operationalized scale for surgeon-observed shoulder active IR ROM

| Observed IR ROM* | IR score |
|---|---|
| 0° | 0 |
| 15° of IR or motion to hip | 1 |
| 30° of IR or motion to buttock/PSIS/SI joint | 2 |
| 45° of IR or motion to sacrum | 3 |
| 60° of IR or motion to L4 to L5 | 4 |
| 75° of IR or motion to L1 to L3 | 5 |
| 90° of IR or motion to T8 to T12 | 6 |
| > 90° of IR or motion to T7 or above | 7 |

IR: internal rotation, ROM: range of motion, PSIS: posterior superior iliac spine, SI: sacroiliac.
*Determined based on highest vertical distance that the subject could reach behind their back.

ER, and IR AROM. Acromial stress reactions were defined as focal pain or tenderness to palpation over the acromion or scapular spine in the absence of radiographic changes [6]. Reoperations were defined as any subsequent surgery involving the index shoulder while revisions were defined as any subsequent procedure involving replacement of one or more components of the original prosthesis. All secondary outcomes were abstracted from postoperative notes, radiographs, and MRI scans.

### Statistical Analysis

All statistical analyses were performed in SAS Studio ver. 9.4 (SAS Institute). All continuous variables were assessed for normality using the Shapiro-Wilk test. Normally distributed continuous variables were compared between groups using Student t-test. Non-normally distributed continuous variables were compared between groups using the Mann-Whitney U-test. Pre-to-postoperative change in VAS pain and AROM was evaluated using the paired t-test or Wilcoxon signed-rank test, as appropriate. Categorical variables were compared between groups using Fisher's exact test. Multivariable linear and logistic regression were used to identify predictors of continuous and binary outcomes, respectively. Each regression model included the following predictors: DCE, procedure indication, age, sex, BMI, smoking history, comorbidities, glenohumeral OA grade, and ACJ OA grade. Subgroup analyses were performed for subjects with CTA (with Hamada classification included as a co-predictor) and for subjects with primary glenohumeral OA. Linear regression results were reported as beta (β) coefficients with 95% confidence intervals (CIs) and logistic regression results were reported as odds ratios (ORs) with 95% CIs. All P-values $<0.05$ were considered significant.

## RESULTS

### Demographic and Clinical Characteristics

Three hundred twenty-six patients were screened for inclusion in the study, of whom 116 met eligibility criteria (Fig. 1). Of the 116 included subjects, 46 underwent RTSA without DCE and 70 underwent RTSA with DCE. Demographic and clinical characteristics were compared between groups (Table 2). The RTSA cohort had a mean age of 67.9 ± 8.7 years (range, 43–87 years) and the RTSA-DCE cohort had a mean age of 70.2 ± 8.9 years (range, 51–95 years). Pluralities of patients in both groups underwent RTSA for treatment of cuff tear arthropathy (RTSA, 56.5%, RTSA-DCE, 47.1%), but a significantly higher proportion of RTSA-DCE patients underwent surgery for treatment of primary glenohumeral OA (RTSA, 21.7% vs. RTSA-DCE, 44.3%; $P<0.001$). The RTSA group had a significantly lower proportion of never smokers ($P=0.02$) and a significantly lower proportion of patients indicated for RTSA due to primary glenohumeral OA ($P=0.02$), but age, BMI, ASA classification, glenohumeral OA grade, ACJ OA grade, incidence of comorbidities, and follow-up time did not significantly differ between the two groups (all $P>0.05$).

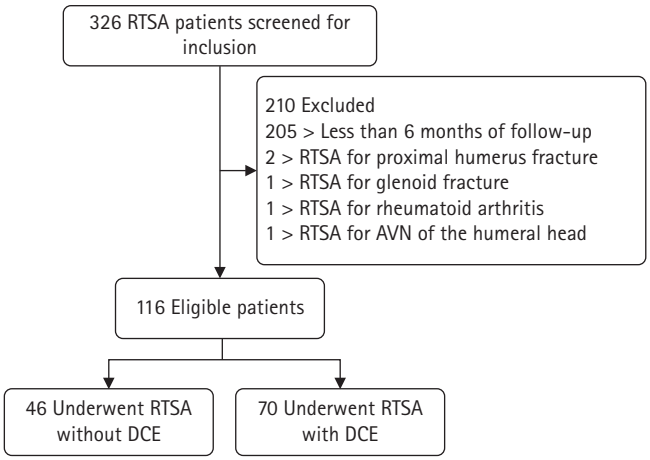


**Fig. 1.** Patient flowchart. RTSA: reverse total shoulder arthroplasty, AVN: avascular necrosis, DCE: distal clavicle excision.

### Postoperative Outcomes and AROM

Postoperative outcomes and shoulder AROM were compared between the RTSA and RTSA-DCE groups (Table 3). No ASFs occurred in the RTSA group by latest follow-up. Only one ASF occurred in the RTSA-DCE group by latest follow-up; this patient was a 65-year-old female with prior history of chronic kidney disease and osteoporosis who underwent RTSA for a primary indication of glenohumeral OA. The most common postoperative adverse events were acromial stress reactions (RTSA, 8.7%; RTSA-DCE, 11.4%) and all-cause reoperations (RTSA, 10.9%; RTSA-DCE, 4.3%). There were no significant inter-group differences in the incidence of acromial stress reactions, all-cause reoperations, all-cause revisions, non-infectious revisions, or prosthetic joint infections (all $P>0.05$). Both groups experienced significant pre-to-postoperative reduction in VAS pain (both $P<0.001$), but the magnitude of this reduction was not significantly different between the two groups ($P=0.17$).

Prior to surgery, the RTSA group had significantly higher flexion AROM ($P=0.04$) and IR AROM ($P=0.04$) but not ER AROM ($P=0.32$). Both groups experienced significant pre-to-postoperative improvement in flexion AROM and ER AROM (all $P<0.001$), but only the RTSA-DCE group experienced significant improvement in IR AROM ($P<0.001$). Improvement in flexion AROM and IR AROM was significantly


https://doi.org/10.5397/cise.2023.00465

**Table 2.** Demographic and clinical characteristics

| Variable | RTSA (n = 46) | RTSA-DCE (n = 70) | P-value |
|---|---|---|---|
| Age (yr) | 67.9 ± 8.7 | 70.2 ± 8.9 | 0.18[†] |
| Sex | | | < 0.001[‡,‖] |
| Male | 28 (60.9) | 14 (20.0) | |
| Female | 18 (39.1) | 56 (80.0) | |
| BMI | 30.9 ± 6.8 | 31.1 ± 7.1 | 0.72[†] |
| ASA classification | | | 0.42[‡] |
| I | 0 | 1 (1.4) | |
| II | 18 (39.1) | 25 (35.7) | |
| III | 24 (52.2) | 42 (60.0) | |
| IV | 4 (8.7) | 2 (2.9) | |
| Smoking history | | | 0.02[‡,‖] |
| Never | 16 (34.8) | 38 (54.3) | |
| Former | 29 (63.0) | 26 (37.1) | |
| Current | 1 (2.2) | 6 (8.6) | |
| Procedure indication | | | 0.02[‡,‖] |
| CTA | 26 (56.5) | 33 (47.1) | |
| MIRCT | 10 (21.7) | 6 (8.6) | |
| GH OA | 10 (21.7) | 31 (44.3) | |
| Hamada classification* | | | 0.21[‡] |
| I | 2 (7.7) | 3 (9.1) | |
| II | 2 (7.7) | 4 (12.1) | |
| III | 6 (23.1) | 4 (12.1) | |
| IVA | 10 (38.5) | 6 (18.2) | |
| IVB | 3 (11.5) | 12 (36.4) | |
| V | 3 (11.5) | 4 (12.1) | |
| KL grade of GH OA | | | 0.06[‡] |
| KL0 | 4 (8.7) | 3(4.3) | |
| KL1 | 4 (8.7) | 3 (4.3) | |
| KL2 | 10 (21.7) | 5 (7.1) | |
| KL3 | 8 (17.4) | 13 (18.6) | |
| KL4 | 20 (43.5) | 46 (65.7) | |
| KL grade of ACJ OA | | | 0.08[‡] |
| KL0 | 6 (13.0) | 5 (7.1) | |
| KL1 | 0 | 5 (7.1) | |
| KL2 | 11 (23.9) | 28 (40.0) | |
| KL3 | 18 (39.1) | 22 (31.4) | |
| KL4 | 11 (23.9) | 10 (14.3) | |
| Diabetes | 10 (21.7) | 22 (31.4) | 0.29[‡] |
| Chronic kidney disease | 5 (10.9) | 11 (15.7) | 0.59[‡] |
| Rheumatological disease | 2 (4.4) | 9 (12.9) | 0.20[‡] |
| Osteoporosis | 6 (13.0) | 11 (15.7) | 0.79[‡] |
| Follow-up time (mo) | 24.9 ± 16.6 | 22.7 ± 12.9 | 0.75[§] |

Values are presented as mean ± standard deviation or number (%).
RTSA: reverse total shoulder arthroplasty, RTSA-DCE: reverse total shoulder arthroplasty and concomitant open distal clavicle excision, BMI: body mass index, ASA: American Society of Anesthesiologists, CTA: cuff tear arthropathy, MIRCT: massive irreparable rotator cuff tear, GH OA: glenohumeral osteoarthritis, KL: Kellgren-Lawrence, ACJ OA: acromioclavicular joint osteoarthritis.
*Among patients with a primary indication of cuff tear arthropathy; P-values for [†]Student t-test, [‡]Fisher's exact test, [§]Mann-Whitney U-test, [‖]P < 0.05.

higher in the RTSA-DCE group (all P < 0.05), but there was no significant inter-group difference in ER AROM improvement (P = 0.38).

**Table 3.** Postoperative outcomes and shoulder AROM

| Variable | RTSA (n = 46) | RTSA-DCE (n = 70) | P-value |
|---|---|---|---|
| Postoperative outcome | | | |
| Acromial stress fracture | 0 | 1 (1.4) | 1.00[§] |
| Acromial stress reaction | 4 (8.7) | 8 (11.4) | 0.76[§] |
| All-cause reoperation | 5 (10.9) | 3 (4.3) | 0.26[§] |
| All-cause revision | 3 (6.5) | 3 (4.3) | 0.68[§] |
| Non-infectious revision | 1 (2.2) | 2 (2.9) | 1.00[§] |
| Prosthetic joint infection | 2 (4.4) | 1 (1.4) | 0.56[§] |
| VAS pain | | | |
| Preoperative | 5.6 ± 2.6 | 6.5 ± 3.0 | 0.12[‖] |
| Postoperative | 2.3 ± 2.8 | 2.4 ± 2.6 | 0.92[‖] |
| Change* | −3.2 ± 2.6 (P < 0.001[‡]) | -4.1 ± 3.5 (P < 0.001[‡]) | 0.17[‖] |
| Shoulder AROM | | | |
| Flexion (°) | | | |
| Preoperative | 100.5 ± 38.5 | 84.6 ± 36.7 | 0.04[‡,¶] |
| Postoperative | 143.0 ± 30.0 | 144.1 ± 27.3 | 0.81[¶] |
| Change* | 43.7 ± 38.5 (P < 0.001[‡]) | 59.5 ± 33.4 (P < 0.001[‡]) | 0.03[‡,¶] |
| External rotation (°) | | | |
| Preoperative | 29.3 ± 16.1 | 25.9 ± 15.2 | 0.32[¶] |
| Postoperative | 40.7 ± 10.6 | 41.3 ± 8.7 | 0.81[¶] |
| Change* | 11.6 ± 16.6 (P < 0.001[‡]) | 15.6 ± 15.8 (P < 0.001[‡]) | 0.38[¶] |
| Internal rotation (scale)[†] | | | |
| Preoperative | 3.8 ± 1.5 | 3.0 ± 1.6 | 0.02[‡,‖] |
| Postoperative | 4.0 ± 1.5 | 3.9 ± 1.4 | 0.58[‖] |
| Change* | 0.2 ± 1.5 (P = 0.57) | 1.0 ± 1.7 (P < 0.001[‡]) | 0.02[‡,‖] |

Values are presented as number (%) or mean ± standard deviation.
AROM: active range of motion, RTSA: reverse total shoulder arthroplasty, RTSA-DCE: reverse total shoulder arthroplasty and concomitant open distal clavicle excision, VAS: visual analog scale.
*Pre-to-postoperative change reported with P-value for paired t-test or Wilcoxon signed-rank test; [†]See Table 1 for details; [‡]P < 0.05; P-values for [§]Fisher's exact test, [‖]Mann-Whitney U-test, [¶]Student t-test.

## Predictors of Postoperative Outcomes

Significant predictors of postoperative outcomes and shoulder AROM were identified (Table 4). Among all subjects, DCE was not significantly predictive of the odds of ASF, acromial stress reaction, or any other postoperative adverse event (all P > 0.05). However, DCE was predictive of greater pre-to-postoperative improvement in flexion AROM (P = 0.006) and IR AROM (P = 0.04). Higher BMI was associated with increased odds of all-cause reoperation (P = 0.03) and all-cause revision (P = 0.04). Primary indication of glenohumeral OA was predictive with lower odds of acromial stress reaction (P = 0.049) and greater improvement in ER AROM (P = 0.01) and IR AROM (P = 0.03) compared to primary indication of cuff tear arthropathy. Conversely, primary indication of massive irreparable rotator cuff tear was asso-

**Table 4.** Predictors of postoperative outcomes and shoulder AROM

| Outcome | Significant predictor* | β or OR (95% CI) | P-value |
|---|---|---|---|
| All subjects (n = 116) | | | |
| Acromial stress fracture | None | - | - |
| Acromial stress reaction | GH OA (vs. CTA) | OR, 0.1 (0.0 to 1.0) | 0.05 |
| All-cause reoperation | BMI | OR, 1.3 (1.0 to 1.6) | 0.03 |
| All-cause revision | BMI | OR, 1.5 (1.0 to 2.2) | 0.04 |
| Non-infectious revision | None | - | - |
| Prosthetic joint infection | None | - | - |
| Change in flexion AROM (°) | DCE | β, 22.4 (6.7 to 38.1) | 0.01 |
| Change in ER AROM (°) | MIRCT (vs. CTA) | β, −10.9 (−21.1 to −0.8) | 0.04 |
| | GH OA (vs. CTA) | β, 8.8 (1.9 to 15.8) | 0.01 |
| Change in IR AROM (scale)† | DCE | β, 0.9 (0.1 to 1.8) | 0.04 |
| | GH OA (vs. CTA) | β, 0.9 (0.1 to 1.8) | 0.03 |
| Change in VAS pain | None | - | - |
| Subjects with CTA (n = 59) | | | |
| Change in flexion AROM (°) | None | - | - |
| Change in ER AROM (°) | Current smoker (vs. never) | β, −21.6 (−40.8 to −2.5) | 0.03 |
| | Rheumatological disease | β, −17.6 (−32.9 to −2.4) | 0.02 |
| Change in IR AROM (scale)† | DCE | β, 1.2 (0.1 to 2.3) | 0.04 |
| | Osteoporosis | β, 2.3 (0.1 to 4.6) | 0.04 |
| Change in VAS pain | None | - | - |
| Subjects with GH OA (n = 41) | | | |
| Change in flexion AROM (°) | DCE | β, 31.6 (4.2 to 59.0) | 0.03 |
| | Current smoker (vs. never) | β, −44.6 (−83.3 to −5.9) | 0.03 |
| Change in ER AROM (°) | Current smoker (vs. never) | β, −26.4 (−49.1 to −3.6) | 0.02 |
| Change in IR AROM (scale)† | DCE | β, 2.0 (0.2 to 3.9) | 0.03 |
| | Female sex | β, −2.6 (−4.9 to −0.3) | 0.03 |
| Change in VAS pain | None | - | - |

AROM: active range of motion, β: beta regression coefficient, OR: odds ratio, CI: confidence interval, GH OA: glenohumeral osteoarthritis, CTA: cuff tear arthropathy, BMI: body mass index, DCE: distal clavicle excision, ER: external rotation, MIRCT: massive irreparable rotator cuff tear, IR: internal rotation, VAS: visual analog scale.
*Significance defined as associated P-value < 0.05; †See Table 1 for details.

ciated with reduced improvement in ER AROM (P = 0.04) compared to primary indication of cuff tear arthropathy.

### Subgroup Analysis by Procedure Indication

When subgrouping the cohort by procedure indication (Table 4), DCE was found to be predictive of greater improvement in IR AROM (P = 0.04) among patients with cuff tear arthropathy and greater improvement in both flexion AROM (P = 0.03) and IR AROM (P = 0.03) among patients with primary glenohumeral OA. In addition, current smoker status (vs. never smoker status) was predictive of reduced improvement in ER AROM (P = 0.03) among patients with cuff tear arthropathy and reduced improvement in both flexion AROM (P = 0.03) and ER AROM (P = 0.02) among patients with primary glenohumeral OA.

## DISCUSSION

### Main Findings

The most important finding of this study was that RTSA with concomitant DCE was not associated with higher odds of postoperative ASF compared to RTSA without DCE, thus supporting the hypothesis of the study. Moreover, DCE was not associated with the odds of any other postoperative adverse events including acromial stress reactions, all-cause reoperations, all-cause revisions, non-infectious revisions, or PJIs. In contrast, DCE was associated with greater pre-to-postoperative improvement in both flexion AROM and IR AROM. In addition, DCE was predictive of greater improvement in flexion AROM and IR AROM among RTSA patients with primary glenohumeral OA and greater improvement in IR AROM among RTSA patients with cuff tear arthropathy. DCE was not found to be predictive of pre-to-postoperative improvement in VAS shoulder pain.


https://doi.org/10.5397/cise.2023.00465

### Concomitant DCE and Acromial Stress Fracture Risk

Prior retrospective studies involving large cohorts of RTSA patients identified risk factors for postoperative ASF including older age, female sex, osteoporosis, and inflammatory arthritis, but none to date assessed whether concomitant DCE is a predictive factor for risk of ASF [6,7]. Likewise, while open DCE has been associated with common complications such as wound disruption, hematoma, and surgical site infection, neither isolated procedures nor concomitant procedures with RTSA were associated with increased rates of ASF in prior retrospective analyses [16,17]. In contrast, in a retrospective case-control study of 11 primary RTSA patients with postoperative ASFs matched to 44 controls, Townsend et al. [3] noted that 20% of the control group had radiographic evidence of a prior DCE or ACJ coplaning procedure, whereas no patients in the ASF group had undergone prior ACJ surgeries. Though Townsend et al. [3] did not find the difference in ACJ procedure rates to be statistically significant, they did hypothesize that DCE was a protective factor against ASF following RTSA. The lone patient in the present study who experienced a postoperative ASF had undergone RTSA with concomitant DCE, but also had known risk factors for ASF including older age, female sex, and history of osteoporosis. As such, the results of the present study do not suggest that concomitant DCE is a predictive factor for the risk of ASF following RTSA. This finding has two major caveats in that (1) only one patient in the entire cohort experienced an ASF by latest follow-up and (2) this study did not include a comparison group of patients with symptomatic ACJ OA who underwent RTSA without DCE.

### Concomitant DCE and Shoulder ROM

The impact of DCE on shoulder ROM has been studied primarily in the setting of concomitant rotator cuff repair (RCR) as opposed to RTSA, and the highest-quality evidence available suggests that DCE does not have a significant effect on postoperative ROM. Wang et al. [18] conducted a meta-analysis of three randomized controlled trials involving 208 patients (91 RCR-DCE, 117 RCR) and found no significant difference in flexion, IR, or ER ROM between the two groups at minimum 2-year follow-up. Similarly, in one of the few studies conducted in the RTSA population, Cirigliano et al. [17] performed a retrospective matched-cohort analysis of 39 RTSA-DCE patients matched to 39 RTSA patients and found no significant differences in postoperative flexion, abduction, ER, or IR ROM between the two groups at minimum 2-year follow-up. In addition, while both groups experienced significant pre-to-postoperative improvement in flexion and abduction ROM and no significant change in IR ROM, the RTSA-DCE group experienced a significant decrease in ER ROM whereas the RTSA group did not. Thus, the prior evidence up to this point has not found concomitant DCE to have a significant positive impact on postoperative shoulder ROM.

In contrast to the Cirigliano et al.'s study [17], in the present study we found RTSA-DCE to be associated with significant pre-to-postoperative improvement in ER ROM as well as flexion and IR ROM, and furthermore, the improvements in flexion and IR ROM were significantly greater than those of the RTSA group. RTSA-DCE patients had significantly lower preoperative flexion and IR ROM compared to their RTSA counterparts, which suggests that RTSA patients with clinically symptomatic ACJ OA may have inferior baseline shoulder ROM compared to RTSA patients without symptomatic ACJ OA. This may be due to the effect of ACJ ankylosis leading to reduced scapulothoracic motion and, indirectly, glenohumeral joint motion [4]. The effect of ACJ OA on glenohumeral motion may only reach significance in glenohumeral joint OA, where there may be greater compensatory motion across the ACJ. RTSA-DCE patients achieved an average increase of 59.5° in shoulder flexion by latest follow-up compared to an average increase of 40.7° among the RTSA group. This inter-group difference in flexion ROM improvement (18.8°) represents a clinically significant difference based on the prior reported minimum clinically important difference of 12° for shoulder flexion after total shoulder arthroplasty [19].

These findings were further reinforced by the multivariate analysis, which found concomitant DCE to be a significant predictor of greater improvements in both flexion and IR ROM even when controlling for differences in demographic and clinical characteristics. The results of the present study suggest that DCE provide additive benefits in terms of improved shoulder ROM when performed for the treatment symptomatic ACJ OA in the setting of RTSA. While there is a subset of patients who may have ACJ pain without significant arthritis, no recommendations can be made regarding whether DCE has the potential to help isolated ACJ pain without arthritis.

### Clinical Considerations

Based on the results of the present study, it is unclear whether concomitant DCE is specifically indicated in patients with symptomatic ACJ OA undergoing RTSA in order to reduce the risk of postoperative ASF. Nonetheless, the results of the present study suggest that RTSA with concomitant DCE alleviates shoulder pain and improves shoulder ROM among patients with symptomatic ACJ OA comorbid with other shoulder pathologies (cuff tear arthropathy, massive irreparable rotator cuff tear, primary glenohumeral OA), and may be indicated for these purposes. It is

important to note that only symptomatic ACJ OA was treated with DCE in this study. Routine DCE is not recommended for asymptomatic radiographic ACJ OA given that prior randomized controlled trials have found no significant difference in postoperative pain or ROM between patients who underwent RCR with versus without DCE for the treatment of rotator cuff tears with radiographic ACJ OA [18,20].

### Limitations

The present study has several limitations. First, this study was retrospective in nature and had short-term follow-up with minimum and mean follow-ups of 6 and 19 months, respectively. Second, the study was conducted as a single surgeon series with a single implant type in a single patient population in the United States, which improves the comparability of the RTSA-DCE and RTSA groups within this study but decreases its generalizability to other RTSA populations. This is particularly important to consider when applying the results of the present study to non-U. S. populations in which BMI is lower and/or osteoporosis is more prevalent. Third, as mentioned previously, there was no control group of patients with symptomatic ACJ OA who were treated with RTSA without concomitant DCE. Since there may have been other clinical differences between patients with and without symptomatic ACJ OA undergoing RTSA, it cannot be definitively concluded that the addition of DCE improves pain and shoulder ROM independent of the RTSA procedure itself. Fourth, preoperative glenoid retroversion was not measured and reported since many patients did not have CT and/or MRI scans that were accessible from the study institution's electronic medical record system. Fifth, preoperative bone densitometry scores could not be obtained for the majority of patients in either cohort, and the present study cannot account for the effect of baseline bone density on ASF risk.

## CONCLUSIONS

Concomitant DCE in RTSA improves shoulder flexion and IR AROM, alleviates shoulder pain, and does not increase the risk of acromial stress fractures.

## NOTES

### ORCID

Ajay C. Kanakamedala https://orcid.org/0000-0001-6991-4327
Dhruv S. Shankar https://orcid.org/0000-0002-4153-9382
Neil Gambhir https://orcid.org/0000-0002-1571-0780
Michael Boin https://orcid.org/0000-0001-6708-6388
Matthew G. Alben https://orcid.org/0000-0001-7398-4088
Mandeep S. Virk https://orcid.org/0000-0001-6294-2771
Young W. Kwon https://orcid.org/0000-0001-6048-2548

### Author contributions

Conceptualization: ACK, MSV, YWK. Data curation: DSS, NG, MGA. Formal Analysis: ACK, DSS, YWK. Investigation: ACK, DSS, NG, MRB, MB, MGA, YWK. Methodology: ACK, MSV, YWK. Project administration: MSV. Software: DSS. Supervision: ACK, MB, YWK. Visualization: DSS. Writing – original draft: ACK, DSS, NG, MRB, MB, YWK. Writing – review & editing: ACK, DSS, MB, MGA, MSV, YWK.

### Conflict of interest

None.

### Funding

None.

### Data availability

Contact the corresponding author for data availability.

### Acknowledgments

None.

## REFERENCES

1. Schairer WW, Nwachukwu BU, Lyman S, Craig EV, Gulotta LV. National utilization of reverse total shoulder arthroplasty in the United States. J Shoulder Elbow Surg 2015;24:91–7.
2. Brown JN, Roberts SN, Hayes MG, Sales AD. Shoulder pathology associated with symptomatic acromioclavicular joint degeneration. J Shoulder Elbow Surg 2000;9:173–6.
3. Townsend CB, Wright J, Wright TW, et al. Severe acromioclavicular joint osteoarthritis is associated with acromial stress fractures after reverse shoulder arthroplasty. JSES Int 2021;6:236–40.
4. Sousa Cde O, Michener LA, Ribeiro IL, Reiff RB, Camargo PR, Salvini TF. Motion of the shoulder complex in individuals with isolated acromioclavicular osteoarthritis and associated with rotator cuff dysfunction: part 2 – muscle activity. J Electromyogr Kinesiol 2015;25:77–83.
5. Moverman MA, Menendez ME, Mahendraraj KA, Polisetty T, Jawa A, Levy JC. Patient risk factors for acromial stress fractures after reverse shoulder arthroplasty: a multicenter study. J Shoulder Elbow Surg 2021;30:1619–25.
6. Zmistowski B, Gutman M, Horvath Y, Abboud JA, Williams

GR Jr, Namdari S. Acromial stress fracture following reverse total shoulder arthroplasty: incidence and predictors. J Shoulder Elbow Surg 2020;29:799–806.
7. ASES Complications of RSA Research Group; Mahendraraj KA, Abboud J, et al. Predictors of acromial and scapular stress fracture after reverse shoulder arthroplasty: a study by the ASES Complications of RSA Multicenter Research Group. J Shoulder Elbow Surg 2021;30:2296–305.
8. Gokkus K, Saylik M, Atmaca H, Sagtas E, Aydin AT. Limited distal clavicle excision of acromioclavicular joint osteoarthritis. Orthop Traumatol Surg Res 2016;102:311–8.
9. Taylor SA, Shah SS, Chen X, et al. Scapular ring preservation: coracoacromial ligament transection increases scapular spine strains following reverse total shoulder arthroplasty. J Bone Joint Surg Am 2020;102:1358–64.
10. Baek Md CH, Kim Md JG, Lee Md DH, Baek GR. Does preservation of coracoacromial ligament reduce the acromial stress pathology following reverse total shoulder arthroplasty. J Shoulder Elb Arthroplast 2021;5:24715492211022171.
11. Werthel JD, Schoch BS, van Veen SC, et al. Acromial fractures in reverse shoulder arthroplasty: a clinical and radiographic analysis. J Shoulder Elb Arthroplast 2018;2:2471549218777628.
12. Hamada K, Fukuda H, Mikasa M, Kobayashi Y. Roentgenographic findings in massive rotator cuff tears: a long-term observation. Clin Orthop Relat Res 1990;(254):92–6.
13. Kellgren JH, Lawrence JS. Radiological assessment of osteo-arthrosis. Ann Rheum Dis 1957;16:494–502.
14. Flurin PH, Marczuk Y, Janout M, Wright TW, Zuckerman J, Roche CP. Comparison of outcomes using anatomic and reverse total shoulder arthroplasty. Bull Hosp Jt Dis (2013) 2013;71 Suppl 2:101–7.
15. Mollon B, Mahure SA, Roche CP, Zuckerman JD. Impact of glenosphere size on clinical outcomes after reverse total shoulder arthroplasty: an analysis of 297 shoulders. J Shoulder Elbow Surg 2016;25:763–71.
16. Forlenza EM, Wright-Chisem J, Cohn MR, et al. Arthroscopic distal clavicle excision is associated with fewer postoperative complications than open. JSES Int 2021;5:856–62.
17. Cirigliano G, Kriechling P, Wieser K, Camenzind RS. Reversed total shoulder arthroplasty after acromioclavicular joint resection yields equivalent clinical results compared to a matched control group. Eur J Orthop Surg Traumatol 2023;33:3547–53.
18. Wang J, Ma JX, Zhu SW, Jia HB, Ma XL. Does distal clavicle resection decrease pain or improve shoulder function in patients with acromioclavicular joint arthritis and rotator cuff tears?: a meta-analysis. Clin Orthop Relat Res 2018;476:2402–14.
19. Simovitch R, Flurin PH, Wright T, Zuckerman JD, Roche CP. Quantifying success after total shoulder arthroplasty: the minimal clinically important difference. J Shoulder Elbow Surg 2018;27:298–305.
20. Livingstone A, Asaid R, Moaveni AK. Is routine distal clavicle resection necessary in rotator cuff repair surgery?: a systematic review and meta-analysis. Shoulder Elbow 2019;11(1 Suppl):39–45.

Original Article

Clin Shoulder Elbow 2023;26(4):366-372
https://doi.org/10.5397/cise.2023.00458

CiSE
Clinics in Shoulder and Elbow

eISSN 2288-8721

# Classification system for partial distal biceps tendon tears: a descriptive 3-Tesla magnetic resonance imaging study of tear morphology

**Alex B Boyle, Simon BM MacLean**

*Department of Orthopaedic Surgery, Tauranga Hospital, Tauranga, New Zealand*

**Background:** There is minimal literature on the morphology of partial distal biceps tendon (DBT) tears. We sought to investigate tear morphology by retrospectively reviewing 3-Tesla magnetic resonance imaging (3T MRI) scans of elbows with partial DBT tears and to propose a basic classification system.
**Methods:** 3T MRI scans of elbows with partial DBT tears were retrospectively reviewed by two experienced observers. Basic demographic data were collected. Tear morphology was recorded including type, presence of retraction (>5 mm), and presence of discrete long-head and short-head tendons at the DBT insertion.
**Results:** For analysis, 44 3T MRI scans of 44 elbows with partial DBT tears were included. There were 9 isolated long-head tears (20%), 13 isolated short-head tears (30%), 2 complete long-head tears with a partial short-head tear (5%), 5 complete short-head tears with a partial long-head tear (11%), and 15 peel-off tears (34%). Retraction was seen in 5 or 44 partial tears (11%), and 13 of the 44 DBTs were bifid tendons at the insertion (30%).
**Conclusions:** Partial DBT tears can be classified into five sub-types: long-head isolated tears, short-head isolated tears, complete long-head tears with partial short-head involvement, complete short-head tears with partial long-head involvement, and peel-off tears. Classification of tears may have implications for operative and non-operative management.
**Level of evidence:** III.

**Keywords:** Orthopedic surgery; Classification; Upper limb; Diagnostic imaging; Distal biceps tendon

## INTRODUCTION

Partial distal biceps tendon (DBT) tears are a unique clinical entity. Patients often present sub-acutely, and signs and symptoms may be subtle or non-specific [1,2]. Recent study has identified morphological differences between elbows with partial DBT tears compared to non-diseased controls, including a higher frequency of bifid tendons and a narrower radio-ulnar space [3].

In complete DBT tears, operative fixation is generally recommended. Anatomic repairs have become standard and can be achieved using intraosseous Endobuttons, transosseous reinsertion suture anchors, interference screws, or transosseous sutures [4-6]. Conversely, in partial DBT tears, optimal management remains contentious. There is a paucity of literature on the characteristics of different tears and on repair techniques for partial tears, and it is unclear whether partial tear disruption affects more or less than 50% of the DBT insertion [7-9].

A short head and a long head make up the biceps musculoten-

Received: June 8, 2023 Revised: July 10, 2023 Accepted: July 16, 2023
Correspondence to: Alex B Boyle
Department of Orthopaedic Surgery, Tauranga Hospital, 829 Cameron Rd, Private bag 12024, Tauranga 3143, New Zealand
Tel: +64-7-579-8000, Fax: +64-7-571-3179, E-mail: alex.boyle@bopdhb.govt.nz, ORCID: https://orcid.org/0000-0001-6849-2871

Copyright© 2023 Korean Shoulder and Elbow Society.
This is an Open Access article distributed under the terms of the Creative Commons Attribution Non-Commercial License (http://creativecommons.org/licenses/by-nc/4.0/) which permits unrestricted non-commercial use, distribution, and reproduction in any medium, provided the original work is properly cited.

dinous unit. The long head arises from the superior aspect of the glenoid and the short head from the coracoid process. These two muscle bellies remain separate, and most tendons are discrete entities at the musculotendinous junction [10-13]. Multiple studies have investigated the anatomy of the DBT as it inserts onto the radial tuberosity [10,12-15]. With increased understanding of the insertional anatomy of the DBT, we have begun to appreciate the separate roles of the long head and short head [13,16,17].

Recent studies have identified DBT anatomy using high-resolution 3-tesla magnetic resonance imaging (3T MRI) [3,11]. 3T MRI imaging has a higher signal-to-noise ratio than 1.5-T images, which allows better anatomic resolution [18] making it well suited for characterizing precise *in vivo* anatomy. Given the paucity of data on different types of partial DBT tears, the purpose of this study was to define the pathoanatomy of the partially torn DBT using 3T MRI and to develop a classification system for this heterogeneous group.

## METHODS

Institutional review board approval was received for this study from the Health and Disability Ethics Committee, New Zealand (Ref. 21/CEN/187). Informed consent was waived due to retrospective nature of this study.

All MRI scans performed over a 2-year period at our institution on elbows for any indication were screened, and all partial tears were noted for closer review. A total of 44 dedicated 3T MRI scans of elbows with partial DBT tears from our institution's Picture Archiving and Communication System imaging system retrospectively was reviewed. These were obtained from patients undergoing treatment for partial DBT tears for elbow pain persisting at least 6 weeks post injury. Exclusion criteria included skeletally immature patients, motion artefact/poor quality scans, and incomplete/inappropriate scans. All scans were performed using the Siemens Vida 3T with slice thickness set to 3 mm. All scans were performed using the institution's standard protocol with the elbow extended and the upper limb next to the trunk to allow true axial and sagittal slices. Sequences reviewed were either sagittal PD TSE (FOV 140×140) and axial PDFS TSE (FOV 100×100) (Figs. 1-4) or sagittal PDFS TSE (FOV 140×140) and axial PDFS (FOV 100×100) (Fig. 5). Basic demographic data including age, sex, and side (right or left) were collected. Mechanism of tear was also noted from the patient's electronic record.

### Measurements

Each scan was reviewed independently by two trained observers:

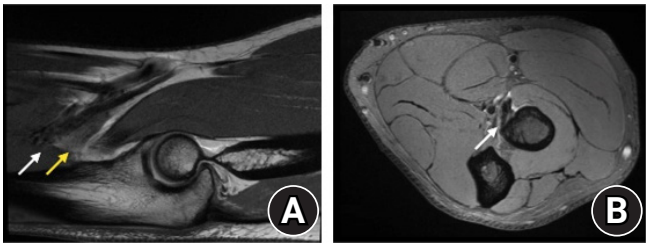


**Fig. 1.** Example of long-head only tear. (A) Sagittal plane. (B) Axial plane. White arrows denote intact tendon and the yellow arrow denotes torn tendon.

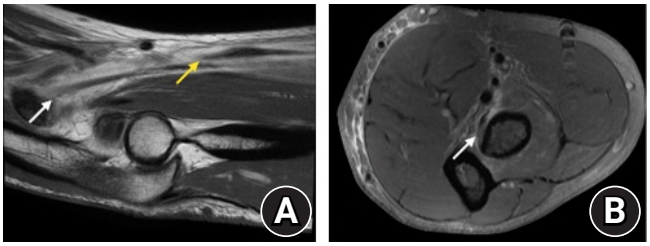


**Fig. 2.** Example of short-head only tear (with marked tendon retraction). (A) Sagittal plane. (B) Axial plane. White arrows denote intact tendon and the yellow arrow denotes torn tendon.

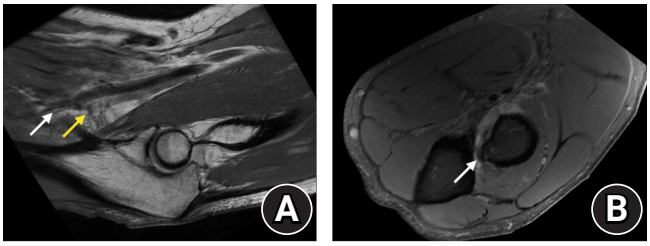


**Fig. 3.** Example of complete long head with partial short-head tear. (A) On sagittal image. The white arrow denotes intact tendon and yellow arrow denotes torn tendon. (B) On the axial image the white arrow denotes the tear.

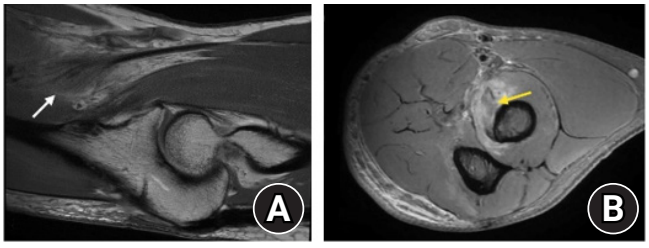


**Fig. 4.** Example of peel-off tear. (A) Sagittal plane. (B) Axial plane. The intact medial fibres are identified on the sagittal sequences with the white arrow denoting intact tendon. The torn lateral fibres are identified on the axial sequences with the yellow arrow denoting torn tendon.

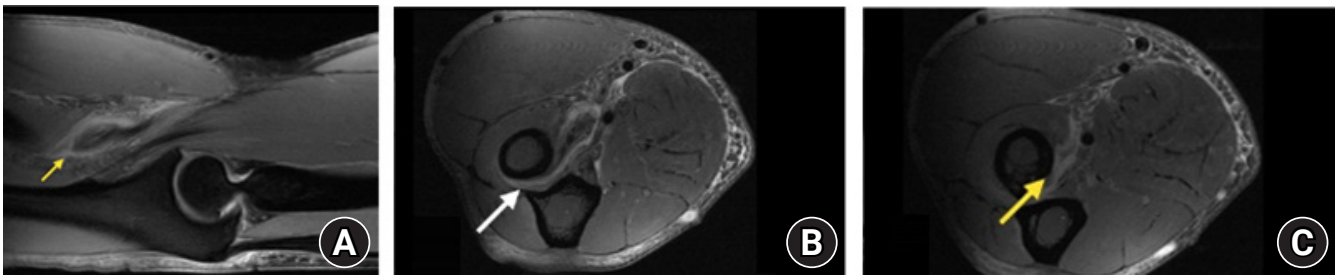


**Fig. 5.** Example of complete short head with partial long head tear. (A) The tear on the sagittal view is best depicted on the sagittal proton density fat sat. (B) Proximal aspect of the radial tuberosity showing intact fibres. (C) Distal aspect of the tuberosity showing no inserting fibres. White arrow denotes intact tendon and yellow arrows denote torn tendon.

a fellowship-trained upper limb surgeon (SBMM) and an orthopaedic surgeon (ABB) in training. Each scan was reviewed for the presence or absence of retraction of the torn part of the tendon and the presence of discrete long-head and short-head tendons at the DBT insertion (a "bifid" tendon), and tear morphology was noted to document the percentage of insertion involved and the anatomic position of the tear.

### Retraction

The presence or absence of retraction of the torn part of the tendon, defined as visible retraction >5 mm, was noted for each patient. This was reviewed by analysing the sagittal images using the axial plane for clarity and by measuring from the radial tuberosity to visible torn tendon edge.

### Bifid Tendons

The presence of discrete long-head and short-head tendons at the DBT insertion (a bifid tendon) was also noted. Images were reviewed at the musculotendinous junction in both the sagittal and axial planes to see if two discrete tendons or a single tendon was visible. In cases where two discrete tendons were visible at the musculotendinous junction, images were traced along the axial plane to see if the tendons interdigitated at some point or whether they continued to their insertion/the tear as two discrete tendons (a bifid tendon).

### Enthesophytes

Enthesophytes were defined as bony proliferations oriented along the line of the tendon fibres at the insertion point of the DBT at the radial tuberosity. The axial and coronal planes were used to assess the presence of enthesophytes as determined by independent observers.

### Tear Morphology

Each scan was carefully reviewed by the two observers (ABB and SBMM) in both the axial and sagittal planes. Once the tear was identified, tear morphology was recorded by measuring the approximate percentage of the footprint involved (i.e., tear length divided by total insertion length) as well as the part of the insertion that was torn (i.e., distal, proximal, radial, ulnar, or a combination). The written descriptions of tear morphology were retrospectively reviewed by the two observers to identify recurring tear types.

## RESULTS

The mean age of the 44 participants was 52 years (range, 34–72 years). There were 36 males and 8 females. All patients described a traumatic mechanism: 37 with eccentric loading/lifting/wrenching injuries, 6 with traumatic hyperextension injuries, and 1 with concentric loading with supination.

### Retraction

Retraction was seen in 5 of 44 partial tears (11%). Of these 5 tears with retraction, 1 was a long-head only tear and the other 4 were short-head only tears.

### Bifid Tendons

At their insertion onto the radial tuberosity, 13 of the 44 DBTs were bifid tendons (30%).

### Enthesophytes

Enthesophytes were seen in 18 of the 44 elbows (41%).

### Tear Morphology

All tears fit into one of five categories. The relative frequencies and descriptions of each tear type are outlined in Table 1. The descriptive data on tear morphology were consistent between observers for all scans.

Group 1 consisted of single tendons in which only the most


https://doi.org/10.5397/cise.2023.00458

**Table 1.** Types of partial distal biceps tendon tears

| Objective MRI finding | Number and associated finding | | | | Interpretation | Proposed tear type |
|---|---|---|---|---|---|---|
| | Total | Retraction | Bifid | Enthesophyte | | |
| If single tendon, most proximal up to 50% of insertion involved only. If bifid tendon, isolated tear of proximal head visible with no involvement of distal head. | 9 (20) | 1 (11) | 3 (33) | 4 (44) | Isolated long-head tear with no short-head tear | Long-head only tear (Fig. 1) |
| If single tendon, most distal up to 50% of insertion involved only. If bifid tendon, isolated tear of distal head visible with no involvement of proximal head. | 13 (30) | 4 (31) | 7 (54) | 4 (31) | Isolated short-head tear with no long-head tear | Short-head only tear (Fig. 2) |
| If single tendon, most proximal up to 50% of insertion involved plus further extension into distal insertion. If bifid tendon, complete tear of proximal head visible as well as partial tear of distal head. | 2 (5) | 0 | 0 | 2 (100) | Complete tear of the long head DBT with partial tear of short head | Complete long head+partial short-head tear (Fig. 3) |
| If single tendon, most distal up to 50% of insertion involved plus further extension into proximal insertion. If bifid tendon, complete tear of distal head visible as well as partial tear of proximal head. | 5 (11) | 0 | 1 (20) | 0 | Complete tear of the short-head DBT with partial tear of long head | Complete short-head + partial long-head tear (Fig. 5) |
| Oedema and partial lift-off seen at insertion at any point but no clear involvement of entire proximal or distal insertion. | 15 (34) | 0 | 2 (13) | 8 (53) | Tear with partial lift-off of part of the insertion with no overt tear | Peel-off tear (Fig. 4) |

Values are presented as number (%).
MRI: magnetic resonance imaging, DBT: distal biceps tendon.

proximal up to 50% of the insertion was involved or bifid tendons in which there was an isolated tear of the proximal head with no tear/involvement of the distal head. These were considered long-head only tears (Fig. 1).

Group 2 consisted of single tendons in which only the most distal up to 50% of the insertion was involved or bifid tendons in which there was an isolated tear of the distal head with no tear/involvement of the proximal head. These were considered short-head only tears (Fig. 2).

Group 3 consisted of single tendons in which the most proximal up to 50% of the insertion was involved as well as further extension of the tear into the distal insertion or bifid tendons in which there was a complete tear of the proximal head with a partial tear/some involvement of the distal head. These were considered complete long head with partial short-head tears (Fig. 3).

Group 4 consisted of single tendons in which the most distal up to 50% of the insertion was involved as well as further extension of the tear into the proximal insertion or bifid tendons in which there was a complete tear of the distal head with a partial tear/some involvement of the proximal head. These were considered complete short head with partial long-head tears (Fig. 5).

Group 5 consisted of tendons in which there was oedema and partial lift-off at the insertion at any point but no clear involvement of the entire proximal or distal insertion. These were considered peel-off tears (Fig. 4).

## DISCUSSION

Our results reveal five main types of DBT partial tears identified on 3T MRI scan: long head isolated tears, short-head isolated tears, complete long-head tears with partial short -head involvement, complete short-head tears with partial long-head involvement, and peel-off tears. Understanding these tear types requires good understanding of the anatomy of the DBT.

The biceps musculotendinous unit consists of the long head and the short head. The long-head arises from the supraglenoid tubercle and the short head from the coracoid process. The two corresponding muscle bellies remain separate, and most DBTs have discrete long-head and short-head tendons at the musculotendinous junction [10-13]. The long-head and short-head parts of the DBT may remain discrete or interdigitate to varying degrees as the DBT runs to its insertion on the radial tuberosity [10-13] during which time it rotates and the orientation of the two heads changes. The short head becomes superficial and the long head becomes deeper and sits slightly more laterally [10,19,20]. The DBT then inserts onto the radial tuberosity. The

long head part of the DBT inserts more proximally on the radial tuberosity, while the short-head part inserts further distally [10,12,13,20]. Several cadaveric studies have supported these unique insertions of the two heads of the DBT onto the radial tuberosity [10,12,13,20]. However, a study by Bhatia et al. [14] did note large variations in footprint insertions.

The pathogenesis of partial DBT tears is relevant to understanding their differing morphologies. A large radial tuberosity or a narrow radio-ulnar space may impinge on the DBT, leading to chronic change and attritional rupture with time. This theory is supported by the finding that the space through which the DBT runs between the lateral ulna and radial tuberosity may decrease as much as 50% from supination to pronation even in non-diseased elbows [21-23]. In a comparative control MRI study of 26 normal elbows and 26 partial tears, significantly larger measurements for radial tuberosity length, radial tuberosity thickness, and ratio of radial tuberosity thickness to radial diameter were found, as well as a statistically significant smaller radio-ulnar space [3]. A significant association also was found between partial tears and enthesophytes, likely for the same reason [3]. In the same study, two discrete tendons was significantly more common in the partial tear group [3]. In the present study, 13 of the 44 DBTs were bifid tendons at their insertion onto the radial tuberosity (31%). It is possible that a discrete tendon predisposes one to particular partial tears. More research is needed in this regard.

There is conflicting evidence on the frequency of complete discrete short-head and long-head DBTs (as opposed to a single DBT tendon or, more commonly, two discrete tendons that interdigitate prior to insertion). Three cadaveric studies, all including 15 to 25 cadavers, have shown differing results. Cho et al. [12] found that 48% of DBTs consisted of two distinct and easily separated parts, while 52% interdigitated completely into a single distal tendon. Eames et al. [13] found that 59% of DBTs consisted of two distinct tendons, while 41% interdigitated prior to insertion. Athwal et al. [10] found that 13% of DBTs consisted of two separate tendons, 54% were attached but easily separable, and 33% were inseparably interdigitated. An MRI study of 106 DBTs found that 82% of tendons interdigitated prior to insertion onto the radial tuberosity, while 8% remained as two visibly discrete tendons for their entire length, remaining as two discrete insertions at their origin at the musculotendinous junction and remaining separate until their two adjacent but separate insertions at the radial tuberosity [11]. The independence of the two tendons has implications for classification and management.

The surgical management of complete DBT tears has been reported in the literature. For partial DBT tears the evidence is less clear; to our knowledge there is no literature to suggest which surgical intervention is most appropriate for any particular partial tear. Surgical intervention clearly has its place, although Bauer et al. [24] demonstrated that high-need patients with partial DBT tears reported better recovery post-surgery than with conservative management, and that 55.7% of partial DBT patients initially managed conservatively eventually underwent surgery. Previous studies characterizing partial DBT tears using MRI have divided partial tears into high-grade partial tears requiring surgical intervention (tendonous disruption affecting more than 50% of the DBT insertion) and low-grade partial tears not requiring surgical intervention (tendonous disruption affecting less than or equal to 50% of the DBT insertion) [7-9]. The utility of this number (50%) as a guide for surgical management is unclear, although a significant decrease of supination strength has been reported when the tear involves more than 75% of the footprint [25]. Operatively managed partial tears are often treated by surgically transecting the remaining intact DBT and performing a complete anatomic repair using the methods outlined above [26,27]. This has similar outcomes to the treatment of complete DBT ruptures [1] but may lead to overly aggressive treatment of some tears. Endoscopic techniques allow intra-operative assessment of tears that may not require full complete release and reinsertion [2].

The anatomy of the insertion may have biomechanical implications relevant to surgical management. If the long head of the DBT inserts more proximally and the short head more distally, [10-13] this may position the short-head DBT to be a more powerful flexor and the long head DBT as a more powerful supinator, as has been reported in previous biomechanical studies [13,16,17]. The proposed mechanism for this involves the moment arm of each head. When the arm is in a neutral or pronated position the moment arm for the short head (the length between the elbow joint axis and the line of force acting on the joint) is larger given its more distal insertion. This makes it a more powerful flexor. Likewise, the more proximal long head insertion is further from the axis of rotation of the forearm, making it a more powerful supinator [13,16,17].

Given the reliance on biceps brachii for supination, perhaps we should be more proactive in fixing long-head only tears. If the long head is the primary supinator, isolated long head ruptures may be best managed with detachment and surgical repair of the single head. Conversely, if the short head is the primary flexor, isolated short-head tears may be appropriate to scope/debride in low demand patients and only proceed to detachment and repair in high demand patients, given that brachialis functions well as a flexor.


https://doi.org/10.5397/cise.2023.00458

By this logic, complete detachment and anatomic repair might be appropriate in complete long head tears with partial short-head involvement and complete short-head tears with partial long head involvement. The peel-off lesions noted in this study bear a significant resemblance to partial articular supraspinatus tendon avulsion (PASTA) lesions. These might be best managed in a similar fashion to an arthroscopic PASTA repair by endoscopically reviewing the tendinous insertion, maintaining any healthy fibers on the footprint, and repairing those that are peeling off.

These proposed management plans are simply hypotheses regarding the different tear types noted in this study. The management outlined above relies heavily on the biomechanical studies that state the short-head DBT is positioned to be a more powerful flexor, and the long head DBT to be a more powerful supinator [13,16,17]. A biomechanical study by Tomizuka et al. [25] contradicted these findings; however, showing that a simulated short-head avulsion significantly decreased the supination strength. Clearly, further biomechanical studies are required to determine the contribution of each component of the DBT to specific biceps function, and our MRI based classification needs to be verified by surgical or cadaveric studies.

This study had several limitations. First, this was an MRI study with no surgical correlation. Although MRI is the radiological gold standard for characterizing DBT injuries, it has been reported that there is not always correlation with surgical findings in partial DBT tears, albeit using 1.5T MRI, rather than 3T MRI [20]. MRI is also expensive and not necessarily readily available for all patients, and this may reduce the generalizability of the findings. Ultrasound has, in one case, shown the potential to differentiate between isolated lesions of the short head or long head [20]. Second, although it is possible to trace the short-head and long-head components of the DBT from musculotendinous junction downwards, in injured tendons the anatomy can be distorted. Our interpretation of each tear (and therefore our classification system) relies in part on the known anatomy of the DBT tendon (which may be unknowingly erroneous) rather than direct visualisation. Third, the sample size in the current study was small, meaning our descriptive study and classification system may not capture the full diversity of partial DBT tears and does not provide a solid basis for epidemiological insight. Nevertheless, this is foundational knowledge on which to build upon and represents the first proposal for a partial DBT tear classification system which may have implications for management looking forward. Future research should consider larger sample sizes, explore correlations with surgical findings, compare the effectiveness of more accessible imaging modalities, and identify the clinical implications of different tear types. Further prospective studies are required to assess an algorithm for treatment of these partial DBT tears.

## CONCLUSIONS

Using 3T MRI scans have investigated the tear morphology of partial DBT tears and have proposed a classification system for these injuries. This descriptive study and classification system will allow further investigation into partial DBT tears and will promote further investigation into the management of these heterogeneous injuries.

## NOTES

**ORCID**

Alex B Boyle https://orcid.org/0000-0001-6849-2871

**Author contributions**

Conceptualization: ABB, SBMM. Data curation: ABB. Formal Analysis: ABB, SBMM. Investigation: ABB. Methodology: ABB, SBMM. Supervision: SBMM. Writing – original draft: ABB. Writing – review & editing: ABB, SBMM.

**Conflict of interest**

None.

**Funding**

None.

**Data availability**

Contact the corresponding author for data availability.

**Acknowledgments**

None.

## REFERENCES

1. Bain GI, Johnson LJ, Turner PC. Treatment of partial distal biceps tendon tears. Sports Med Arthrosc Rev 2008;16:154–61.
2. Caekebeke P, Duerinckx J, van Riet R. Acute complete and partial distal biceps tendon ruptures: what have we learned? A review. EFORT Open Rev 2021;6:956–65.
3. Boyle AB, George CM, MacLean SB. Anatomic factors associated with partial distal biceps tendon tears: a comparative control study. J Shoulder Elbow Surg 2022;31:1224–30.
4. Alemann G, Dietsch E, Gallinet D, Obert L, Kastler B, Aubry S.

Repair of distal biceps brachii tendon assessed with 3-T magnetic resonance imaging and correlation with functional outcome. Skeletal Radiol 2015;44:629–39.
5. Miyamoto RG, Elser F, Millett PJ. Distal biceps tendon injuries. J Bone Joint Surg Am 2010;92:2128–38.
6. Sutton KM, Dodds SD, Ahmad CS, Sethi PM. Surgical treatment of distal biceps rupture. J Am Acad Orthop Surg 2010; 18:139–48.
7. de la Fuente J, Blasi M, Martínez S, et al. Ultrasound classification of traumatic distal biceps brachii tendon injuries. Skeletal Radiol 2018;47:519–32.
8. Festa A, Mulieri PJ, Newman JS, Spitz DJ, Leslie BM. Effectiveness of magnetic resonance imaging in detecting partial and complete distal biceps tendon rupture. J Hand Surg Am 2010; 35:77–83.
9. Le Huec JC, Moinard M, Liquois F, Zipoli B, Chauveaux D, Le Rebeller A. Distal rupture of the tendon of biceps brachii. Evaluation by MRI and the results of repair. J Bone Joint Surg Br 1996;78:767–70.
10. Athwal GS, Steinmann SP, Rispoli DM. The distal biceps tendon: footprint and relevant clinical anatomy. J Hand Surg Am 2007;32:1225–9.
11. Boyle AB, Uri Ke J, Ragg A, MacLean SB. Anatomy of the distal biceps tendon: an in vivo 3-T magnetic resonance imaging study. J Shoulder Elbow Surg 2022;31:1316–22.
12. Cho CH, Song KS, Choi IJ, et al. Insertional anatomy and clinical relevance of the distal biceps tendon. Knee Surg Sports Traumatol Arthrosc 2011;19:1930–5.
13. Eames MH, Bain GI, Fogg QA, van Riet RP. Distal biceps tendon anatomy: a cadaveric study. J Bone Joint Surg Am 2007;89: 1044–9.
14. Bhatia DN, Kandhari V, DasGupta B. Cadaveric study of insertional anatomy of distal biceps tendon and its relationship to the dynamic proximal radioulnar space. J Hand Surg Am 2017; 42:e15–23.
15. Mazzocca AD, Cohen M, Berkson E, et al. The anatomy of the bicipital tuberosity and distal biceps tendon. J Shoulder Elbow Surg 2007;16:122–7.
16. Jarrett CD, Weir DM, Stuffmann ES, Jain S, Miller MC, Schmidt CC. Anatomic and biomechanical analysis of the short and long head components of the distal biceps tendon. J Shoulder Elbow Surg 2012;21:942–8.
17. Morrey BF, Askew LJ, An KN, Dobyns JH. Rupture of the distal tendon of the biceps brachii: a biomechanical study. J Bone Joint Surg Am 1985;67:418–21.
18. Mosher TJ. Musculoskeletal imaging at 3T: current techniques and future applications. Magn Reson Imaging Clin N Am 2006; 14:63–76.
19. Kulshreshtha R, Singh R, Sinha J, Hall S. Anatomy of the distal biceps brachii tendon and its clinical relevance. Clin Orthop Relat Res 2007;456:117–20.
20. Tagliafico A, Michaud J, Capaccio E, Derchi LE, Martinoli C. Ultrasound demonstration of distal biceps tendon bifurcation: normal and abnormal findings. Eur Radiol 2010;20:202–8.
21. Davis WM, Yassine Z. An etiological factor in tear of the distal tendon of the biceps brachii: report of two cases. J Bone Joint Surg Am 1956;38:1365–8.
22. Rausch V, Krieter JP, Leschinger T, et al. The radioulnar distance at the level of the radial tuberosity. Clin Anat 2020;33:661–6.
23. Schmidt CC, Brown BT, Williams BG, et al. The importance of preserving the radial tuberosity during distal biceps repair. J Bone Joint Surg Am 2015;97:2014–23.
24. Bauer TM, Wong JC, Lazarus MD. Is nonoperative management of partial distal biceps tears really successful. J Shoulder Elbow Surg 2018;27:720–5.
25. Tomizuka Y, Schmidt CC, Davidson AJ, et al. Partial distal biceps avulsion results in a significant loss of supination force. J Bone Joint Surg Am 2021;103:812–9.
26. Bourne MH, Morrey BF. Partial rupture of the distal biceps tendon. Clin Orthop Relat Res 1991;143–8.
27. Nielsen K. Partial rupture of the distal biceps brachii tendon: a case report. Acta Orthop Scand 1987;58:287–8.


https://doi.org/10.5397/cise.2023.00458

Original Article

Clin Shoulder Elbow 2023;26(4):373-379
https://doi.org/10.5397/cise.2023.00738

CiSE
Clinics in Shoulder and Elbow

eISSN 2288-8721

# Effect of cigarette smoking on the maintenance of reduction after treatment of acute acromioclavicular joint dislocation with hook plate fixation

**Jee-Hoon Choi[1], Yong-Min Chun[2], Tae-Hwan Yoon[1,2]**

[1]*Department of Orthopedic Surgery, Arthroscopy and Joint Research Institute, Gangnam Severance Hospital, Yonsei University College of Medicine, Seoul, Korea*
[2]*Department of Orthopedic Surgery, Arthroscopy and Joint Research Institute, Severance Hospital, Yonsei University College of Medicine, Seoul, Korea*

**Background:** The purpose of this study was to determine the association between smoking and clinical outcomes of hook plate fixation for acute acromioclavicular (AC) joint injuries.
**Methods:** This study retrospectively investigated 82 patients who underwent hook plate fixation for acute AC joint dislocation between March 2014 to June 2022. The patients were grouped by smoking status, with 49 in group N (nonsmokers) and 33 in group S (smokers). Functional scores and active range of motion were compared among the groups at the 1-year follow-up. Coracoclavicular distance (CCD) was measured, and difference with the uninjured side was compared at initial injury and 6 months after implant removal.
**Results:** No significant differences were observed between the two groups in demographic factors such as age and sex, as well as parameters related to initial injury status, which included time from injury to surgery, the preoperative CCD difference value, and the Rockwood classification. However, the postoperative CCD difference was significantly higher in group S (3.1±2.6 mm) compared to group N (1.7±2.4 mm). Multivariate regression analysis indicated that smoking and the preoperative CCD difference independently contributed to an increase in the postoperative CCD difference. Despite the radiographic differences, the postoperative clinical outcome scores and active range of motion measurements were comparable between the groups.
**Conclusions:** Smoking had a detrimental impact on ligament healing after hook plate fixation for acute AC joint dislocations. This finding emphasizes the importance of smoking cessation to optimize reduction maintenance after AC joint injury.
**Level of evidence:** III.

**Keywords:** Smoking; Acromioclavicular joint injury; Hook plate fixation; Coracoclavicular joint distance

## INTRODUCTION

Due to the increasing popularity of recreational activities and sports, the prevalence of acromioclavicular (AC) joint injuries is on the rise [1]. Neglected injuries can lead to chronic pain, instability, and decline in shoulder function [2,3]. Various surgical approaches including the use of Kirschner wire, hook plate, and cortical button have been employed to stabilize the AC joint [4-7]. Among them, the clavicular hook plate is anatomically contoured to fit the clavicle and features a tapered hook designed to

Received: August 17, 2023 Revised: September 8, 2023 Accepted: September 12, 2023
Correspondence to: Tae-Hwan Yoon
Department of Orthopedic Surgery, Arthroscopy and Joint Research Institute, Gangnam Severance Hospital, Yonsei University College of Medicine, 211 Eonju-ro, Gangnam-gu, Seoul 06273, Korea
Tel: +82-2-2019-3414, E-mail: uvsoul1106@gmail.com, ORCID: https://orcid.org/0000-0002-2859-5240

Copyright© 2023 Korean Shoulder and Elbow Society.
This is an Open Access article distributed under the terms of the Creative Commons Attribution Non-Commercial License (http://creativecommons.org/licenses/by-nc/4.0/) which permits unrestricted non-commercial use, distribution, and reproduction in any medium, provided the original work is properly cited.

function as a lever beneath the acromion [8]. This lever action depresses the clavicle, promoting healing of the AC and coracoclavicular (CC) ligaments [9].

Although achievement of rigid fixation and early range of motion (ROM) are advantages of hook plate fixation leading to satisfactory clinical results, complications such as subacromial impingement, bony erosion, and peri-implant fracture have been noted [10-13]. As a result of these considerations, the implant is typically removed after 3 to 4 months of initial surgery. Following plate removal, it is common for the CC distance to remain similar to that of the unaffected side. However, in some cases, the CC distance reverts to the height prior to surgery [14-17]. Various reasons can contribute to inadequate healing, including that AC joint injuries predominantly occur in young, active male patients, many of whom are also active smokers [18,19].

Smoking has a detrimental effect on the outcomes of many orthopedic treatments. Among them, procedures requiring ligament and tendon restoration, such as anterior cruciate ligament reconstruction, rotator cuff repair, and lateral ankle ligament reconstruction, have been reported in numerous studies to be adversely affected by smoking [20-24]. Likewise, considering the importance of tendon healing, it is conceivable that smoking may also adversely affect AC joint injuries. However, as of our current understanding, no study has specifically investigated the relationship between smoking and AC joint injuries.

Therefore, the purpose of this study is to determine the association between smoking and clinical outcomes of hook plate fixation for acute AC joint injuries. We hypothesized that smoking would adversely affect AC and CC ligament healing, leading to loss of reduction and unfavorable consequences for patient outcomes.

# METHODS

The Institutional Review Board of Severance Hospital at the Yonsei University College of Medicine approved this study (No. 4-2023-0858), and the requirement for informed consent was waived.

This study retrospectively reviewed the data of 112 patients who had undergone hook plate fixation for acute AC joint dislocation at our institution between March 2014 to June 2022. The inclusion criteria were (1) acute Rockwood type III or V AC joint dislocation and (2) minimum 1-year follow-up after the initial surgery. Exclusion criteria were (1) fixation method other than the hook plate, (2) peri-implant complication requiring further surgical intervention such as clavicle fracture, (3) a previous history of surgery on the affected shoulder, (4) concomitant fracture of the ipsilateral shoulder, (5) former smoker (quit smoking before the surgery or during the follow-up period), and (6) individuals with a worker's compensation claim.

Overall, 82 patients were included in this study (Fig. 1). Smoking status was documented preoperatively at hospitalization and was updated on outpatient visits. Duration and quantity of smoking were obtained, and individuals who had smoked more than 100 cigarettes in their lifetime and currently smoked on a regular basis were defined as "smokers" [25]. "Nonsmokers" were defined as individuals naïve to exposure of tobacco.

### Surgical Procedure and Postoperative Rehabilitation

All surgical procedures were performed by two experienced orthopedic surgeons with expertise in shoulder surgery. The surgery was conducted under general anesthesia in the 20° beach chair position. A 7- to 8-cm-sized skin incision was made over the distal clavicle and AC joint, positioned one-fourth of the width from the posterior border of the clavicle. The AC joint was identified, and the hook component was passed through the posterior aspect of the AC joint under the acromion, while the locking plate component was placed on the distal clavicle (3.5 mm LCP clavicle hook plate, Synthes). The plate's contour and reduction status were carefully examined under fluoroscopic guidance. The depth of the hook was determined using the contralateral AC joint radiograph as a reference, and slight over-compression was intended. If there was a sufficient amount of ligament remaining, the ruptured AC ligament was repaired after hook plate fixation. After achieving satisfactory reduction, locking screw fixation and secure deltotrapezius fascial repair were performed

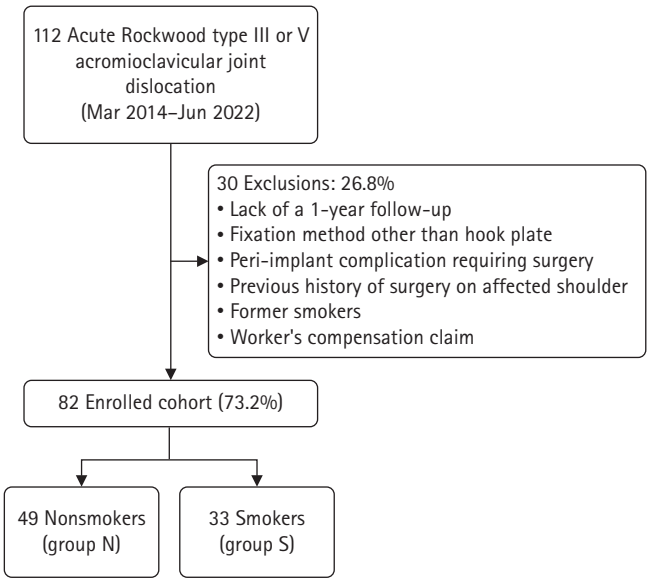


**Fig. 1.** Consolidated Standards of Reporting Trials (CONSORT) flow diagram presenting the flow of patients across the study.


https://doi.org/10.5397/cise.2023.00738

over the plate. Self-assisted circumduction exercises were initiated the day after surgery, as tolerated. Following 2 weeks of immobilization of the operated arm, self-assisted active ROM exercises were initiated. Radiographic follow-up was conducted on a monthly basis, and plate removal was performed at 3 to 4 months postoperatively.

### Clinical and Radiological Assessments

Medical records were reviewed for patient demographics and clinical factors. The demographic factors were age, sex, time from injury to surgery, and duration from hook plate fixation to implant removal. Functional outcomes were evaluated using the visual analog scale and the subjective shoulder value. Active ROM was measured, including forward flexion in the scapular plane, external rotation with the elbow at the side, and internal rotation. Internal rotation was quantified by assigning scores to the highest spinal vertebra level reached by the patient's thumb during internal rotation. T1 to T12 were scored from 1 to 12, L1–L5 were scored from 13 to 17, and the sacrum was scored 18 [26-28]. The active ROM and functional scores were assessed during every follow-up by an independent examiner who was blinded to group assignment and patient information.

Both clavicle anteroposterior views were acquired preoperatively and then monthly after surgery. Initial radiographs were used for measuring the coracoclavicular distance (CCD) and classifying the patients according to the Rockwood classification. The CCD was defined as the perpendicular distance from the highest point of the coracoid cortex to the lower margin of the clavicle cortex. The CCD was assessed in comparison with the contralateral shoulder 6 months after implant removal to ascertain the extent of reduction maintenance (Fig. 2). Two shoulder-specialized orthopedic fellows participated in the CCD measurement, and the mean values were subjected to analysis.

### Statistical Analysis

Statistical analyses were performed using SPSS software ver. 25.0 (IBM Corp.). Student t-test was used to compare continuous variables between the groups, and chi-square test was used for categorical values. Reduction maintenance status according to CCD difference was determined, and univariate regression analysis was performed. Variables with statistically significant differences were subjected to multivariate regression analysis via a stepwise method. A significance level of $P < 0.05$ was used with a 95% confidence interval.

## RESULTS

### Patient Demographics

A total of 82 individuals was enrolled in the study, 49 in group N (nonsmokers) and 33 in group S (smokers), with an average smoking history of 17.6 ± 15.9 pack-years for the smokers. There were no significant differences between the two groups in terms of

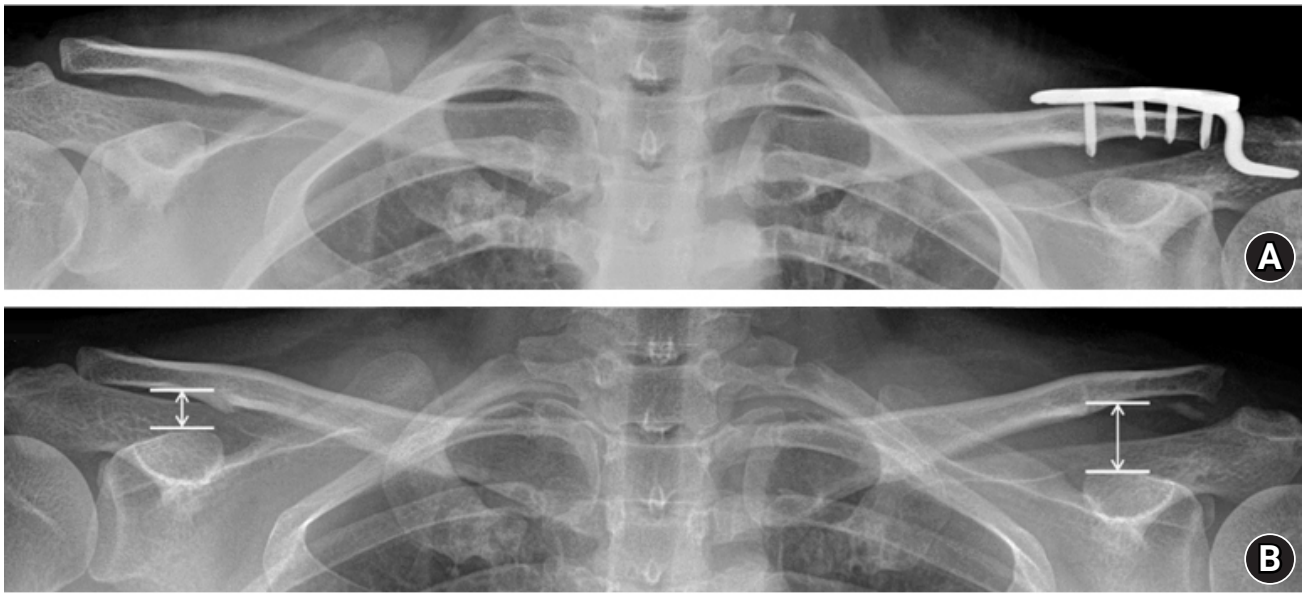


**Fig. 2.** Anteroposterior radiograph of a patient treated with hook plate fixation for an acromioclavicular joint injury. (A) Hook plate fixation with intentional over reduction. (B) Six months after implant removal. The coracoclavicular distance was defined as the perpendicular distance from the highest point of the coracoid cortex to the lower margin of the clavicle cortex.

demographic factors, including age, sex, time from injury to surgery, and duration from hook plate fixation to implant removal.

### Clinical and Radiological Outcomes

There were no notable differences in the parameters related to initial injury status such as the preoperative CCD difference and the Rockwood classification. However, the postoperative CCD difference (the CCD difference at 6 months after plate removal) was significantly higher in group S (3.1 ± 2.6 mm) compared to group N (1.7 ± 2.4 mm) (Table 1). No discernible difference in the clinical scores and active ROM were discovered between the two groups, except for internal rotation (Table 2). Univariate regression analysis was conducted using the postoperative CCD difference as the dependent variable, and smoking status and preoperative CCD difference were identified as the significant factors. Furthermore, as confirmed by multivariate regression analysis, both factors independently influenced the postoperative CCD difference (Table 3). Among the patients in group S, two experienced chronic pain associated with reduction loss and underwent CC ligament reconstruction.

## DISCUSSION

The primary finding of this study is that smoking has a detrimental effect on ligament healing in patients with acute AC injury. Despite differences in radiographic parameters, the two groups exhibited comparable patient-reported clinical outcome scores and ROM. Furthermore, regression analysis established smoking and the initial CCD difference as independent risk factors for increase in the postoperative CCD difference.

Hook plate fixation has been recognized as a straightforward procedure with satisfactory clinical outcomes for treating acute AC joint dislocation [17,29]. Ko et al. [30] conducted a long-term outcome comparison between hook plate fixation and the suture button fixation technique. The study did not find significant differences in terms of functional outcome scores, final CCD, or

**Table 1.** Demographic characteristics

| Variable | Nonsmoker (n = 49) | Smoker (n = 33) | P-value |
|---|---|---|---|
| Age (yr) | 42.9 ± 15.9 | 38.9 ± 13.3 | 0.241 |
| Sex | | | 0.991 |
| Male | 46 (93.8) | 31 (94.0) | |
| Female | 3 (6.2) | 2 (6.0) | |
| Rockwood classification | | | 0.499 |
| III | 26 (53.1) | 15 (45.5) | |
| V | 23 (46.9) | 18 (54.5) | |
| Time from injury to operation (day) | 5.6 ± 4.7 | 5.0 ± 3.7 | 0.535 |
| Time to implant removal (day) | 114.5 ± 22.4 | 120.7 ± 45.1 | 0.415 |
| Acromioclavicular ligament repair | 9 (52.9) | 8 (47.1) | 0.520 |
| Preoperative CCD difference (mm) | 9.6 ± 3.1 | 9.7 ± 2.7 | 0.800 |
| Postoperative CCD difference (mm) | 1.7 ± 2.4 | 3.1 ± 2.6 | 0.017 |

Values are presented as mean ± standard deviation or number (%).
CCD: coracoclavicular distance, CCD preoperative: measured on plain radiographs of initial injury, CCD postoperative: measured on plain radiographs 6 months after plate removal.

**Table 2.** Functional scores and active range of motion between groups

| Variable | Nonsmoker (n = 49) | Smoker (n = 33) | P-value |
|---|---|---|---|
| VAS score | 1.57 ± 0.74 | 1.88 ± 0.96 | 0.111 |
| SSV score | 85.31 ± 7.93 | 81.82 ± 9.83 | 0.080 |
| Forward flexion | 150.71 ± 8.84 | 147.61 ± 9.90 | 0.141 |
| External rotation | 57.96 ± 4.07 | 56.36 ± 4.89 | 0.127 |
| Internal rotation | 14.10 ± 1.28 | 14.70 ± 1.13 | 0.034* |

Values are presented as mean ± standard deviation. The internal rotation was measured using the highest spinal segment the patient could reach with his or her thumb up. To facilitate statistical analysis, the spinal segment levels were converted into continuous numbers: T1 to T12 were designated as 1 to 12; L1 to L5, as 13 to 17; and the sacrum, as 18.
VAS: visual analog scale, SSV: subjective shoulder value.
*Indicates $P < 0.05$.


https://doi.org/10.5397/cise.2023.00738

**Table 3.** Uni- and multivariable regression analysis of postoperative CCD in the affected shoulder

| Variable | Univariable beta coefficient | 95% CI | | P-value | Multivariable beta coefficient | 95% CI | | P-value |
|---|---|---|---|---|---|---|---|---|
| | | Lower | Upper | | | Lower | Upper | |
| Smoking | | | | | | | | |
| Nonsmoker | Ref | | | | | | | |
| Smoker | 1.377 | 0.258 | 2.496 | 0.017* | 1.296 | 0.364 | 2.228 | 0.007* |
| Sex | | | | | | | | |
| Male | Ref | | | | | | | |
| Female | −0.073 | −2.450 | 2.305 | 0.952 | | | | |
| Age | −0.033 | −0.071 | 0.004 | 0.083 | | | | |
| Preoperative CCD difference | 0.485 | 0.321 | 0.649 | < 0.001* | 0.479 | 0.321 | 0.636 | < 0.001* |
| Time from injury to operation | 0.026 | −0.108 | 0.160 | 0.698 | | | | |
| Time to implant removal | 0.003 | −0.014 | 0.020 | 0.748 | | | | |

CCD: coracoclavicular distance, CI: confidence interval, Ref: reference.
*Indicates P < 0.05.

complications between the two treatment groups. Therefore, both treatments were concluded to be viable and effective options for addressing AC joint dislocation. Suture button fixation does not require a second surgery for device removal, and the retained suture loop prevents further displacement, facilitating ligament healing over a longer period of time. On the contrary, for hook plate fixation, removal is necessary, which emphasizes the importance of achieving satisfactory ligament healing before plate removal. Unlike degenerative shoulder conditions such as rotator cuff tears, AC joint injuries are common among young, active male patients with a high prevalence of smoking, as evidenced by our cohort, where smoking was observed in 36% of the cases [18,19]. While smoking is well known to adversely affect ligament healing [31,32], the specific impact of smoking on healing of the ligaments after hook plate fixation for AC joint injury remains uncertain. For this reason, we initiated this study.

Reduction loss associated after hook plate removal has been reported in the literature. In a recent retrospective study of 118 patients by Lee et al. [33], risk factors for reduction loss after hook plate fixation were identified as female sex, delayed time to surgery (>7 days), and the initial coracoid clavicular displacement ratio. The initial CCD reflects the degree of damage to the soft tissue surrounding the AC joint and was found to affect reduction loss, aligning with our results. On the other hand, the duration to surgery and female sex did not significantly affect the postoperative CCD difference in our cohort. This may be because most patients (80.4%) underwent treatment within 1 week, and only five female patients were enrolled, attenuating the impact on the outcome.

Our study is focused on establishing the effect of smoking on the outcome of hook plate fixation, and we observed an increase in the postoperative CCD difference related to smoking. Smoking is recognized for its adverse impact on the outcomes of orthopedic procedures involving ligament healing. Unfavorable outcomes, such as increased anterior translation, as well as significantly low subjective and objective clinical scores, have been found to be related to smoking in anterior cruciate ligament reconstruction [20]. Park et al. [23] performed a propensity score matched analysis to determine the effect of smoking on healing of rotator cuff tears after arthroscopic repair. They noted higher retear rates in smokers (29.4%) compared to nonsmokers (5.9%), confirming the association between smoking and compromised rotator cuff healing. Studies have shown that smoking hinders normal regeneration of musculoskeletal tissue, impairing microvascular flow and disrupting the balance of bone and collagen metabolism [34,35]. Nicotine, the main component of tobacco, impedes cell proliferation, vascular ingrowth, and collagen formation [32,36,37]. Additionally, carbon monoxide and hydrogen cyanide, along with nicotine-induced vasoconstriction, further contribute to tissue hypoxia and delay the healing process [38,39]. Based on these research findings, it is essential to emphasize the importance of smoking cessation to patients considering hook plate fixation for acute AC joint injuries.

In the current study, smoking status did not result in a statistically significant difference in clinical outcomes, such as ROM and functional score, except internal rotation. Smoking is recognized for its potential to cause synovial inflammation and contributes to the onset of stiff shoulder, which can explain the difficulty in internal rotation according to our study [40]. Although our findings are based on a short-term follow-up period, the negative effect of smoking on radiographic CCD maintenance did not lead to discernible differences in clinical outcomes. Furthermore, considering that one point in internal rotation scoring is equivalent to the height of one vertebral body, the actual clini-

cal significance may not be substantial. Similarly, the findings of Lee et al. [33] acknowledge that the loss of reduction did not exert a significant influence on short-term clinical outcomes during the 1-year follow-up. Nevertheless, two patients in the smoker group required additional CC ligament reconstruction due to chronic pain, and different conclusions may arise from longer-term studies.

There were several limitations to this study. First, it was a retrospective study with non-randomized patient assignment, which had the potential for selection bias. Second, the study was conducted with a small sample size. Conducting a multi-center study with a larger number of patients will likely provide more precise insights into the risk factors contributing to the reduction loss. Finally, the exact CCD measurement may have varied on the plain radiographs depending on the observers and the angles of radiograph acquisition.

## CONCLUSIONS

Smoking was found to have a detrimental impact on ligament healing after hook plate fixation for acute AC joint dislocations. This finding emphasizes the importance of smoking cessation to optimize reduction maintenance after AC joint injury.

## NOTES

### ORCID


| | |
|---|---|
| Jee-Hoon Choi | https://orcid.org/0000-0002-6732-9738 |
| Yong-Min Chun | https://orcid.org/0000-0002-8147-6136 |
| Tae-Hwan Yoon | https://orcid.org/0000-0002-2859-5240 |


### Author contributions

Conceptualization: THY. Data curation: YMC, THY. Formal Analysis: THY. Investigation: THY. Methodology: JHC, THY. Project administration: THY. Resources: THY. Software: THY. Supervision: YMC, THY. Validation: JHC, THY. Visualization: JHC, THY. Writing – original draft: JHC, THY. Writing – review & editing: THY.

### Conflict of interest

Yong-Min Chun is an editorial board member of the journal but was not involved in the peer reviewer selection, evaluation, or decision process of this article. No other potential conflict of interest relevant to this article was reported.


### Funding

None.


### Data availability

Contact the corresponding author for data availability.


### Acknowledgments

None.


## REFERENCES


1. Nordin JS, Olsson O, Lunsjö K. Acromioclavicular joint dislocations: incidence, injury profile, and patient characteristics from a prospective case series. JSES Int 2020;4:246–50.
2. Barth J, Duparc F, Baverel L, et al. Prognostic factors to succeed in surgical treatment of chronic acromioclavicular dislocations. Orthop Traumatol Surg Res 2015;101(8 Suppl):S305–11.
3. Cisneros LN, Reiriz JS. Management of chronic unstable acromioclavicular joint injuries. J Orthop Traumatol 2017;18:305–18.
4. Beitzel K, Cote MP, Apostolakos J, et al. Current concepts in the treatment of acromioclavicular joint dislocations. Arthroscopy 2013;29:387–97.
5. DeBerardino TM, Pensak MJ, Ferreira J, Mazzocca AD. Arthroscopic stabilization of acromioclavicular joint dislocation using the AC graftrope system. J Shoulder Elbow Surg 2010;19(2 Suppl):47–52.
6. Tauber M. Management of acute acromioclavicular joint dislocations: current concepts. Arch Orthop Trauma Surg 2013;133:985–95.
7. Mazzocca AD, Arciero RA, Bicos J. Evaluation and treatment of acromioclavicular joint injuries. Am J Sports Med 2007;35:316–29.
8. Faraj AA, Ketzer B. The use of a hook-plate in the management of acromioclavicular injuries: report of ten cases. Acta Orthop Belg 2001;67:448–51.
9. Kashii M, Inui H, Yamamoto K. Surgical treatment of distal clavicle fractures using the clavicular hook plate. Clin Orthop Relat Res 2006;447:158–64.
10. Chaudry SN, Waseem M. Clavicular hook plate: complications of retaining the implant. Injury 2006;37:665.
11. Chiang CL, Yang SW, Tsai MY, Kuen-Huang Chen C. Acromion osteolysis and fracture after hook plate fixation for acromioclavicular joint dislocation: a case report. J Shoulder Elbow Surg 2010;19:e13–5.
12. Ding M, Ni J, Hu J, Song D. Rare complication of clavicular hook plate: clavicle fracture at the medial end of the plate. J Shoulder Elbow Surg 2011;20:e18–20.
13. Hoffler CE, Karas SG. Transacromial erosion of a locked subacromial hook plate: case report and review of literature. J



https://doi.org/10.5397/cise.2023.00738

Shoulder Elbow Surg 2010;19:e12–5.
14. Weinstein DM, McCann PD, McIlveen SJ, Flatow EL, Bigliani LU. Surgical treatment of complete acromioclavicular dislocations. Am J Sports Med 1995;23:324–31.
15. Ejam S, Lind T, Falkenberg B. Surgical treatment of acute and chronic acromioclavicular dislocation Tossy type III and V using the hook plate. Acta Orthop Belg 2008;74:441–5.
16. Hemmann P, Koch M, Gühring M, Bahrs C, Ziegler P. Acromioclavicular joint separation treated with clavicular hook plate: a study of radiological and functional outcomes. Arch Orthop Trauma Surg 2021;141:603–10.
17. Kienast B, Thietje R, Queitsch C, Gille J, Schulz AP, Meiners J. Mid-term results after operative treatment of rockwood grade III-V acromioclavicular joint dislocations with an AC-hook-plate. Eur J Med Res 2011;16:52–6.
18. Fraser-Moodie JA, Shortt NL, Robinson CM. Injuries to the acromioclavicular joint. J Bone Joint Surg Br 2008;90:697–707.
19. Pallis M, Cameron KL, Svoboda SJ, Owens BD. Epidemiology of acromioclavicular joint injury in young athletes. Am J Sports Med 2012;40:2072–7.
20. Kim SJ, Lee SK, Kim SH, Kim SH, Ryu SW, Jung M. Effect of cigarette smoking on the clinical outcomes of ACL reconstruction. J Bone Joint Surg Am 2014;96:1007–13.
21. Karim A, Pandit H, Murray J, Wandless F, Thomas NP. Smoking and reconstruction of the anterior cruciate ligament. J Bone Joint Surg Br 2006;88:1027–31.
22. Bishop JY, Santiago-Torres JE, Rimmke N, Flanigan DC. Smoking predisposes to rotator cuff pathology and shoulder dysfunction: a systematic review. Arthroscopy 2015;31:1598–605.
23. Park JH, Oh KS, Kim TM, et al. Effect of smoking on healing failure after rotator cuff repair. Am J Sports Med 2018;46:2960–8.
24. Lee DO, Eom JS, Jung HG. The effect of smoking on the outcomes of lateral ankle ligament reconstruction. J Orthop Sci 2018;23:88–91.
25. Bondy SJ, Victor JC, Diemert LM. Origin and use of the 100 cigarette criterion in tobacco surveys. Tob Control 2009;18:317–23.
26. Kim SJ, Choi YR, Jung M, Lee W, Chun YM. Arthroscopic repair of anterosuperior massive rotator cuff tears: does repair integrity affect outcomes. Am J Sports Med 2017;45:1762–8.
27. Yoon JS, Kim SJ, Choi YR, Kim SH, Chun YM. Arthroscopic repair of the isolated subscapularis full-thickness tear: single- versus double-row suture-bridge technique. Am J Sports Med 2019;47:1427–33.
28. Oh JH, Kim SH, Kwak SH, Oh CH, Gong HS. Results of concomitant rotator cuff and SLAP repair are not affected by unhealed SLAP lesion. J Shoulder Elbow Surg 2011;20:138–45.
29. Oh JH, Min S, Jung JW, et al. Clinical and radiological results of hook plate fixation in acute acromioclavicular joint dislocations and distal clavicle fractures. Clin Shoulder Elb 2018;21:95–100.
30. Ko SH, Lee CC, Jeon YD, Han JW, Lee KJ. Long-term clinical outcomes after tightrope versus hook plate fixation for acute acromioclavicular joint dislocation. Orthop J Sports Med 2023;11:23259671231165097.
31. Kanneganti P, Harris JD, Brophy RH, Carey JL, Lattermann C, Flanigan DC. The effect of smoking on ligament and cartilage surgery in the knee: a systematic review. Am J Sports Med 2012;40:2872–8.
32. Galatz LM, Silva MJ, Rothermich SY, Zaegel MA, Havlioglu N, Thomopoulos S. Nicotine delays tendon-to-bone healing in a rat shoulder model. J Bone Joint Surg Am 2006;88:2027–34.
33. Lee YS, Kim DS, Jung JW, Jo YH, Lee CH, Lee BG. Risk factors of loss of reduction after acromioclavicular joint dislocation treated with a hook plate. J Orthop Traumatol 2023;24:10.
34. Argintar E, Triantafillou K, Delahay J, Wiesel B. The musculoskeletal effects of perioperative smoking. J Am Acad Orthop Surg 2012;20:359–63.
35. Lee JJ, Patel R, Biermann JS, Dougherty PJ. The musculoskeletal effects of cigarette smoking. J Bone Joint Surg Am 2013;95:850–9.
36. Xanthoulea S, Deliaert A, Romano A, Rensen SS, Buurman WA, van der Hulst RR. Nicotine effect on inflammatory and growth factor responses in murine cutaneous wound healing. Int Immunopharmacol 2013;17:1155–64.
37. Lundgreen K, Lian OB, Scott A, Nassab P, Fearon A, Engebretsen L. Rotator cuff tear degeneration and cell apoptosis in smokers versus nonsmokers. Arthroscopy 2014;30:936–41.
38. Jensen JA, Goodson WH, Hopf HW, Hunt TK. Cigarette smoking decreases tissue oxygen. Arch Surg 1991;126:1131–4.
39. Whiteford L. Nicotine, CO and HCN: the detrimental effects of smoking on wound healing. Br J Community Nurs 2003;8:S22–6.
40. Itoi E, Arce G, Bain GI, et al. Shoulder stiffness: current concepts and concerns. Arthroscopy 2016;32:1402–14.

Original Article

Clin Shoulder Elbow 2023;26(4):380-389
https://doi.org/10.5397/cise.2023.00479

CiSE
Clinics in Shoulder and Elbow

eISSN 2288-8721

# Anatomic total shoulder arthroplasty with a nonspherical humeral head and inlay glenoid: 90-day complication profile in the inpatient versus outpatient setting

**Andrew D. Posner, Michael C. Kuna, Jeremy D. Carroll, Eric M. Perloff, Matthew J. Anderson, Ian D. Hutchinson, Joseph P. Zimmerman**

*Department of Orthopedic Surgery, Albany Medical Center, Albany, NY, USA*

**Background:** Total shoulder arthroplasty (TSA) with a nonspherical humeral head component and inlay glenoid is a successful bone-preserving treatment for glenohumeral arthritis. This study aimed to describe the 90-day complication profile of TSA with this prosthesis and compare major and minor complication and readmission rates between inpatient- and outpatient-procedure patients.
**Methods:** A retrospective review was performed of a consecutive cohort of patients undergoing TSA with a nonspherical humeral head and inlay glenoid in the inpatient and outpatient settings by a single surgeon between 2017 and 2022. Age, sex, body mass index, American Society of Anesthesiologists (ASA) score, Charlson Comorbidity Index (CCI), and 90-day complication and readmission rates were compared between inpatient and outpatient groups.
**Results:** One hundred eighteen TSAs in 111 patients were identified. Mean age was 64.9 years (range, 39–90) and 65% of patients were male. Ninety-four (80%) and 24 (20%) patients underwent outpatient and inpatient procedures, respectively. Four complications (3.4%) were recorded: axillary nerve stretch injury, isolated ipsilateral arm deep venous thrombosis (DVT), ipsilateral arm DVT with pulmonary embolism requiring readmission, and gastrointestinal bleed requiring readmission. There were no reoperations or other complications. Outpatients were younger with lower ASA and CCI scores than inpatients; however, there was no difference in complications (1/24 vs. 3/94, P=1.00) or readmissions (1/24 vs. 1/94, P=0.37) between these two groups.
**Conclusions:** TSA with a nonspherical humeral head and inlay glenoid can be performed safely in both inpatient and outpatient settings. Rates of early complications and readmissions were low with no difference according to surgical setting.
**Level of evidence:** IV.

**Keywords:** Total shoulder arthroplasty; Nonspherical humeral head; Inlay glenoid; Outpatient; Complications

## INTRODUCTION

Total shoulder arthroplasty (TSA) is an effective surgical treatment for end stage glenohumeral arthritis not resolved by conservative treatment [1,2]. Anatomic TSA prostheses designs continue to evolve and there is a growing trend towards the use of bone-preserving prostheses as alternatives to traditional stemmed humeral implants [3-6]. Bone-preserving prostheses, such as stemless TSA and humeral head resurfacing designs, are also associated with shorter operative and anesthesia time, a lower risk of periprosthetic fracture, less intraoperative blood loss, and preserved anatomy for easier revision procedures than traditional

Received: June 17, 2023 Revised: August 12, 2023 Accepted: August 19, 2023
Correspondence to: Andrew D. Posner
Department of Orthopedic Surgery, Albany Medical Center, 1367 Washington Ave, Suite 202, Albany, NY 12206, USA
Tel: +1-518-453-3079, Fax: +1-518-453-1463, E-mail: Andrew.d.posner1@gmail.com, ORCID: https://orcid.org/0000-0002-6021-3273

Copyright© 2023 Korean Shoulder and Elbow Society.
This is an Open Access article distributed under the terms of the Creative Commons Attribution Non-Commercial License (http://creativecommons.org/licenses/by-nc/4.0/) which permits unrestricted non-commercial use, distribution, and reproduction in any medium, provided the original work is properly cited.

stemmed TSA prostheses [3,6-13]. Potential disadvantages include dependence on proximal bone stock [6]. TSA with a nonspherical humeral head and an inlay glenoid is one of the available bone-preserving prosthesis options. This implant aims to replicate the native anatomy of both the humerus and glenoid with the goal of restoring natural movement and improving component stability [14,15]. Numerous studies have reported excellent patient clinical outcomes with use of this prosthesis, but none of these prior studies reported outpatient complications [14-19].

Progressive improvements in shoulder arthroplasty techniques, perioperative protocols, and pain management strategies have allowed for increased utilization of outpatient TSA [20]. In addition, changes in healthcare policy with an increased focus on value-based medical care have further contributed to the rapid growth of outpatient arthroplasty [21]. Previous studies have described the success and safety of outpatient shoulder arthroplasty following the use of traditional stemmed TSA prostheses [1,17,20-23]. Despite the literature describing outcomes and complications following the use of traditional prostheses, few studies have evaluated complications and readmissions in the outpatient setting following the use of newer generation implants. Although outpatient arthroplasty rates are increasing, no large cohort studies describing 90-day complication rates for outpatient stemless TSA or humeral head resurfacing are available [6,24,25].

There is a paucity of literature describing complications of TSA and the safety of outpatient versus inpatient TSA surgery with a nonspherical humeral head and an inlay glenoid. The purpose of this study was to assess the 90-day complication profile of TSA with the above-mentioned prosthesis and compare early complication and readmission rates between patients undergoing inpatient or outpatient procedures. We hypothesized that TSA with a nonspherical humeral head and inlay glenoid could be performed safely in both the inpatient and outpatient settings with a low rate of early complications. Furthermore, we hypothesized that there would be no difference in complication or readmission rates between patients who underwent inpatient versus outpatient TSA.

## METHODS

### Patient Selection

Institutional Review Board approval was obtained for the study (No. 5248). Informed patient consent was waived for this retrospective review by our Institutional Review Board. A retrospective chart review was conducted in a consecutive cohort of patients who underwent TSA with a nonspherical humeral head implant and an inlay glenoid replacement (Hemi-CAP OVO/Inlay Glenoid Total Shoulder System; Arthrosurface). Procedures were performed by a single surgeon (JPZ) between November 2017 and June 2022. Patient selection for this TSA prosthesis and the determination of surgical setting are outlined in Fig. 1. Inclusion criteria were primary glenohumeral osteoarthritis refractory to conservative treatment with an intact rotator cuff. Patients with Walch type A1, A2, B1, B2, and B3 glenoids, as diagnosed on preoperative axillary radiographs, were included [26]. Axillary radiographs have been shown to be comparable to computed tomography scans for glenoid staging [27]. Use of TSA with a nonspherical humeral head component and an inlay glenoid in Walch type A1, A2, B1, B2, and B3 glenoids is supported by multiple studies [3,16,18,19]. Exclusion criteria included diagnoses other than primary glenohumeral osteoarthritis, rotator cuff tear arthropathy, proximal humeral bone deficiency or deformity prohibitive to humeral head component fixation, and Walch C glenoids. Active smokers are not candidates for shoulder arthroplasty in the surgeon's practice due to literature documenting increased complication rates [28,29].

### Selection Criteria for Inpatient vs. Outpatient Procedures

TSA was performing in one of three surgical settings: inpatient surgery, hospital-based outpatient surgery, or outpatient surgery at a free-standing ambulatory surgery center (ASC). For inpatient procedures, the arthroplasty was performed at a hospital and the patient spent a minimum of 1 night in the hospital. For hospital-based outpatient procedures, the arthroplasty was performed at a hospital; however the patient was discharged home on the same day without spending the night in the hospital. For ASC-based outpatient procedures, the arthroplasty was performed at a free-standing surgical center, which is a facility physically independent of a hospital without an inpatient unit. Following TSA, the patient was discharged home directly from the post-anesthesia care unit at the ASC.

Patient selection for inpatient, hospital-based outpatient surgery, or ASC outpatient surgery was initially determined by preoperative anesthesia and surgeon evaluation (Fig. 1). A patient's medical status was first assessed. Patients with the presence of one or more of the following medical or social comorbidities were selected for inpatient surgery: chronic obstructive pulmonary disease on home oxygen therapy, chronic steroid use, unstable coronary artery disease/congestive heart failure/hypertension, cardiac intervention within 6 months, bleeding disorders, and lack of home social support. Currently available risk prediction tools that aid in identifying patients who are appropriate for out-

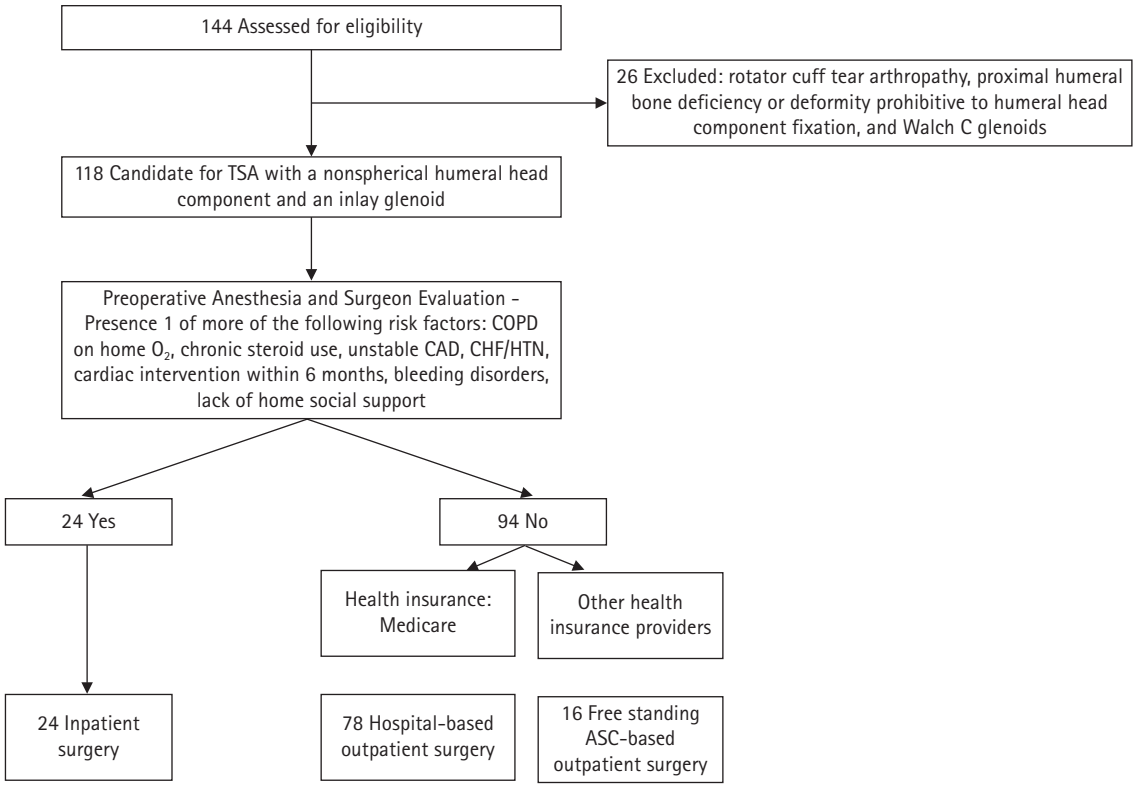


**Fig. 1.** Selection criteria for inpatient, hospital-based outpatient, or free-standing ambulatory surgery center (ASC) outpatient procedures. TSA: total shoulder arthroplasty, COPD: chronic obstructive pulmonary disease, $O_2$: oxygen therapy, CAD: coronary artery disease, CHF: congestive heart failure, HTN: hypertension.

patient TSA [30-32] were not available for use when this study was initiated. Patients without the above medical or social factors were selected for outpatient surgery. The setting of their outpatient procedure, either hospital-based outpatient surgery or outpatient surgery at an ASC, was determined by their health insurance status. The Centers for Medicare and Medicaid Services (CMS) restricts coverage for TSA at ASCs; thus, all patients with healthcare coverage provided by CMS who were candidates for outpatient surgery underwent hospital-based outpatient procedures. Patients with other health insurance providers who were candidates for outpatient surgery underwent surgery at the ASC.

## Surgical Technique

All TSA procedures utilized a nonspherical humeral head and an all-polyethylene inlay glenoid component. Patients received regional anesthesia with or with general anesthesia, as determined by anesthesiologist recommendations, and were placed in the beach-chair position. A standard deltopectoral approach with subscapularis tenotomy and biceps tenodesis was performed. Sizing guides were used to determine the true superoinferior (SI) and anteroposterior (AP) dimensions of the humeral head. For the ovoid humeral head component, the SI dimension was 4 mm larger than the AP dimension, with varying radiuses of curvature. After sizing, a guide pin was placed matching the patient's native version and inclination. The humeral head was reamed to match the spherical undersurface of the component. Bony debris were removed and a tapered post was inserted into the humerus.

The glenoid was exposed and the reamer guide pin was placed on the center point on the glenoid. The glenoid was reamed, ensuring that the glenoid trial sat flush with the surrounding native glenoid surface. The glenoid component was inserted using a third-generation cement technique. After glenoid implantation, the definitive ovoid humeral head component was impacted over the post, engaging the morse taper. The subscapularis was repaired in all cases and standard closure was performed. Preoperative and postoperative anterior-posterior and axillary radiographs are presented in Fig. 2.

Postoperatively, patients' arms were placed into a sling and they were immediately allowed pendulum exercises and range of motion of the elbow, wrist, and hand. At 2 weeks postoperatively, shoulder wall walks were allowed and formal physical therapy with a rotator cuff strengthening program was initiated. External


https://doi.org/10.5397/cise.2023.00479

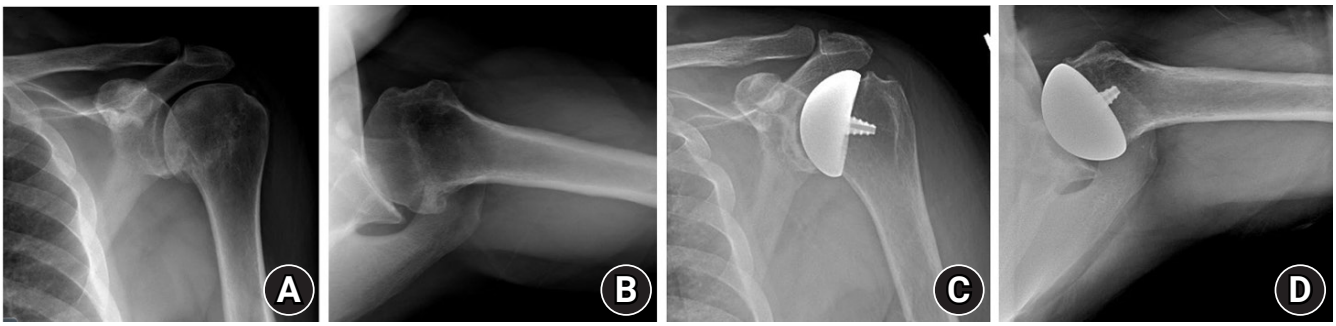


**Fig. 2.** Preoperative anteroposterior (A) and axillary (B) radiographs demonstrating glenohumeral osteoarthritis. Postoperative anteroposterior (C) and axillary (D) radiographs following total shoulder arthroplasty with nonspherical humeral head and an inlay glenoid component.

rotation was limited for 6 weeks to protect the subscapularis repair.

### Data Collection

Baseline patient characteristics and 90-day postoperative complications were collected from electronic medical records. A 90-day postoperative period was chosen to assess complications, readmission, and reoperations because this encompasses the global surgical period and appropriately reflects the medical postoperative course. Patient characteristics were age, sex, smoking status, body mass index (BMI), Charlson Comorbidity Index (CCI) score, American Society of Anesthesiologists (ASA) score, and location of surgery: either inpatient, hospital-based outpatient, or free-standing ASC.

Complications assessed within 90 days included medical and surgical complications as well as readmission. Medical and surgical complications included all adverse events as defined by the American College of Surgeons National Surgical Quality Improvement Program (ASC-NSQIP) [33], in addition to shoulder-specific complications. "Serious" adverse events were defined by ASC-NSQIP as follows: death, coma >24 hours, on ventilator >48 hours, unplanned intubation, stroke/cerebrovascular accident, thromboembolic event including deep venous thrombosis (DVT) or pulmonary embolism (PE), infectious complications (superficial surgical site infection, deep surgical site infection, organ/space infection, or sepsis), cardiac arrest, myocardial infarction, acute renal failure, return to the operating room, graft/prosthesis/flap failure, or peripheral nerve injury. "Minor" adverse events as defined by the ASC-NSQIP were wound dehiscence, blood transfusion, urinary tract infection, pneumonia, or progressive renal insufficiency. In addition, complications specific to shoulder arthroplasty were also assessed and included dislocations, wound complications, infections, subscapularis failures, tenodesis failure, hardware failure, periprosthetic fractures, arthrofibrosis, hematomas, and all-cause reoperations.

### Statistical Analyses

All analyses were conducted with use of JMP software ver. 12 (SAS Institute). Means, standard deviations, and ranges are reported for continuous variables while frequencies and percentages are reported for categorical variables. The significance of differences in descriptive statistics between patient groups was evaluated with two-tailed t-tests and Fisher's exact tests as statistically appropriate. P-values $<0.05$ were considered to be statistically significant.

## RESULTS

### Patient Demographics

One hundred eighteen TSAs in 111 patients were identified. Patient demographics, BMI, ASA score, CCI score, and surgical setting are presented in Table 1. Twenty-four patients (20%) underwent inpatient procedures while 94 patients (80%) underwent outpatient procedures. Among outpatient procedures, 78 of 94 (83%) and 16 of 94 (17%) were performed in the hospital-based outpatient and free-standing ASC settings, respectively.

### 90-Day Complications: All Patients

Complications are presented in Table 2. Within the 90-day postoperative period, four complications (3.4%) were observed: axillary nerve stretch injury, isolated ipsilateral arm DVT, ipsilateral arm DVT with PE, and upper gastrointestinal bleed (UGIB) requiring blood transfusion. Two patients (1.7%) required readmission. There were no dislocations, wound complications, infections, subscapularis failures, tenodesis failure, hardware failures, periprosthetic fractures, arthrofibrosis, hematomas, or reoperations.

One patient who underwent outpatient surgery was diagnosed with an axillary nerve injury postoperatively. The injury was attributed to intraoperative stretch neuropraxia and monitored with serial electromyography. At 9 months postoperatively, the

nerve injury had completely resolved clinically and on electromyography following observational outpatient management. One patient who underwent outpatient surgery developed a DVT on their operative extremity, diagnosed on postoperative day (POD) 18, leading to a PE. This patient required readmission and was successfully treated with oral anticoagulation. Another patient who underwent outpatient surgery also developed a DVT on their operative extremity, diagnosed on POD 9, which was successfully treated on an outpatient basis with oral anticoagulation. One patient who underwent inpatient surgery developed a UGIB on POD 4, requiring readmission for a blood transfusion. She had a history of gastroesophageal reflux disease and clopidogrel use for coronary artery disease which was restarted postoperatively; however, she denied use of nonsteroidal anti-inflammatory drugs (NSAIDs). The patient was successfully managed medically.

**Table 1.** Patient characteristics

| Patient characteristics | Value |
|---|---|
| Number of shoulders | 118 |
| Age (yr) | 64.9 ± 9.8 (39–90) |
| Sex | |
| Female | 41 (35) |
| Male | 77 (65) |
| BMI (kg/m$^2$) | 31.1 ± 6.0 (20.3–52.0) |
| ASA score | 2.5 ± 0.5 (1–3) |
| Charlson Comorbidity Index | 3.0 ± 1.7 (0–7) |
| Active smoker | 0 |
| Inpatient procedure | 24 (20) |
| Outpatient procedure | 94 (80) |
| Hospital-based outpatient (n = 94) | 78 (83) |
| Ambulatory surgery center (n = 94) | 16 (17) |

Values are presented as mean ± standard deviation (range) or number (%).
BMI: body mass index, ASA: American Society of Anesthesiologists.

### 90-Day Complications: Outpatient vs. Inpatient Surgery

Ninety-four patients (80%) had outpatient procedures, while 24 patients (20%) underwent inpatient procedures (Table 3). Patients who underwent outpatient procedures were significantly younger than those who underwent inpatient procedures (64.1 vs. 67.8, P = 0.049). Furthermore, patients who underwent outpatient procedures had significantly lower ASA (2.4 vs. 2.8, P < 0.001) and CCI scores (2.8 vs. 4.1, P < 0.001) than those who underwent inpatient procedures. Between groups, there were no significant differences in the percentage females or BMI. There were also no significant differences om rates of 90-day complications (3/94 vs. 1/24, P = 1.00) or readmissions (1/94 vs. 1/24, P = 0.37) between the two groups. In addition, there were no significant differences between rates of any complication subtype between groups.

## DISCUSSION

Our findings suggest that TSA with a nonspherical humeral head component and an inlay glenoid is associated with favorable short-term complication and readmission rates of 3.4% and 1.7%, respectively. Inpatient and outpatient TSA procedures were per-

**Table 2.** Rates of adverse events at 90 days

| Complication profile | Overall (n = 118) | Outpatient (n = 94) | Inpatient (n = 24) |
|---|---|---|---|
| Any adverse event | 4 (3.4) | 3 (3.2) | 1 (4.2) |
| ACS NSQIP "serious" adverse events | 3 (2.5) | 3 (3.2) | 0 |
| Thromboembolic event (DVT/PE) | 2 (1.7) | 2 (2.1) | 0 |
| Peripheral nerve injury | 1 (0.9) | 1 (1.1) | 0 |
| Death, coma > 24 hours, ventilator > 48 hours, unplanned intubation, CVA, infectious complication, cardiac arrest requiring CPR, MI, ARF, RTOR, and graft/prosthesis/flap failure | 0 | 0 | 0 |
| ACS NSQIP "minor" adverse events | 1 (0.9) | 0 | 1 (4.2) |
| Blood transfusion | 1 (0.9) | 0 | 1 (4.2) |
| Wound dehiscence, UTI, pneumonia | 0 | 0 | 0 |
| Readmission | 2 (1.7) | 1 (1.1) | 1 (4.2) |
| Shoulder specific complications | 0 | 0 | 0 |
| Dislocations, wound complications, infections, subscapularis failures, tenodesis failures, hardware failures, periprosthetic fractures, arthrofibrosis, hematoma, and all cause reoperations | 0 | 0 | 0 |

Values are presented as number (%).
ACS-NSQIP: American College of Surgeons National Surgical Quality Improvement Program, DVT: deep vein thrombosis, PE: pulmonary embolism, CVA: cerebrovascular accident, CPR: cardiopulmonary resuscitation, MI: myocardial infarction, ARF: acute renal failure, RTOR: return to operating room, UTI: urinary tract infection.


https://doi.org/10.5397/cise.2023.00479

**Table 3.** Outpatient versus inpatient surgery comparison

| Characteristics | Inpatient | Outpatient | P-value |
|---|---|---|---|
| Number of shoulders | 24 (20) | 94 (80) | - |
| Age (yr) | 67.8 ± 10.2 (49–90) | 64.1 ± 9.6 (39–83) | 0.05 |
| Female | 12 (50) | 29 (31) | 0.10 |
| BMI (kg/m$^2$) | 32.5 ± 7.0 (21.8– 45.6) | 31.0 ± 5.8 (20.3–52) | 0.12 |
| ASA score | 2.8 ± 0.4 (2 –3) | 2.4 ± 0.5 (1–3) | < 0.001 |
| Charlson Comorbidity Index | 4.1 ± 1.8 (0–7) | 2.8 ± 1.6 (0–7) | < 0.001 |
| Complication (90 day) | 1 (4.2) | 3 (3.2) | 1 |
| Thromboembolic event (DVT/PE) | 0 | 2 (2.1) | 1 |
| Peripheral nerve injury | 0 | 1 (1.1) | 1 |
| Blood transfusion | 1 (4.2) | 0 | 0.20 |
| Readmissions (90 day) | 1 (4.2) | 1 (1.1) | 0.37 |

Values are presented as number (%) or mean ± standard deviation (range).
BMI: body mass index, ASA: American Society of Anesthesiologists, DVT: deep vein thrombosis, PE: pulmonary embolism.

formed safely with no differences in complication rates or readmissions between surgical settings.

Shoulder arthroplasty is the primary treatment for patients with advanced glenohumeral osteoarthritis for whom conservative treatment has failed. Despite its growing use clinically, studies evaluating TSA, reverse total shoulder arthroplasty (RTSA), and hemiarthroplasty (HA) have reported concerning rates of readmissions and early medical and surgical postoperative complications [34-40]. At 90-days postoperatively, rates of complications range have been reported to range from 2.3% to 11% [35,36,41] and those of readmission from 1.8% to 11.2% [36,38,39]. Stemless TSA may be the most similar implant to TSA with a nonspherical humeral head and inlay glenoid, and while no large-cohort data 90-day studies exist, meta-analyses have reported that the short and mid-term complication rates following stemless TSA range from 8.3% to 9.7% [6,24,25]. In most reports, complications within 90 days were more likely to be medical than surgical, with the most frequent complications being related to the respiratory, renal, and cardiac systems, respectively [34,36,39]. Our 90-day complication rate of 3.4% and readmission rate of 1.7% are at the lower end of the ranges reported following the use of TSA, RTSA, HA, and stemless TSA. This comparison suggests that TSA with a humeral head component and inlay glenoid is safe and has a short-term complication profile similar to that of other TSA prostheses designs. In addition, similar to what has been reported in the literature, roughly 75% of our 90-day complications were medical in nature (DVT/PE and UGIB) while only 25% were surgical (axillary nerve stretch injury). There were no dislocations, wound complications, infections, subscapularis failures, tenodesis failures, hardware failures, periprosthetic fractures, arthrofibrosis, hematomas, or reoperations in our study.

Historically, use of bone-preserving humeral prostheses with improved glenoid stability has been prescribed for young active males who have higher rates of component loosening [4,10,35,42,43]. Advantages of Bone preserving prosthesis, such as Stemless TSA and humeral head resurfacing designs, are being compared to traditional stemmed TSA prosthesis [3,6-10,13]. Together, this may translate into fewer postoperative adverse events [11]. TSA with nonspherical humeral head and an inlay glenoid prosthesis aims to replicate the native anatomy, restore natural movement, and improve component stability [14,15]. Multiple studies have reported excellent patient clinical outcomes with use of TSA with this prosthesis design; however, no prior study evaluated outpatient complications [3,16,18,19].

In our study, there were no significant differences in either 90-day complication (3/94 vs. 1/24, P = 1.00) or readmission (1/94 vs. 1/24, P = 0.37) rates between patients undergoing outpatient or inpatient TSA. Outpatient shoulder arthroplasty is increasing in frequency and multiple studies that evaluated patients who underwent TSA, RTSA, or HA reported no significant differences in early postoperative complications between outpatient and inpatient cohorts [17,21,22,37,44]. Brolin et al. [44] and Bean at al. [45] reported that TSA and RTSA can be safely performed in a free-standing ASC setting; however no such research for TSA with a humeral head component and inlay glenoid exists. There were not enough ASC patients in our study to adequately power a comparison between patients who underwent outpatient hospital-based and outpatient ASC-based procedures. The lower proportion of procedures performed in the ASC setting may be due to TSA not being approved for CMS coverage at the time of this study.

In our study, outpatient TSA patients were significantly younger and had significantly lower ASA and CCI scores than inpatient TSA patients. These same demographic differences between co-

horts have also been reported in the TSA, RTSA, and HA literature [37,44]. Patient selection is paramount for successful and safe outpatient shoulder arthroplasty; complications, and readmission rates all increase with patient age, female sex, and medical comorbidities [21,34,46]. Identifying higher-risk patients preoperatively is essential, as they may be more appropriate candidates for inpatient procedures. Multiple risk prediction tools have been developed to aid in identifying patients appropriate for outpatient TSA [30-32]. These tools can improve patient selection for same day discharge while minimizing perioperative complications. Eventual applications of these prediction tools may allow for an evidence-based standardization of outpatient shoulder arthroplasty patient selection.

In our study, one patient had an isolated DVT, one patient had a DVT/PE requiring readmission, one patient had an axillary nerve stretch injury, and one patient had an UGIB requiring readmission and transfusion. Rates of symptomatic and asymptomatic DVT after shoulder arthroplasty range from 0.09% to 13%, and rates of PE range from 0 to 3% [47]. Rapp et al. [47], based on a review of VTE after shoulder arthroplasty, recommended that mechanical prophylaxis be considered in all patients, and that chemical prophylaxis be considered on a case-by-case basis. Iatrogenic axillary neuropraxia following TSA was reviewed by LiBrizzi et al. [48], who reported that the rate of axillary nerve injury following TSA and RTSA ranged from 0% to 16% . The most common cause of axillary nerve injury is stretch, either due to intraoperative positioning of the arm or retractor use for visualization [48]. All cases observed by LiBrizzi et al. [48] were neurapraxias that resolved completely following observation. One of our patients also experienced complete neurologic recovery at 9 months postoperatively following observational management. Lastly, we reported one case of UGIB requiring readmission and transfusion. No prior study has specifically described the incidence of UGIB following TSA; however, rates of UGIB following hip and knee arthroplasty have been reported to be as high as 4.5% [49-51]. Risk factors include preexisting peptic ulcer disease, advanced age, smoking, and use of steroids, NSAIDs, and anti-coagulation [49]. Our patient had several risk factors: she had peptic ulcer disease and was on clopidogrel, was allergic to NSAIDs, and did not take any perioperatively.

Strengths of our study are that we reported 90-day postoperative complication and readmission rates following inpatient and outpatient TSA with a nonspherical humeral head and an inlay glenoid, which have not previously been reported. One hundred eighteen patients where included, which is the largest relative cohort to receive this TSA prosthesis to date. However, 118 patients is relatively small in comparison to the number of patients evaluated in studies that have investigated traditional TSA, RTSA, and HA. Additional patient recruitment and follow-up are therefore warranted.

Limitations of our study include that only 16 surgeries were performed in the free-standing ASC setting; more patients are needed to adequately power a comparison between inpatient, outpatient hospital-based, and free-standing ASC surgeries. Once TSA in the freestanding ASC is approved by the CMS, the proportion of procedures performed there will likely increase. The aim of this study was to assess the safety of outpatient TSA with humeral head and inlay glenoid replacement, therefore no functional patient-reported outcomes or long-term complication rates were included; however, both are topics for future study as we continue to follow this cohort. Inpatient and outpatient groups were not age- or comorbidity-matched cohorts, with the outpatient group being younger and healthier. Patients who underwent outpatient procedures were selected for that surgical setting based on preoperative anesthesia and surgeon evaluation. These preoperative differences may have impacted the outcomes in the study given that age and comorbidities increase postoperative complications. Thus, we cannot interpret our results to mean that outpatient TSA with a nonspherical humeral head and inlay glenoid is applicable to all patients; our study only provides evidence that TSA with a nonspherical humeral head and inlay glenoid is safe for patients selected for outpatient surgery based on our preoperative anesthesia and surgeon evaluations.

## CONCLUSIONS

In this study, TSA with a nonspherical humeral head component and an inlay glenoid was performed with low short-term complication and readmission rates of 3.4% and 1.7%, respectively. Inpatient and outpatient TSA procedures were both performed safely with no difference in complications or readmissions between surgical settings.

## NOTES

### ORCID


| | |
|---|---|
| Andrew D. Posner | https://orcid.org/0000-0002-6021-3273 |
| Michael C. Kuna | https://orcid.org/0000-0003-4436-9670 |
| Jeremy D. Carroll | https://orcid.org/0000-0002-4281-9490 |
| Eric M. Perloff | https://orcid.org/0000-0002-8964-8019 |
| Ian D. Hutchinson | https://orcid.org/0000-0002-3410-9288 |


### Author contributions

Conceptualization: ADP, MJA, IDH, JPZ. Data Curation: ADP,


https://doi.org/10.5397/cise.2023.00479

EMP, MCK, JDC. Methodology: IDH, JPZ, Formal Analysis: ADP. Supervision: JPZ. Writing – Original Draft: ADP, MJA. Writing – Review and editing: ADP, MCK, JDC, EMP, MJA, IDH, JPZ.

### Conflict of interest

JPZ (MD) receives personal fees from Arthrosurface, unrelated to this submitted work. No other potential conflicts of interest relevant to this article were reported.

### Funding

None.

### Data availability

Contact the corresponding author for data availability.

### Acknowledgments

None.

## REFERENCES

1. Antonacci CL, Cu BJ, Erickson BJ, Vazquez O, Alberta FG. Complications and readmissions after reverse and anatomic total shoulder arthroplasty with same-day discharge. J Am Acad Orthop Surg 2021;29:116–22.
2. Brolin TJ, Cox RM, Zmistowski BM, Namdari S, Williams GR, Abboud JA. Surgeons' experience and perceived barriers with outpatient shoulder arthroplasty. J Shoulder Elbow Surg 2018;27:S82–7.
3. Egger AC, Peterson J, Jones MH, Miniaci A. Total shoulder arthroplasty with nonspherical humeral head and inlay glenoid replacement: clinical results comparing concentric and nonconcentric glenoid stages in primary shoulder arthritis. JSES Open Access 2019;3:145–53.
4. Peebles LA, Arner JW, Haber DB, Provencher MT. Glenohumeral resurfacing in young, active patients with end-stage osteoarthritis of the shoulder. Arthrosc Tech 2020;9:e1315–22.
5. Wiater JM, Levy JC, Wright SA, et al. Prospective, blinded, randomized controlled trial of stemless versus stemmed humeral components in anatomic total shoulder arthroplasty: results at short-term follow-up. J Bone Joint Surg Am 2020;102:1974–84.
6. Brabston EW, Fehringer EV, Owen MT, Ponce BA. Stemless humeral implants in total shoulder arthroplasty. J Am Acad Orthop Surg 2020;28:e277–87.
7. Burgess DL, McGrath MS, Bonutti PM, Marker DR, Delanois RE, Mont MA. Shoulder resurfacing. J Bone Joint Surg Am 2009;91:1228–38.
8. Harmer L, Throckmorton T, Sperling JW. Total shoulder arthroplasty: are the humeral components getting shorter. Curr Rev Musculoskelet Med 2016;9:17–22.
9. Levy O, Copeland SA. Cementless surface replacement arthroplasty (Copeland CSRA) for osteoarthritis of the shoulder. J Shoulder Elbow Surg 2004;13:266–71.
10. Miniaci A, Scarcella MJ. Shoulder resurfacing for treatment of focal defects and diffuse osteoarthritis. Orthopade 2021;50:112–8.
11. Mullett H, Levy O, Raj D, Even T, Abraham R, Copeland SA. Copeland surface replacement of the shoulder: results of an hydroxyapatite-coated cementless implant in patients over 80 years of age. J Bone Joint Surg Br 2007;89:1466–9.
12. Nixon RA, Dang KH, Haberli JE, O'Donnell EA. Surgical time and outcomes of stemmed versus stemless total shoulder arthroplasty. J Shoulder Elbow Surg 2022;31:S83–9.
13. Saltzman BM, Leroux TS, Verma NN, Romeo AA. Glenohumeral osteoarthritis in the young patient. J Am Acad Orthop Surg 2018;26:e361–70.
14. Gunther SB, Lynch TL, O'Farrell D, Calyore C, Rodenhouse A. Finite element analysis and physiologic testing of a novel, inset glenoid fixation technique. J Shoulder Elbow Surg 2012;21:795–803.
15. Humphrey CS, Gale AL. Spherical versus elliptical prosthetic humeral heads: a comparison of anatomic fit. J Shoulder Elbow Surg 2018;27:S50–7.
16. Cvetanovich GL, Naylor AJ, O'Brien MC, Waterman BR, Garcia GH, Nicholson GP. Anatomic total shoulder arthroplasty with an inlay glenoid component: clinical outcomes and return to activity. J Shoulder Elbow Surg 2020;29:1188–96.
17. Erickson BJ, Shishani Y, Jones S, et al. Outpatient versus inpatient anatomic total shoulder arthroplasty: outcomes and complications. JSES Int 2020;4:919–22.
18. Uribe JW, Zvijac JE, Porter DA, Saxena A, Vargas LA. Inlay total shoulder arthroplasty for primary glenohumeral arthritis. JSES Int 2021;5:1014–20.
19. Yalcin S, Scarcella M, Miniaci A. Does non-spherical humeral head with inlay glenoid re-center the glenohumeral joint. Semin Arthroplasty 2021;31:310–6.
20. Calkins TE, Mosher ZA, Throckmorton TW, Brolin TJ. Safety and cost effectiveness of outpatient total shoulder arthroplasty: a systematic review. J Am Acad Orthop Surg 2022;30:e233–41.
21. Charles MD, Cvetanovich G, Sumner-Parilla S, Nicholson GP, Verma N, Romeo AA. Outpatient shoulder arthroplasty: outcomes, complications, and readmissions in 2 outpatient settings. J Shoulder Elbow Surg 2019;28:S118–23.
22. Cimino AM, Hawkins JK, McGwin G, Brabston EW, Ponce BA,

Momaya AM. Is outpatient shoulder arthroplasty safe? A systematic review and meta-analysis. J Shoulder Elbow Surg 2021;30:1968–76.
23. Vajapey SP, Contreras ES, Neviaser AS, Bishop JY, Cvetanovich GL. Outpatient total shoulder arthroplasty: a systematic review evaluating outcomes and cost-effectiveness. JBJS Rev 2021;9:e20.00189.
24. Liu EY, Kord D, Horner NS, Leroux T, Alolabi B, Khan M. Stemless anatomic total shoulder arthroplasty: a systematic review and meta-analysis. J Shoulder Elbow Surg 2020;29:1928–37.
25. Willems JI, Hoffmann J, Sierevelt IN, van den Bekerom MP, Alta TD, van Noort A. Results of stemless shoulder arthroplasty: a systematic review and meta-analysis. EFORT Open Rev 2021;6:35–49.
26. Walch G, Badet R, Boulahia A, Khoury A. Morphologic study of the glenoid in primary glenohumeral osteoarthritis. J Arthroplasty 1999;14:756–60.
27. Aronowitz JG, Harmsen WS, Schleck CD, Sperling JW, Cofield RH, Sánchez-Sotelo J. Radiographs and computed tomography scans show similar observer agreement when classifying glenoid morphology in glenohumeral arthritis. J Shoulder Elbow Surg 2017;26:1533–8.
28. Althoff AD, Reeves RA, Traven SA, Wilson JM, Woolf SK, Slone HS. Smoking is associated with increased surgical complications following total shoulder arthroplasty: an analysis of 14,465 patients. J Shoulder Elbow Surg 2020;29:491–6.
29. Hatta T, Werthel JD, Wagner ER, et al. Effect of smoking on complications following primary shoulder arthroplasty. J Shoulder Elbow Surg 2017;26:1–6.
30. Biron DR, Sinha I, Kleiner JE, et al. A novel machine learning model developed to assist in patient selection for outpatient total shoulder arthroplasty. J Am Acad Orthop Surg 2020;28:e580–5.
31. Fournier MN, Brolin TJ, Azar FM, Stephens R, Throckmorton TW. Identifying appropriate candidates for ambulatory outpatient shoulder arthroplasty: validation of a patient selection algorithm. J Shoulder Elbow Surg 2019;28:65–70.
32. Goltz DE, Burnett RA, Levin JM, et al. Appropriate patient selection for outpatient shoulder arthroplasty: a risk prediction tool. J Shoulder Elbow Surg 2022;31:235–44.
33. American College Surgeons. User guide for the 2019 ACS NSQIP participant use data file [Internet]. American College Surgeons; 2020 [cited 2023 Aug 1]. Available from: https://www.facs.org/media/isko30q1/nsqip_puf_userguide_2019.pdf
34. Anakwenze OA, O'Donnell EA, Jobin CM, Levine WN, Ahmad CS. Medical complications and outcomes after total shoulder arthroplasty: a nationwide analysis. Am J Orthop (Belle Mead NJ) 2018;47.
35. Craig RS, Lane JC, Carr AJ, Furniss D, Collins GS, Rees JL. Serious adverse events and lifetime risk of reoperation after elective shoulder replacement: population based cohort study using hospital episode statistics for England. BMJ 2019;364:l298.
36. Kennon JC, Songy CE, Marigi E, et al. Cost analysis and complication profile of primary shoulder arthroplasty at a high-volume institution. J Shoulder Elbow Surg 2020;29:1337–45.
37. Leroux TS, Basques BA, Frank RM, et al. Outpatient total shoulder arthroplasty: a population-based study comparing adverse event and readmission rates to inpatient total shoulder arthroplasty. J Shoulder Elbow Surg 2016;25:1780–6.
38. Mahoney A, Bosco JA, Zuckerman JD. Readmission after shoulder arthroplasty. J Shoulder Elbow Surg 2014;23:377–81.
39. Schairer WW, Zhang AL, Feeley BT. Hospital readmissions after primary shoulder arthroplasty. J Shoulder Elbow Surg 2014;23:1349–55.
40. Waterman BR, Dunn JC, Bader J, Urrea L, Schoenfeld AJ, Belmont PJ. Thirty-day morbidity and mortality after elective total shoulder arthroplasty: patient-based and surgical risk factors. J Shoulder Elbow Surg 2015;24:24–30.
41. Virani NA, Williams CD, Clark R, Polikandriotis J, Downes KL, Frankle MA. Preparing for the bundled-payment initiative: the cost and clinical outcomes of total shoulder arthroplasty for the surgical treatment of glenohumeral arthritis at an average 4-year follow-up. J Shoulder Elbow Surg 2013;22:1601–11.
42. Schoch B, Schleck C, Cofield RH, Sperling JW. Shoulder arthroplasty in patients younger than 50 years: minimum 20-year follow-up. J Shoulder Elbow Surg 2015;24:705–10.
43. Sperling JW, Cofield RH, Rowland CM. Minimum fifteen-year follow-up of Neer hemiarthroplasty and total shoulder arthroplasty in patients aged fifty years or younger. J Shoulder Elbow Surg 2004;13:604–13.
44. Brolin TJ, Mulligan RP, Azar FM, Throckmorton TW. Neer Award 2016: outpatient total shoulder arthroplasty in an ambulatory surgery center is a safe alternative to inpatient total shoulder arthroplasty in a hospital: a matched cohort study. J Shoulder Elbow Surg 2017;26:204–8.
45. Bean BA, Connor PM, Schiffern SC, Hamid N. Outpatient shoulder arthroplasty at an ambulatory surgery center using a multimodal pain management approach. J Am Acad Orthop Surg Glob Res Rev 2018;2:e064.
46. Dunn JC, Lanzi J, Kusnezov N, Bader J, Waterman BR, Belmont PJ. Predictors of length of stay after elective total shoulder arthroplasty in the United States. J Shoulder Elbow Surg 2015;24:754–9.


https://doi.org/10.5397/cise.2023.00479

47. Rapp CM, Shields EJ, Wiater BP, Wiater JM. Venous thromboembolism after shoulder arthoplasty and arthroscopy. J Am Acad Orthop Surg 2019;27:265–74.
48. LiBrizzi CL, Rojas J, Joseph J, Bitzer A, McFarland EG. Incidence of clinically evident isolated axillary nerve injury in 869 primary anatomic and reverse total shoulder arthroplasties without routine identification of the axillary nerve. JSES Open Access 2019;3:48–53.
49. Adenikinju AS, Feng JE, Namba CA, Luthringer TA, Lajam CM. Gastrointestinal complications warranting invasive interventions following total joint arthroplasty. J Arthroplasty 2019; 34:2780–4.
50. Lalmohamed A, Vestergaard P, Javaid MK, et al. Risk of gastrointestinal bleeding in patients undergoing total hip or knee replacement compared with matched controls: a nationwide cohort study. Am J Gastroenterol 2013;108:1277–85.
51. Sharma S. Upper gastrointestinal bleeding after hip and knee arthroplasty. Orthopedics 2006;29:255–7.

Original Article

Clin Shoulder Elbow 2023;26(4):390-396
https://doi.org/10.5397/cise.2023.00346

CiSE
Clinics in Shoulder and Elbow

eISSN 2288-8721

# Glenohumeral versus subacromial steroid injections for impingement syndrome with mild stiffness: a randomized controlled trial

Yong-Tae Kim[1,*], Tae-Yeong Kim[2,*], Jun-Beom Lee[2], Jung-Taek Hwang[2]

[1]*Department of Orthopedic Surgery, Hallym University Dongtan Sacred Heart Hospital, Hwaseong, Korea*
[2]*Department of Orthopedic Surgery, Hallym University Chuncheon Sacred Heart Hospital, Chuncheon, Korea*

**Background:** The subacromial (SA) space is a commonly used injection site for treatment of impingement syndrome. For shoulder stiffness, glenohumeral (GH) injections are commonly performed. However, in cases of impingement syndrome with mild shoulder stiffness, the optimal site of steroid injection has yet to be identified.
**Methods:** This prospective, randomized study compared the short-term outcomes of ultrasound-guided GH and SA steroid injections in patients who were diagnosed with impingement syndrome and mild stiffness. Each group comprised 24 patients who received either a GH or SA injection of 40 mg of triamcinolone. Range of motion and clinical scores were assessed before and 3, 7, and 13 weeks after the injection.
**Results:** GH and SA injections significantly improved the range of motion and clinical scores after 13 weeks of follow-up. Notably, targeting the GH joint resulted in an earlier gain of forward elevation, external rotation, and internal rotation in 3 weeks ($P<0.001$, $P=0.012$, and $P=0.002$, respectively) and of internal rotation and a Constant-Murley score in 7 weeks ($P<0.001$ and $P=0.046$). Subsequent measurements were similar between the groups and showed a steady improvement in all ranges of motion and clinical scores.
**Conclusions:** GH injections may be more favorable than SA injections for treatment of impingement syndrome with mild stiffness, especially in improving the range of motion in the early period. However, the procedures showed similar outcomes after 3 months.
**Level of evidence:** I.

**Keywords:** Shoulder impingement syndrome; Adhesive capsulitis; Intra-articular injection; Subacromial injection; Steroid injection

## INTRODUCTION

Impingement syndrome is a frequently occurring shoulder disorder caused by compression or friction of the rotator cuff tendons and subacromial (SA) bursa against the SA arch [1]. This condition results in pain when elevating the shoulder, which often leads to a limited range of motion (ROM), causing secondary shoulder stiffness [2].

Steroid injection is a recognized treatment option for both impingement syndrome and shoulder stiffness [3]. Its purpose is to reduce inflammation and pain, thereby improving function and ROM in the shoulder joint [4]. However, the effectiveness of ste-

Received: May 6, 2023 Revised: June 25, 2023 Accepted: July 12, 2023
Correspondence to: Jung-Taek Hwang
Department of Orthopedic Surgery, Hallym University Chuncheon Sacred Heart Hospital, 77 Sakju-ro, Chuncheon, Korea
Tel: +82-33-240-5197, Fax: +82-33-241-8063, E-mail: drakehjt@hanmail.net, ORCID: https://orcid.org/0000-0003-4189-084X

*These authors contributed equally to this work as co-first authors.

Copyright© 2023 Korean Shoulder and Elbow Society.
This is an Open Access article distributed under the terms of the Creative Commons Attribution Non-Commercial License (http://creativecommons.org/licenses/by-nc/4.0/) which permits unrestricted non-commercial use, distribution, and reproduction in any medium, provided the original work is properly cited.

roid injections may depend on the site of injection, specifically in relation to the primary diagnosis. While SA injections are essential in treating bursal inflammation and impingement syndrome, glenohumeral (GH) injections are more effective in managing capsular inflammation, which is commonly observed in shoulder stiffness [5,6].

Despite the commonality of impingement syndrome with a resultant "mild" (defined in the Methods section) stiffness in the outpatient setting, there is a shortage of literature regarding the optimal injection site. It remains to be determined if addressing bursal pain through an SA injection will ultimately relieve stiffness, or if targeting the stiff capsule with a GH injection will provide a better outcome in terms of function. Several studies have compared injection sites in primary shoulder stiffness [5,7]; however, no study has yet to directly compare the two methods in treating impingement syndrome. Therefore, the current study aimed to compare the effectiveness of ultrasound-guided steroid injections in the SA and GH spaces for treating impingement syndrome with mild stiffness.

## METHODS

This study was approved by Institutional Review Board of Hallym University Chuncheon Sacred Heart Hospital (No. 2012-96). Informed consent was obtained from all patients.

### Patient Enrollment

Following approval from the Institutional Review Board, and in compliance with the Declaration of Helsinki, a prospective randomized controlled trial was conducted from January 2013 to June 2014, involving 56 patients diagnosed with shoulder impingement syndrome with mild stiffness (ClinicalTrials ID: NCT06051370). Impingement syndrome was diagnosed based on a positive Hawkin's sign and radiographic findings (rotator cuff with intact continuity but tendinosis confirmed by magnetic resonance imaging (MRI) or ultrasound, with a possible SA enthesophyte) [8]. "Mild" stiffness was defined in this study as the degree of that permits daily activity but often causes endpoint range-of-motion pain [9]. It was specified as meeting two or more of the following criteria in both passive and active shoulder ROM: abduction between 110° and 150°, forward elevation (FE) between 120° and 140°, external rotation at the side (ER) between 30° and 50°, and internal rotation at 90° of abduction (IR) between 30° and 50°.

Patients were excluded from the study if they (1) refused to undergo ultrasound-guided injection, (2) were diagnosed with a rotator cuff tear, calcific tendinosis, or biceps pathology, (3) had a history of operation, fracture, or nerve injury of the shoulder, or (4) received treatment apart from the protocol conducted during this study. A final number of 51 patients was enrolled in the trial and randomly assigned to either the GH ultrasound-guided injection group (GH group) or the SA ultrasound-guided injection group (SA group). Double-blinded randomization was performed by an independent nurse using a computer-generated random sequence. A musculoskeletal radiologist (MSH) with more than 20 years of experience performed diagnostic ultrasound and MRI interpretations. A shoulder specialist (JTH) with more than 10 years of experience performing ultrasound-guided injections. A blinded orthopedic resident and nurse carried out the physical examination and clinical scoring. After the final follow-up, 48 patients (24 in each group) were eligible for analysis (Fig. 1).

### Treatment and Follow-up Protocol

A diagnostic ultrasound was first performed using a 5- to 12-MHz linear probe (Philips Healthcare) to rule out shoulder pathology other than impingement syndrome. Using a 21-gauge spinal needle, a solution of 1 mL triamcinolone, 4 mL 1% lidocaine, and 7 mL 0.9% normal saline was injected under ultrasound guidance using 5- to 13-MHz linear probe (GE Healthcare) into either the GH space through the posterior approach or the SA space through the anterolateral approach (Fig. 2) [10]. The patients were then observed in 3, 7, and 13 weeks after the injection. Oral aceclofenac 100 mg twice daily and omeprazole

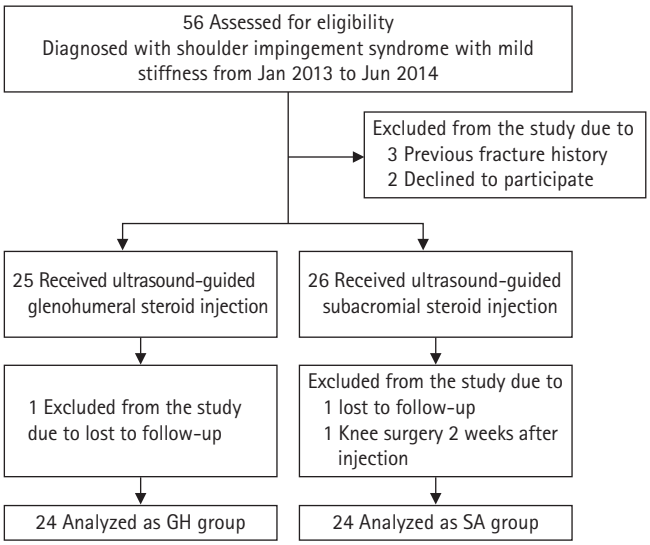


**Fig. 1.** Flow Consolidated Standards of Reporting Trials (CONSORT) diagram of patient enrollment. GH group: ultrasound-guided glenohumeral steroid injection, SA group: ultrasound-guided subacromial steroid injection.

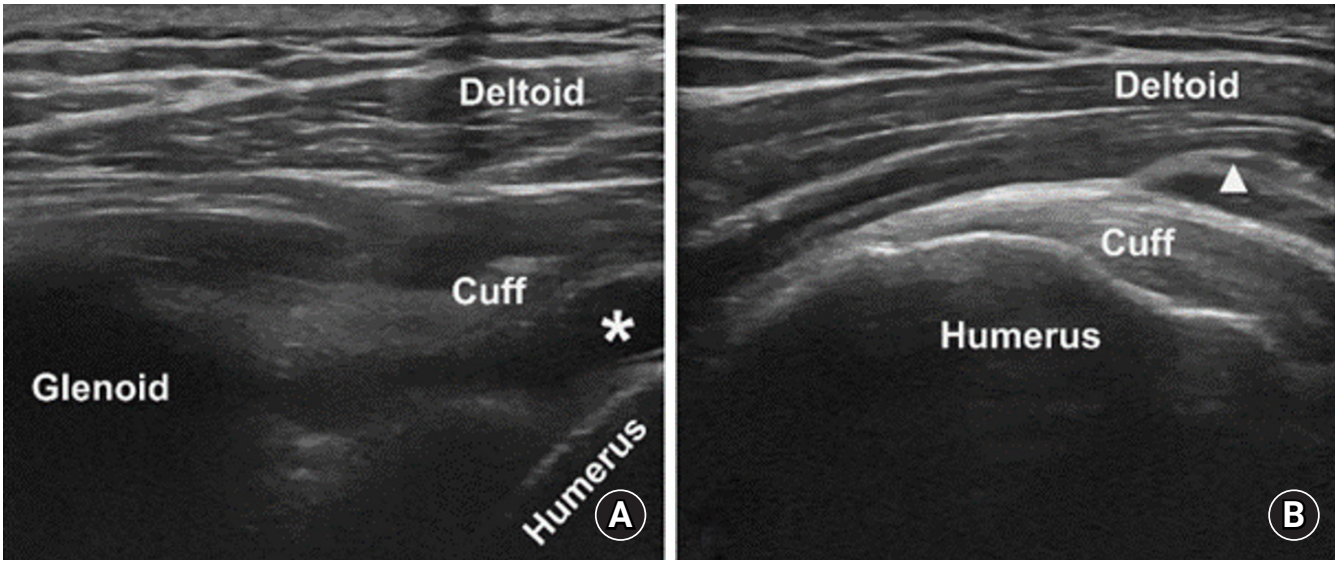


**Fig. 2.** Ultrasound-guided steroid injection. (A) Glenohumeral injection. The needle was introduced intra-articularly through a posterior approach. The injection solution as marked by the asterisk (*) is visualized between the cuff/capsule and the humeral head. (B) Subacromial injection. The needle is introduced through an anterolateral approach between the deltoid and the rotator cuff. Bulging of the subacromial bursa during injection as indicated by the triangle (▲) is demonstrated.

20 mg once daily were prescribed during the follow-up. Stretching exercises in all ranges of motion commenced in the 3rd week. Using a wand, patients were instructed to passively stretch their shoulders to an endpoint where pain is felt and maintain that position for at least 30 seconds, five sessions a day, 5 minutes per session. Rubber-band strengthening was added in the 7th week, with a concentration on ER. Using a rubber band (Thera-band, Hygienic Corp.) tied into a loop, the patients were instructed to maintain maximum painless external rotation for 30 seconds, five sessions a day, 5 minutes per session. The tension of the rubber band was based on the patients' ability to maintain painless maximum rotation for 30 seconds.

### Clinical Assessment and Data Collection

Patient information, including age, sex, duration of symptoms, affected side, and hand dominance, was recorded. The following assessments were performed at baseline and at follow-up visits in weeks 3, 7, and 13: ROM in FE, ER, and IR, pain visual analog scale (pVAS), American Shoulder and Elbow Surgeons (ASES) score, and the Constant-Murley (Constant) score. The ASES score was chosen because it has been verified as best reflecting the activities of daily life [11], while strength was evaluated through the Constant score [12] Improvement in ROM was calculated by subtracting the pre-injection measurements from the measurements at each follow-up visit.

### Statistical Analysis

A power analysis determined that a sample size of 42 patients (21 per group) would be sufficient to have an 80% statistical power to detect a significant difference in the improvement of the Constant score between pre-injection and 7-week post-injection, with a two-sided $\alpha$ level of 0.05. An effect size of 0.89 was assumed based on the mean difference and standard deviation of improvement in the Constant score between pre-injection and 7-week post-injection in a pilot study of 20 patients.

Normal distribution was checked using the Kolmogorov-Smirnov test. The independent-samples t-test or the Mann-Whitney U-test were used to analyze continuous data, while the paired-sample t-test was used for an intra-group comparison of serial measurements. Categorical data were analyzed using Pearson's chi-square test. Continuous data were described as mean ± standard deviation, and categorical data were described as a percentage. Analyses were performed using IBM SPSS ver. 25 (IBM Corp.), and a P-value below 0.05 was considered statistically significant.

## RESULTS

The demographic data and pre-injection baseline clinical evaluation results were comparable between the two groups (Table 1). Significant improvement in ROM and clinical scores were observed within both groups from pre-injection to the final 13-


https://doi.org/10.5397/cise.2023.00346

**Table 1.** Demographic and pre-injection data: intergroup analysis

| Variable | GH group (n = 24) | SA group (n = 24) | P-value |
|---|---|---|---|
| Age (yr) | 52.1 ± 7.5 | 51.4 ± 12.7 | 0.992 |
| Symptom duration (mo) | 16.3 ± 48.1 | 16.2 ± 36.0 | 0.612 |
| Sex (male:female) | 7:17 | 9:15 | 0.540 |
| Laterality (right:left) | 10:14 | 15:9 | 0.149 |
| Hand dominance | 12 (50.0) | 11 (45.8) | 0.773 |
| Pre-injection | | | |
| FE ROM (°) | 127.5 ± 7.4 | 129.2 ± 8.3 | 0.494 |
| ER at side ROM (°) | 53.8 ± 13.1 | 54.6 ± 10.8 | 0.934 |
| IR at 90° ROM (°) | 45.4 ± 7.2 | 48.8 ± 9.0 | 0.303 |
| pVAS score | 6.3 ± 2.0 | 6.0 ± 1.2 | 0.240 |
| ASES score | 46.1 ± 18.4 | 53.0 ± 8.9 | 0.106 |
| Constant score | 55.9 ± 7.9 | 59.2 ± 7.6 | 0.149 |

Values are presented as mean ± standard deviation or number (%). GH group: ultrasound-guided glenohumeral steroid injection, SA group: ultrasound-guided subacromial steroid injection.
FE: forward elevation, ROM: range of motion, ER: external rotation at side, IR: internal rotation at 90° of abduction, pVAS: pain visual analog scale, ASES: American Shoulder and Elbow Surgeons, Constant: Constant-Murley.

**Table 2.** Pre-injection vs. final follow-up in 13 weeks: intragroup analysis

| Variable | Pre-injection (n = 24) | Final follow-up (n = 24) | P-value* |
|---|---|---|---|
| GH group (n = 24) | | | |
| FE ROM (°) | 127.5 ± 7.4 | 148.8 ± 3.4 | < 0.001 |
| ER at side ROM (°) | 53.8 ± 13.1 | 76.9 ± 13.0 | < 0.001 |
| IR at 90° ROM (°) | 45.4 ± 7.2 | 75.0 ± 11.5 | < 0.001 |
| pVAS score | 6.3 ± 2.0 | 2.6 ± 2.1 | < 0.001 |
| ASES score | 46.1 ± 18.4 | 74.5 ± 19.0 | < 0.001 |
| Constant score | 55.9 ± 7.9 | 67.2 ± 8.8 | < 0.001 |
| SA group (n = 24) | | | |
| FE ROM (°) | 129.2 ± 8.3 | 148.3 ± 3.8 | < 0.001 |
| ER at side ROM (°) | 54.6 ± 10.8 | 76.5 ± 8.0 | < 0.001 |
| IR at 90° ROM (°) | 48.8 ± 9.0 | 74.4 ± 8.9 | < 0.001 |
| pVAS score | 6.0 ± 1.2 | 2.6 ± 1.5 | < 0.001 |
| ASES score | 53.0 ± 8.9 | 77.1 ± 12.9 | < 0.001 |
| Constant score | 59.2 ± 7.6 | 68.7 ± 9.9 | < 0.001 |

Values are presented as mean ± standard deviation. GH group: ultrasound-guided glenohumeral steroid injection, SA group: ultrasound-guided subacromial steroid injection.
FE: forward elevation, ROM: range of motion, ER: external rotation at side, IR: internal rotation at 90° of abduction, pVAS: pain visual analog scale, ASES: American Shoulder and Elbow Surgeons, Constant: Constant-Murley.
*P-value < 0.05.

week follow-up (Table 2). Generally, an early improvement of ROM was observed in the GH group in 3 weeks (Table 3).

Both groups exhibited significant improvement in ROM, pain, and clinical scores from pre-injection to the final follow-up at 13 weeks (Table 2). However, the GH group demonstrated an earlier gain of FE, ER, and IR ROM in 3 weeks ($P < 0.001$, $P = 0.012$, and $P = 0.002$) and of ER and the Constant score in 7 weeks ($P < 0.001$ and $P = 0.046$) compared to the SA group (Table 3, Fig. 3). Nevertheless, the improvements between the two groups were similar in subsequent follow-ups (Table 3, Fig. 3)

## DISCUSSION

The SA space has traditionally been the preferred injection site for treating impingement syndrome [8]. However, in cases of mild stiffness, the current study suggests that GH injections may lead to an earlier improvement than the SA approach, within 7 weeks post-injection. Overall, injection targeting the GH joint resulted in a general earlier gain of ROM. Contrary to common perception, there was no significant advantage of SA injections over GH injections in terms of reducing pain. Nonetheless, both injection groups demonstrated a significant improvement in

**Table 3.** Comparison of the amount of improvement from pre-injection: intergroup analysis

| GH vs. SA group | P-value | | | | | |
|---|---|---|---|---|---|---|
| | ΔFE ROM | ΔER ROM | ΔIR ROM | ΔpVAS | ΔASES | ΔConstant |
| 3 wk–Pre | < 0.001* | 0.012* | 0.002* | 0.637 | 0.768 | 0.078 |
| 7 wk–Pre | 0.082 | 0.112 | < 0.001* | 0.730 | 0.558 | 0.046* |
| 13 wk–Pre | 0.288 | 0.402 | 0.129 | 0.333 | 0.366 | 0.228 |

GH group: ultrasound-guided glenohumeral steroid injection, SA group: ultrasound-guided subacromial steroid injection. Δ: amount of improvement = follow-up measurement subtracted by the pre-injection (Pre) measurement.
FE: forward elevation, ROM: range of motion, ER: external rotation at side, IR: internal rotation at 90° of abduction, pVAS: pain visual analog scale, ASES: American Shoulder and Elbow Surgeons, Constant: Constant-Murley.
*P-value < 0.05.

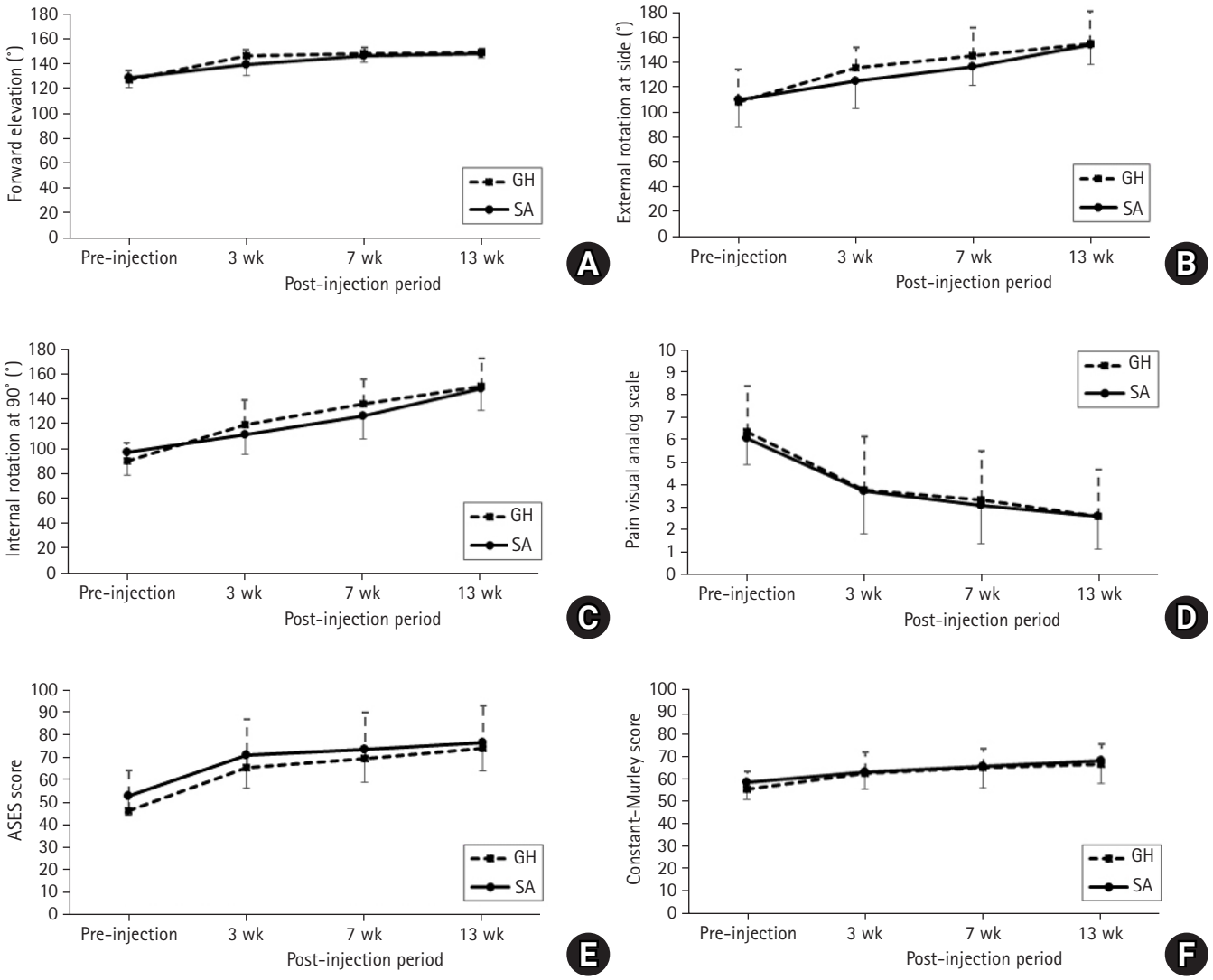


**Fig. 3.** Serial measurements from pre-injection to last follow-up. (A) Forward elevation. (B) External rotation at side. (C) Internal rotation at 90° of shoulder abduction. (D) Pain visual analog scale. (E) American Shoulder and Elbow Surgeons (ASES) score. (F) Constant-Murley score. GH group: ultrasound-guided glenohumeral steroid injection, SA group: ultrasound-guided subacromial steroid injection.


https://doi.org/10.5397/cise.2023.00346

symptoms, with no discernible difference between the two groups after 13 weeks.

Various studies have examined the accuracy of SA and GH injections. A direct comparison of the two techniques was conducted by Eustace et al. [6]. In their study, the injections were performed without ultrasound guidance. Nevertheless, the accuracy of the SA injections was 29%, whereas that of the GH injections was 42%. The results demonstrated that the GH injections had a higher success rate, which was associated with better clinical outcomes.

The accuracy of SA injections is often questioned and has been intensively investigated. Precise, isolated infiltration of the SA bursa is difficult as the bursa is normally collapsed into a thin layer [13]. Moreover, in pathologic scenarios, adhesion and thickening of the walls are common [14]. Several studies have reported success rates for SA injections ranging from 69% to 83%. However, within these successful cases, 46%–75% have also infiltrated other structures, including the subcutaneous layer, deltoid, rotator cuff, and GH joint [10,15-17].

The GH joint consists of an "actual" space between two directly articulating bones with a joint capsule surrounding the joint cavity. The interval between the round humeral head and the relatively flat upper glenoid is readily available for injection with a reliable "loss-of-resistance" to aid in precise needle placement [18]. Unlike SA injections, in which even a successful procedure may cause direct contact with the steroid to the posterosuperior rotator cuff, in GH injections, the superior capsule covers the underside of the rotator cuff, and its non-dependent position away from gravity dispersion may minimize direct steroid-to-tendon infiltration [19]. Not limited to an established treatment of primary shoulder stiffness, the safety and efficacy of postoperative GH steroid injections to treat pain and stiffness after rotator cuff repair have been repeatedly reported [20,21].

The preferred technique needs to be identified. An ideal injection site for steroids would be the first choice, where the success rate is higher in placing the intended injection. The second choice would be the technique whereby the deleterious effects of the steroids can be minimized. In this aspect, the current study showed there is no reason to insist on traditional SA injections for the treatment of impingement syndrome, especially when there is concomitant stiffness.

This study had some limitation. First, the follow-up rate was short, spanning approximately 3 months. Long-term follow-up may permit further comparison regarding the incidence of a subsequent injection or even a rotator cuff tear. However, as this was an outpatient investigation based on conservative treatment for a relatively mild disease state, 3 months of evaluation may have been sufficient to reveal meaningful results, as they were for other studies regarding injection treatments [5,22]. Second, as this was an outpatient-based study, patient compliance and the effect of oral anti- inflammatory medication may have been confounding factors. Nonetheless, the same amount of oral medication was prescribed, and patient instruction on adhering to the treatment protocol was conducted throughout the study. Therefore, the difference in outcomes could be predominantly attributed to the only independent variable—the injection method. Another study limitation was its relatively small sample size. Although some statistically significant findings were derived, a follow-up study with a greater number of participants, and perhaps with a third arm of sham injection, may be needed. Despite these limitations, this study was the first to elucidate an infrequently discussed but relatively common disease entity observed in everyday practice.

## CONCLUSIONS

GH injections may be preferable to SA injections for the treatment of impingement syndrome with mild stiffness, notably in gaining ROM in the early period. However, the two procedures showed similar outcomes regarding pain, ROM, and clinical scores after 3 months.

## NOTES

### ORCID

| | |
|---|---|
| Yong-Tae Kim | https://orcid.org/0000-0003-2996-9969 |
| Tae-Yeong Kim | https://orcid.org/0000-0001-6384-1438 |
| Jun-Beom Lee | https://orcid.org/0009-0006-9845-8651 |
| Jung-Taek Hwang | https://orcid.org/0000-0003-4189-084X |

### Author contributions

Conceptualization: JTH. Data curation: TYK. Formal analysis: YTK, TYK. Supervision: JTH. Validation: YTK. Writing–original draft: YTK, TYK. Writing–review & editing: JBL.

### Conflict of interest

Jung-Taek Hwang is an editorial board member of the journal but was not involved in the peer reviewer selection, evaluation, or decision process of this article. No other potential conflicts of interest relevant to this article were reported.

### Funding

None.

**Data availability**

Contact the corresponding author for data availability.

**Acknowledgments**

The authors would like to thank Myung Sun Hong, MD, a musculoskeletal radiologist with 20 years of experience working at Hallym University Chuncheon Sacred Heart Hospital, for performing the diagnostic ultrasound and magnetic resonance imaging interpretations.

## REFERENCES

1. Papadonikolakis A, McKenna M, Warme W, Martin BI, Matsen FA. Published evidence relevant to the diagnosis of impingement syndrome of the shoulder. J Bone Joint Surg Am 2011;93:1827–32.
2. Koester MC, George MS, Kuhn JE. Shoulder impingement syndrome. Am J Med 2005;118:452–5.
3. Windt DA van der, Koes BW, de Jong BA, Bouter LM. Shoulder disorders in general practice: incidence, patient characteristics, and management. Ann Rheum Dis 1995;54:959.
4. Sun Y, Chen J, Li H, Jiang J, Chen S. Steroid injection and nonsteroidal anti-inflammatory agents for shoulder pain. Medicine (Baltimore) 2015;94:e2216.
5. Oh JH, Oh CH, Choi JA, Kim SH, Kim JH, Yoon JP. Comparison of glenohumeral and subacromial steroid injection in primary frozen shoulder: a prospective, randomized short-term comparison study. J Shoulder Elbow Surg 2011;20:1034–40.
6. Eustace JA, Brophy DP, Gibney RP, Bresnihan B, FitzGerald O. Comparison of the accuracy of steroid placement with clinical outcome in patients with shoulder symptoms. Ann Rheum Dis 1997;56:59.
7. Shin SJ, Lee SY. Efficacies of corticosteroid injection at different sites of the shoulder for the treatment of adhesive capsulitis. J Shoulder Elbow Surg 2013;22:521–7.
8. Harrison AK, Flatow EL. Subacromial impingement syndrome. J Am Acad Orthop Surg 2011;19:701–8.
9. Namdari S, Yagnik G, Ebaugh DD, et al. Defining functional shoulder range of motion for activities of daily living. J Shoulder Elbow Surg 2012;21:1177–83.
10. Mathews PV, Glousman RE. Accuracy of subacromial injection: anterolateral versus posterior approach. J Shoulder Elbow Surg 2005;14:145–8.
11. Wright RW, Baumgarten KM. Shoulder outcomes measures. J Am Acad Orthop Surg 2010;18:436–44.
12. Constant CR, Murley AG. A clinical method of functional assessment of the shoulder. Clin Orthop Relat Res 1987;214:160–4.
13. Jacobson JA. Shoulder US: anatomy, technique, and scanning pitfalls. Radiology 2011;260:6–16.
14. Matsuzaki S, Yoneda M, Kobayashi Y, Fukushima S, Wakitani S. Dynamic enhanced MRI of the subacromial bursa: correlation with arthroscopic and histological findings. Skeletal Radiol 2003;32:510–20.
15. Yamakado K. The targeting accuracy of subacromial injection to the shoulder: an arthrographic evaluation. Arthroscopy 2002;18:887–91.
16. Partington PF, Broome GH. Diagnostic injection around the shoulder: hit and miss? A cadaveric study of injection accuracy. J Shoulder Elbow Surg 1998;7:147–50.
17. Henkus HE, Cobben LP, Coerkamp EG, Nelissen RG, Arkel ER van. The accuracy of subacromial injections: a prospective randomized magnetic resonance imaging study. Arthroscopy 2006;22:277–82.
18. Sethi PM, Attrache NE. Accuracy of intra-articular injection of the glenohumeral joint: a cadaveric study. Orthopedics 2006;29:149–52.
19. Nimura A, Kato A, Yamaguchi K, et al. The superior capsule of the shoulder joint complements the insertion of the rotator cuff. J Shoulder Elbow Surg 2012;21:867–72.
20. Kim IB, Jung DW. An intra-articular steroid injection at 6 weeks postoperatively for shoulder stiffness after arthroscopic rotator cuff repair does not affect repair integrity. Am J Sports Med 2018;46:2192–202.
21. Kim YS, Jin HK, Lee HJ, Cho HL, Lee WS, Jang HJ. Is it safe to inject corticosteroids into the glenohumeral joint after arthroscopic rotator cuff repair. Am J Sports Med 2019;47:1694–700.
22. Kim YB, Lee WS, Won JS. The effects of a single-dose subacromial injection of a nonsteroidal anti-inflammatory drug in geriatric patients with subacromial impingement syndrome: a randomized double-blind study. Clin Shoulder Elbow 2021;24:4–8.



https://doi.org/10.5397/cise.2023.00346

Original Article

Clin Shoulder Elbow 2023;26(4):397-405
https://doi.org/10.5397/cise.2023.00339

CiSE
Clinics in Shoulder and Elbow

eISSN 2288-8721

# Plate prebending using a three-dimensional–printed model affords effective anatomical reduction in clavicular shaft fractures

**Hyungsuk Kim, Younsung Jung, Hyun Seok Song**

*Department of Orthopedic Surgery, Eunpyeong St. Mary's Hospital, College of Medicine, The Catholic University of Korea, Seoul, Korea*

**Background:** A precontoured plate rarely fits properly within the patient's clavicle and must be bent intraoperatively. This study aimed to determine whether anatomical reduction could be achieved using a plate bent before surgery.
**Methods:** This study included 87 consecutive patients with displaced mid-shaft clavicle fractures who underwent plate fixation and were followed-up for a minimum of 1 year. After exclusions, 39 consecutive patients underwent fixation with a precontoured plate bent intraoperatively (intraoperative bending group), and 28 underwent fixation with the plate bent preoperatively (preoperative bending group). Using free software and a three-dimensional (3D) printer, ipsilateral clavicle 3D-printed models were constructed. Using plain radiographs, the distance between the edge of the lateral inferior cortex and the medial inferior cortex was measured. The angle between the line connecting the inferior cortex edge and the line passing through the flat portion of the superior cortex of the distal clavicle was measured.
**Results:** Mean length differences between the ipsilateral and contralateral clavicle were smaller on both anteroposterior (AP; P=0.032) and axial images (P=0.029) in the preoperative bending group. The mean angular differences on both AP (P=0.045) and axial images (P=0.008) were smaller in the preoperative bending group. No significant differences were observed between the two groups in functional scores at the last follow-up.
**Conclusions:** Smaller differences in length and angle between the ipsilateral and contralateral clavicle, indicative of reduction, were observed in the preoperative bending group. Using the precontoured technique with low expense, the operation was performed more effectively as reflected by a shorter operation time.
**Level of evidence:** III.

**Keywords:** Clavicle; Fracture reduction; Plate; Three-dimensional printing

## INTRODUCTION

Clavicle fracture is a common type of upper limb facture, accounting for 2.6%–4% of all adult fractures and 35% of shoulder girdle injuries [1]. In adults, 69%–82% of these fractures occur in the mid-shaft, and significant displacement is reported in 73% of all mid-shaft clavicle fractures [1]. Despite the high prevalence of fracture and displacement, clavicle fractures have traditionally been managed without surgical treatment on the basis of early reports suggesting that non-union and malunion are rare outcomes [2]. However, there are several studies reporting higher non-union rates with conservative treatment, ranging from 7%

Received: May 3, 2023 Revised: June 27, 2023 Accepted: July 9, 2023
Correspondence to: Hyun Seok Song
Department of Orthopedic Surgery, Eunpyeong St. Mary's Hospital, College of Medicine, The Catholic University of Korea, 1021 Tongil-ro, Eunpyeong-gu, Seoul 03312, Korea
Tel: +82-2-2030-4628, Fax: +82-2-2030-4629, E-mail: hssongmd@hanmail.net, ORCID: https://orcid.org/0000-0002-7844-2293

Copyright© 2023 Korean Shoulder and Elbow Society.
This is an Open Access article distributed under the terms of the Creative Commons Attribution Non-Commercial License (http://creativecommons.org/licenses/by-nc/4.0/) which permits unrestricted non-commercial use, distribution, and reproduction in any medium, provided the original work is properly cited.

to 15% [3-5]. Furthermore, fracture union is commonly achieved with some degree of angulation and/or shortening. Related clinical findings after non-surgical treatment include limited range of motion, disappointing cosmetic outcomes, and residual pain [3,6]. Thus, surgical treatment for displaced clavicle fractures is increasingly performed in clinical practice [4,7].

The human clavicle has a distinct double-curved, S-shaped three-dimensional (3D) structure and shows considerable variation in terms of length, diameter, and degree of bowing [8]. Current surgical treatments include interfragmentary screw fixation, cerclage wiring, intramedullary fixation, and plate fixation [4,9-12]. Although there have been reports of reasonable results with intramedullary fixation [13,14], plate fixation is preferred in patients with displaced comminuted fractures because interposed soft tissues can impair fracture reduction [10,15]. Furthermore, plate fixation allows firm fixation via cortical bone compression and promotes resistance against rotational torque. A systematic review by Zlowodzki et al [9] demonstrated that plate fixation reduced the non-union rate for acute mid-shaft clavicle fractures to 2.2%, compared with 15.1% for conservative treatment.

There are several commercially available precontoured anatomical plates. These plates are designed to fit the natural shape of the clavicle. Precontoured plates were originally introduced to shorten the operation time as they eliminate the need for intraoperative plate contouring. However, the precontoured plate frequently fails to fit properly within the patient's clavicle and must be bent intraoperatively by the surgeon.

Most assessments of clavicle fracture treatments are based on the union rate and clinical results. To our knowledge, no studies on patients with clavicle fractures have assessed the extent of anatomical reduction compared with the pre-injured state. Clavicular shortening greater than 2 cm has been used as a marker of poor clinical outcome, but this finding is controversial [3,16].

This study was performed to determine whether anatomical reduction could be achieved using a plate bent before surgery. We hypothesized that the use of pre-bent plates would result in smaller differences between the ipsilateral and contralateral clavicle, promoting more effective anatomical reduction and shorter operation times.

# METHODS

The study protocol was approved by the Institutional Review Board of Eunpyeong St. Mary's Hospital (No. PC20RISI0021), which waived the requirement for informed consent due to the retrospective design. Approval was granted to "Comparison of the anatomical plate using 3D printer" (No. PIRB-20200305-005) on March 5, 2020.

## Patient Enrollment

The study included 87 consecutive patients with closed displaced mid-shaft clavicle fractures who underwent open reduction and internal fixation with similar products at a university hospital between January 2015 and October 2019. Plate bending was performed intraoperatively when contour mismatch was observed after reduction. After excluding 14 patients in whom plate bending was not performed intraoperatively or preoperatively, 73 patients were included. Forty-one consecutive patients underwent fixation with a precontoured plate bent intraoperatively (intraoperative bending group), and 32 consecutive patients underwent fixation with a precontoured plate bent preoperatively (preoperative bending group). After excluding two and four patients, respectively, with a less than 1-year follow-up, the final sample sizes were 39 patients in the intraoperative bending group and 28 patients in the preoperative bending group (Fig. 1). All surgeries were performed at one university hospital by the senior author. The exclusion criteria were open fracture, age younger than 17 years, previous history of fracture of the ipsilateral clavicle or shoulder, and injury of the ipsilateral side.

Demographic information is shown in Table 1. The mean patient age was 49.6 ± 16.1 years (range, 18–76 years) in the intraoperative bending group and 53.1 ± 19.7 years (range, 18–80 years) in the preoperative bending group (P = 0.444). The Robinson classification, which is considered essential for treatment selection and prognostic assessment of mid-shaft clavicle fractures [17,18], was used to categorize patients by fracture pattern. No statistically significant difference in the Robinson classification was found between two groups (P = 0.139). One patient had a zy-

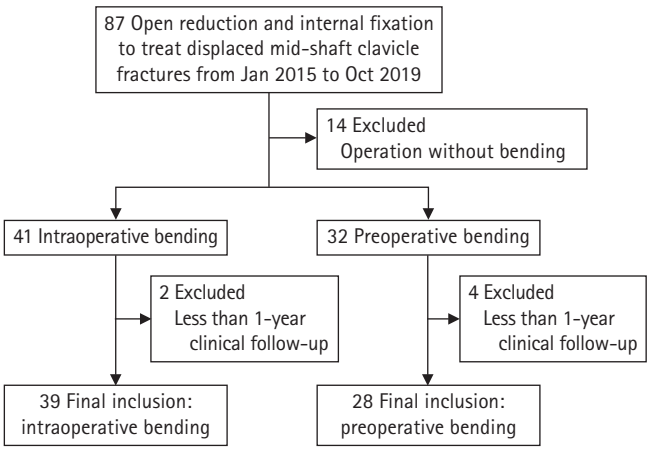


**Fig. 1.** Study flow diagram.


https://doi.org/10.5397/cise.2023.00339

**Table 1.** Patient demographic data

| Variable | Intraoperative bending group (n = 39) | Preoperative bending group (n = 28) | P-value |
|---|---|---|---|
| Age (yr) | 49.6 ± 16.1 (18–76) | 53.1 ± 19.7 (18–80) | 0.444 |
| Follow-up duration (mo) | 17.3 ± 7.3 (12–36) | 14.4 ± 6.1 (12–42) | 0.018 |
| Sex | | | 0.180 |
| Male | 35 | 21 | |
| Female | 4 | 7 | |
| Affected side | | | 0.310 |
| Right | 16 | 15 | |
| Left | 23 | 13 | |
| Robinson classification [18] | | | 0.139 |
| 2A2 | 4 | 4 | |
| 2B1 | 3 | 4 | |
| 2B2 | 26 | 19 | |
| 3B1 | 4 | 1 | |
| 3B2 | 2 | 0 | |

Values are presented as mean ± standard deviation (range).

gomatic fracture, and another had scapula and glenoid fractures on the contralateral side. The mean follow-up duration was 17.3 ± 7.3 months (range, 12–36 months) in the intraoperative bending group and 14.4 ± 6.1 months (range, 12–42 months) in the preoperative bending group. The follow-up duration was longer in the intraoperative bending group (P = 0.018).

## Preoperative Bending of the Plate Using a 3D-Printed Model

To obtain images of the un-injured contralateral clavicle, computed tomography (CT) scans of both sides were obtained in all patients. CT axial images of both clavicles, in digital imaging and communications in medicine (DICOM) format, were obtained from the picture archiving and communication system (PACS). Free open source software, ITK SNAP (https://www.itksnap.org, ver 3.4.0), was used to reconstruct un-injured contralateral CT axial images into 3D structural images [19]. This software allowed the authors to delineate 3D anatomical structures of clavicular cortical bone. Semi-automatic segmentation was performed with this software using active contour methods. Manual segmentation was performed for thin cortical bone areas when semi-automatic segmentation was insufficient (Fig. 2).

The constructed 3D contralateral clavicle images were converted to ipsilateral clavicle images using the mirroring function in the free open source software Meshmixer (https://www.meshmixer.com, ver 3.0) (Fig. 3). Clavicular models were constructed with a fused deposition modeling type 3D printer (da Vinci 2.0A, XYZ Printing) using acrylonitrile-butadiene-styrene filaments. Each model could be printed with less than 2 U.S. dollar (USD) of filament.

For each 3D-printed clavicular model, a precontoured plate (Modular Clavicle Plate System, Synthes) was mounted on the superior aspect of the model in the best-fit position. Bending of the plate was performed to match the contour of the 3D-printed model (Fig. 4). Pre-bent plates were sterilized prior to surgery.

## Surgical Procedures

Each patient underwent general anesthesia and was placed in the supine position. A transverse skin incision was made over the fracture site, and soft tissue dissection was meticulously performed. After the fracture pattern had been identified, reduction was performed. In patients with comminution, interfragmentary or cerclage wiring was performed to reduce comminuted fracture fragments before placement of the plate. Reduction forceps or towel clips were occasionally used for temporary reduction maintenance. Precontoured plates (Modular Clavicle Plate System, Synthes) were used for all patients.

In the intraoperative bending group, additional plate bending was performed to match the clavicular contour. In the preoperative bending group, the pre-bent plate was mounted and fixed under the image intensifier. In both groups, a Velpeau sling was applied for 4 weeks postoperatively. Early mobilization of hand and elbow joints was initiated if the pain was tolerable. Patients were permitted to resume their normal daily activities at 6 weeks postoperatively.

## Radiological Assessment

Both clavicular anteroposterior (AP) and axial images were obtained immediately after the operation. The ipsilateral and contralateral lengths of the clavicle were measured in both AP and

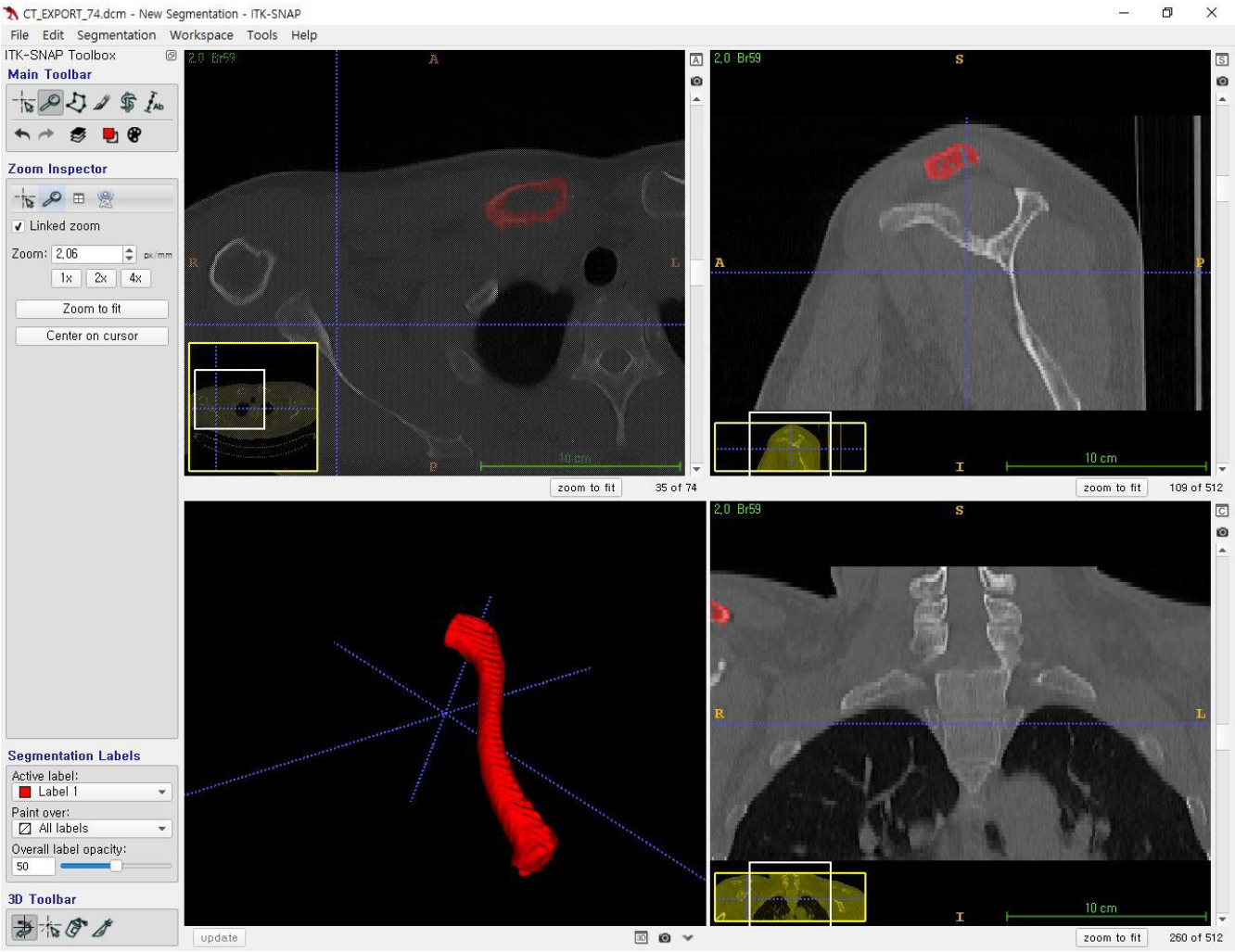


**Fig. 2.** Reconstruction of computed tomography (CT) axial images to three-dimensional structural images using ITK snap (version 3.4.0).

axial images. The length was measured between the edge of the lateral inferior cortex and the medial inferior cortex (Fig. 5). The clavicular angle was also measured. Specifically, the angle between the line connecting the inferior cortex edge and the line passing through the flat portion of the distal clavicular superior cortex was measured on AP images. The angle between the line passing through the flat portions of the medial and distal clavicle was measured on axial images (Fig. 6).

Length and angular differences between ipsilateral and contralateral clavicles were calculated by subtracting the ipsilateral values from contralateral values. Absolute differences were compared between the two groups. All measurements were performed independently by two orthopedic surgeons who were blinded to patient information during the measurement process (HK and HSS). Measurements were performed twice by each investigator, with a 4-week interval between measurements. Intraobserver and interobserver reliability were analyzed using intraclass correlation coefficient.

## Clinical Assessment

Operation times were compared between the two groups. Serial plain radiographs were collected during follow-up visits. Fracture union times and union rates were compared between the two groups. Complications were also analyzed in both groups. Nonunion was defined as a radiologically visible fracture gap at six months postoperatively. Implant failure was defined as screw loosening or implant breakage without evidence of bone healing. At the last follow-up visit, functional outcomes were compared using the American Shoulder and Elbow Surgeons and Constant scoring systems.


https://doi.org/10.5397/cise.2023.00339

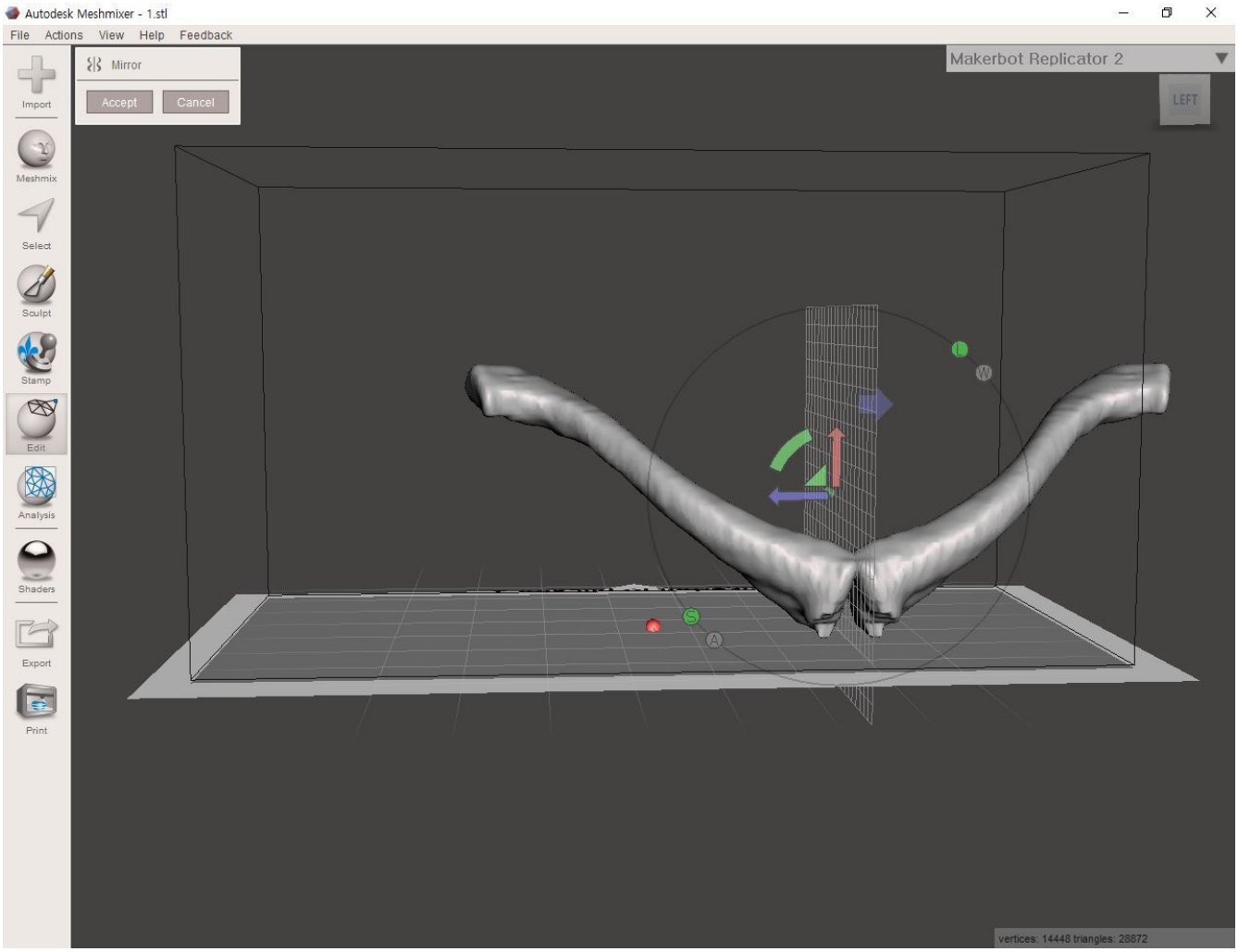


**Fig. 3.** Mirroring function of Meshmixer (version 3.0) used for inversion of the contralateral clavicle.

### Statistical Analysis

Statistical analyses were performed using IBM SPSS statistics ver. 24.0 (IBM Corp.). Student t-test was used for comparison of radiological and clinical data between the two groups. Pearson's chi-square test, Fisher's exact test, and the linear by linear association test were used to compare demographic characteristics between the two groups. Mean, standard deviation, and standard error of the mean values were calculated for all variables. Statistical significance was set at $P < 0.05$.

## RESULTS

### Radiological Assessment

The mean length difference between the ipsilateral and contralateral clavicles was smaller on both AP and axial images in the preoperative bending group. The mean length difference measured on AP images was 7.9 ± 4.8 mm in the intraoperative bending group and 5.8 ± 3.0 mm in the preoperative bending group ($P = 0.032$). The mean length difference measured on axial images was 8.2 ± 5.6 mm in the intraoperative bending group and 5.3 ± 4.3 mm in the preoperative bending group ($P = 0.029$).

The mean angular difference between the ipsilateral and contralateral clavicle, on both AP and axial images, was smaller in the preoperative bending group. The mean angular difference measured on AP images was 4.6° ± 3.2° in the intraoperative bending group and 3.2° ± 2.1° in the preoperative bending group ($P = 0.045$). The mean angular difference on axial image was 8.1° ± 6.9° in the intraoperative bending group and 4.7° ± 2.9° in the preoperative bending group ($P = 0.008$).

The intraclass correlation coefficients were 0.987 ($P < 0.001$) and 0.968 ($P < 0.001$) for the length measurements on AP and axial images, respectively. The values were 0.911 ($P < 0.001$) and

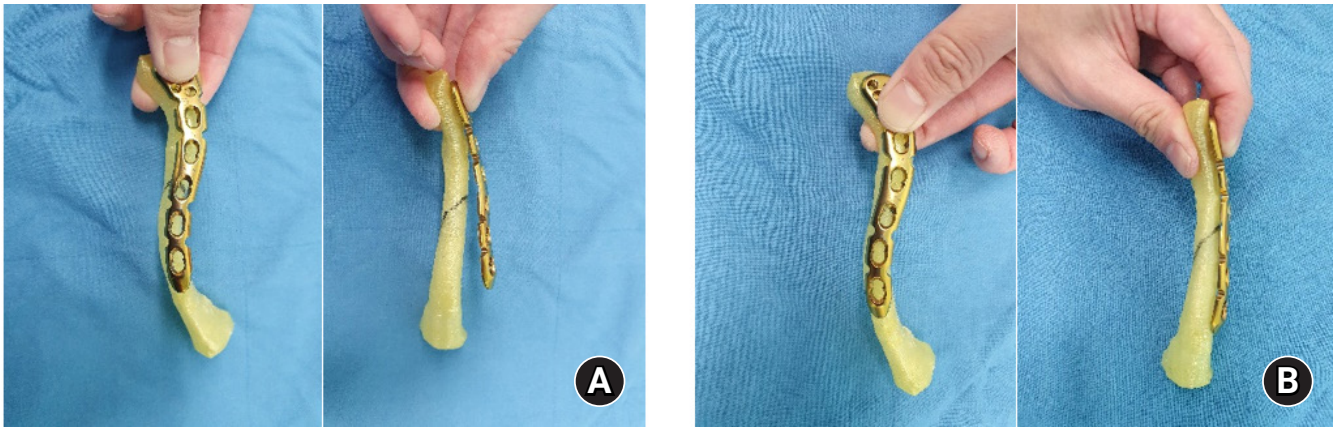


**Fig. 4.** Preoperative plate bending to match the contours of the three-dimensional–printed model and plate (Synthes). A fracture line is drawn on the model. (A) Before bending (superior view and anterior view). (B) After bending (superior view and anterior view).

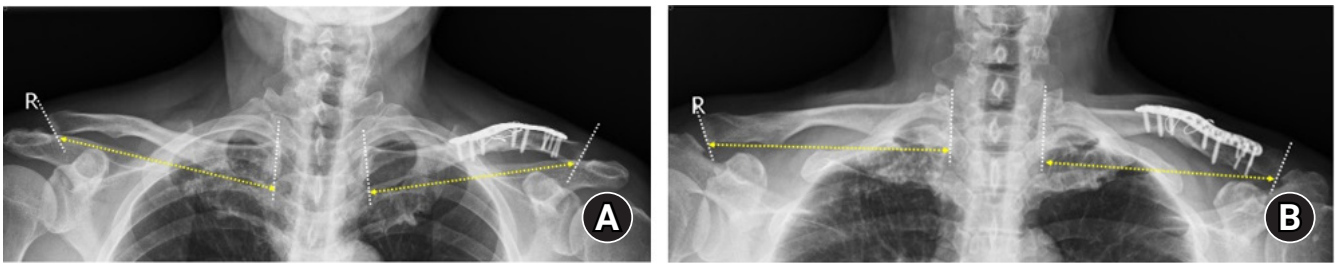


**Fig. 5.** Length measurement methods. The distance between the edge of the lateral inferior cortex and the medial inferior cortex (yellow dotted line with arrows) was measured on both (A) anteroposterior and (B) axial plain radiographs. The lateral and medial border is marked with white dotted lines.

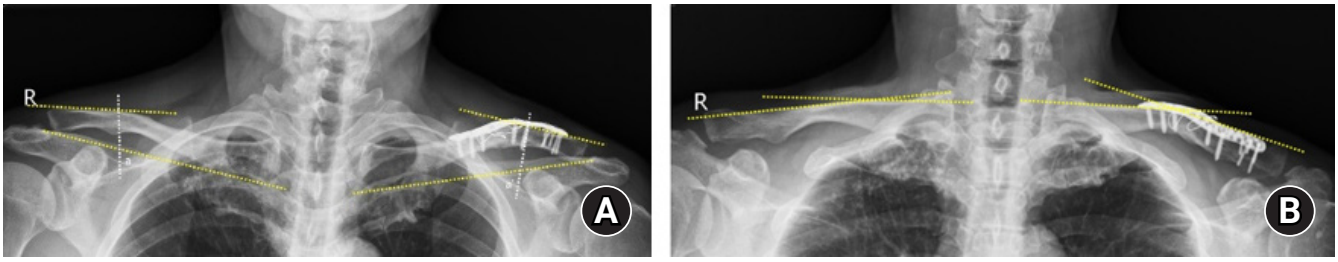


**Fig. 6.** Angular measurement methods. (A) On anteroposterior images, the angle between the line connecting the inferior cortex edge and the line passing through the flat portion of the distal clavicular superior cortex was measured. (B) On axial images, the angle was measured between the line passing through the flat portion of the medial and distal clavicle.

0.961 ($P<0.001$) for angulation measurements on AP and axial images, respectively.

### Clinical Assessment

The operation time was 85.6 minutes in the intraoperative bending group and 69.7 minutes in the preoperative bending group ($P<0.001$) (Table 2). One patient in the preoperative bending group exhibited delayed union. In the intraoperative bending group, one non-union, one delayed union, and two cases of screw loosening were observed. Time to union was shorter in the preoperative bending group ($P=0.005$). No significant difference was observed between the two groups in terms of functional scores at the last follow-up (Table 2).

## DISCUSSION

When plates were pre-bent on 3D-printed models constructed using CT images of the contralateral side of the clavicle, anatomi-


https://doi.org/10.5397/cise.2023.00339

**Table 2.** Clinical assessment results

| Variable | Intraoperative bending group (n = 39) | Preoperative bending group (n = 28) | P-value |
|---|---|---|---|
| Operation time (min) | 85.6 ± 17.3 | 69.7 ± 12.8 | < 0.001 |
| Union rate (%) | 97.4 (38 patients) | 100 (28 patients) | 1.000 |
| Union time (mo) | 5.7 ± 2.5 | 4.3 ± 1.6 | 0.005 |
| Complication | | | |
| Non-union | 1 (2.6) | 0 | 1.000 |
| Delayed union | 1 (2.6) | 1 (3.6) | 1.000 |
| Screw loosening | 2 (5.1) | 0 | 0.506 |
| Functional score | | | |
| ASES | 90.0 ± 8.8 | 90.6 ± 8.9 | 0.773 |
| Constant | 90.0 ± 7.1 | 90.5 ± 8.5 | 0.820 |

Values are presented as mean ± standard deviation or number (%) unless otherwise indicated.
ASES: American Shoulder and Elbow Surgeons.

cal reduction was achieved in terms of both clavicle length and angulation, which led to a shorter operation time. Surgical treatment for clavicular fractures includes interfragmentary screw fixation, cerclage wiring, intramedullary fixation, and plate fixation [20]. Leroux et al. [21] reported a revision surgery rate of 24.6%, with a non-union rate of 2.6% and malunion rate of 1.1%, among 1,350 patients who had undergone open reduction and internal fixation. Other reported complications include infection, hardware failures (e.g., plate breakage or screw pull-out), and hypertrophic scarring. Underlying neurovascular structures may also be at risk during plate fixation [22].

Most studies on clavicular fractures have been aimed at achieving fracture union, which is important for management. However, previous studies of clavicular fractures have focused on the quality of reduction and functional restoration to the preinjury state rather than anatomical reduction. Hill et al. [3] reported that the likelihood of non-union or symptomatic malunion was higher with shortening of 2 cm or more. Non-union rates of approximately 20% have been reported in patients with comminuted fractures [23,24]. van der Meijden et al. [4] proposed surgical indications including younger age, high activity level, shortening of 1.5–2 cm with or without comminution, and significant cosmetic deformity or multiple traumas.

To our knowledge, no reports have described the parameters used for assessment of clavicular fracture reduction. Therefore, we suggest that the length and angle measurements used in this study be employed (Fig. 5). Notably, operation time was shorter when using the prebending technique. Despite the commercial availability of precontoured locking plates, variations in clavicle length and angulation among individuals often lead to poorly fitting plates. Additional intraoperative bending is often necessary to match the contour and reduce the fracture gap. By prebending the plate using a 3D-printed model constructed based on the contralateral side of the clavicle, we avoided the need for additional bending of the plate during surgery. In the intraoperative bending group, more time was needed to match the contour of the plate to the temporarily fixed fracture.

Moreover, intraoperative bending did not guarantee anatomical reduction. In the absence of wide dissection, the inferior cortex could not be observed. This could complicate restoration of the clavicular angle and cause gaps in inferior fracture sites, promoting delayed union or non-union. Although there were no significant differences in complications between the two groups in this study, fewer complications may be expected with prebending of the clavicular plate due to the shorter operation time and reduced intraoperative manipulation.

This study had some limitations. First, anatomical reduction was analyzed relative to the contralateral side. Hoogervorst et al. [25] reported the potential for error when measuring the length of both clavicles side-to-side on thoracic CT. Those researchers reported that approximately 32% of patients showed asymmetry of 5 mm or more, with an absolute length difference of 3.74 mm. In that study, only length was measured on single 3D reconstructed thoracic CT images. However, the 3D position of the clavicle could cause errors in clavicular length measurements. In our study, we assessed length differences on both AP and axial images, as well as angulation on plain radiographs. Some studies have reported within-patient variation between the right and left clavicles [26-28]. We believed that the contralateral clavicle would be the most suitable reference during plate preparation. Second, the measurement methods used to assess anatomical reduction in this study have not been validated by other clinicians. Third, the plain radiographs in this study were analyzed retrospectively. Therefore, there may have been differences in methods among the technicians collecting the radiographs. Fourth, we did not determine the degree to which anatomical differences

might have affected the clinical results. Notably, we found no reports discussing whether malunion affects functional outcomes. Last, this retrospective comparative study included a relatively small number of patients. However, the post hoc power was calculated to be 98.7%, with an alpha value of 0.05.

This is the first study to assess anatomical reduction relative to the contralateral side in patients with clavicular fractures.

We propose a method for analyzing plain radiographs in terms of anatomical reduction in clavicular fractures. Furthermore, using free software and an entry-level 3D-printer, ipsilateral clavicle 3D-printed models were constructed. Each model could be printed with less than 2 USD of filament.

## CONCLUSIONS

Smaller differences in length and angle between the ipsilateral and contralateral clavicles were observed in the preoperative bending group, indicative of anatomical reduction. Using the prebending technique with low expense, the operation was performed more effectively as reflected by a shorter operation time.

## NOTES

### ORCID

| | |
|---|---|
| Hyungsuk Kim | https://orcid.org/0000-0003-3400-0263 |
| Younsung Jung | https://orcid.org/0009-0008-3493-203X |
| Hyun Seok Song | https://orcid.org/0000-0002-7844-2293 |

### Author contributions

Conceptualization: HK, HSS. Data curation: HK. Formal analysis: YJ. Investigation: HK. Methodology: HK, YJ, HSS. Resources: YJ. Software: HK. Supervision: HSS. Validation: HK, HSS. Visualization: HK. Writing – original draft: HK, YJ, HSS. Writing – review & editing: HK, HSS.

### Conflict of interest

None.

### Funding

None.

### Data availability

Contact the corresponding author for data availability.

### Acknowledgments

None.

## REFERENCES

1. Khan LA, Bradnock TJ, Scott C, Robinson CM. Fractures of the clavicle. J Bone Joint Surg Am 2009;91:447–60.
2. Canadian Orthopaedic Trauma Society. Nonoperative treatment compared with plate fixation of displaced midshaft clavicular fractures: a multicenter, randomized clinical trial. J Bone Joint Surg Am 2007;89:1–10.
3. Hill JM, McGuire MH, Crosby LA. Closed treatment of displaced middle-third fractures of the clavicle gives poor results. J Bone Joint Surg Br 1997;79:537–9.
4. van der Meijden OA, Gaskill TR, Millett PJ. Treatment of clavicle fractures: current concepts review. J Shoulder Elbow Surg 2012;21:423–9.
5. Song HS, Kim H. Current concepts in the treatment of midshaft clavicle fractures in adults. Clin Shoulder Elb 2021;24:189–98.
6. Robinson CM, Goudie EB, Murray IR, et al. Open reduction and plate fixation versus nonoperative treatment for displaced midshaft clavicular fractures: a multicenter, randomized, controlled trial. J Bone Joint Surg Am 2013;95:1576–84.
7. Kim HY, Yang DS, Bae JH, Cha YH, Lee KW, Choy WS. Clinical and radiological outcomes after various treatments of midshaft clavicle fractures in adolescents. Clin Orthop Surg 2020;12:396–403.
8. Huang JI, Toogood P, Chen MR, Wilber JH, Cooperman DR. Clavicular anatomy and the applicability of precontoured plates. J Bone Joint Surg Am 2007;89:2260–5.
9. Zlowodzki M, Zelle BA, Cole PA, Jeray K, McKee MD; Evidence-Based Orthopaedic Trauma Working Group. Treatment of acute midshaft clavicle fractures: systematic review of 2144 fractures: on behalf of the Evidence-Based Orthopaedic Trauma Working Group. J Orthop Trauma 2005;19:504–7.
10. Narsaria N, Singh AK, Arun GR, Seth RR. Surgical fixation of displaced midshaft clavicle fractures: elastic intramedullary nailing versus precontoured plating. J Orthop Traumatol 2014;15:165–71.
11. Shin WJ, Chung YW, Kim SD, An KY. Additional fixation using a metal plate with bioresorbable screws and wires for robinson type 2B clavicle fracture. Clin Shoulder Elb 2020;23:205–9.
12. Jeong JY, Chun YM. Treatment of acute high-grade acromioclavicular joint dislocation. Clin Shoulder Elb 2020;23:159–65.
13. Andrade-Silva FB, Kojima KE, Joeris A, Santos Silva J, Mattar R Jr. Single, superiorly placed reconstruction plate compared with flexible intramedullary nailing for midshaft clavicular fractures: a prospective, randomized controlled trial. J Bone Joint Surg Am 2015;97:620–6.
14. van der Meijden OA, Houwert RM, Hulsmans M, et al. Opera-


https://doi.org/10.5397/cise.2023.00339

tive treatment of dislocated midshaft clavicular fractures: plate or intramedullary nail fixation?: a randomized controlled trial. J Bone Joint Surg Am 2015;97:613–9.
15. Xu B, Lin Y, Wang Z, et al. Is intramedullary fixation of displaced midshaft clavicle fracture superior to plate fixation?: evidence from a systematic review of discordant meta-analyses. Int J Surg 2017;43:155–62.
16. Wick M, Müller EJ, Kollig E, Muhr G. Midshaft fractures of the clavicle with a shortening of more than 2 cm predispose to nonunion. Arch Orthop Trauma Surg 2001;121:207–11.
17. O'Neill BJ, Hirpara KM, O'Briain D, McGarr C, Kaar TK. Clavicle fractures: a comparison of five classification systems and their relationship to treatment outcomes. Int Orthop 2011;35:909–14.
18. Robinson CM. Fractures of the clavicle in the adult. Epidemiology and classification. J Bone Joint Surg Br 1998;80:476–84.
19. Yushkevich PA, Piven J, Hazlett HC, et al. User-guided 3D active contour segmentation of anatomical structures: significantly improved efficiency and reliability. Neuroimage 2006;31:1116–28.
20. Kim DW, Kim DH, Kim BS, Cho CH. Current concepts for classification and treatment of distal clavicle fractures. Clin Orthop Surg 2020;12:135–44.
21. Leroux T, Wasserstein D, Henry P, et al. Rate of and risk factors for reoperations after open reduction and internal fixation of midshaft clavicle fractures: a population-based study in Ontario, Canada. J Bone Joint Surg Am 2014;96:1119–25.
22. Collinge C, Devinney S, Herscovici D, DiPasquale T, Sanders R. Anterior-inferior plate fixation of middle-third fractures and nonunions of the clavicle. J Orthop Trauma 2006;20:680–6.
23. Jørgensen A, Troelsen A, Ban I. Predictors associated with nonunion and symptomatic malunion following non-operative treatment of displaced midshaft clavicle fractures: a systematic review of the literature. Int Orthop 2014;38:2543–9.
24. Robinson CM, Court-Brown CM, McQueen MM, Wakefield AE. Estimating the risk of nonunion following nonoperative treatment of a clavicular fracture. J Bone Joint Surg Am 2004;86:1359–65.
25. Hoogervorst P, Appalsamy A, Franken S, van Kampen A, Hannink G. Quantifying shortening of the fractured clavicle assuming clavicular symmetry is unreliable. Arch Orthop Trauma Surg 2018;138:803–7.
26. Abdel Fatah EE, Shirley NR, Mahfouz MR, Auerbach BM. A three-dimensional analysis of bilateral directional asymmetry in the human clavicle. Am J Phys Anthropol 2012;149:547–59.
27. Bernat A, Huysmans T, Van Glabbeek F, Sijbers J, Gielen J, Van Tongel A. The anatomy of the clavicle: a three-dimensional cadaveric study. Clin Anat 2014;27:712–23.
28. Daruwalla ZJ, Courtis P, Fitzpatrick C, Fitzpatrick D, Mullett H. Anatomic variation of the clavicle: a novel three-dimensional study. Clin Anat 2010;23:199–209.

Original Article

Clin Shoulder Elbow 2023;26(4):406-415
https://doi.org/10.5397/cise.2022.01445

CiSE
Clinics in Shoulder and Elbow

eISSN 2288-8721

# Radiologic and clinical outcomes of an arthroscopic bridging graft for irreparable rotator cuff tears with a modified Mason-Allen stitch using a plantaris tendon autograft: a case series with minimum 2-year outcomes

**Hyun-Gyu Seok, Sam-Guk Park**

*Department of Orthopedic Surgery, Yeungnam University Medical Center, Daegu, Korea*

**Background:** Surgical management of a massive rotator cuff tear (RCT) is always challenging. This study describes the clinical and radiological outcomes of patients who underwent bridging grafts using a plantaris tendon for an irreparable RCT.
**Methods:** Thirteen patients with a massive RCT were treated with arthroscopic interposition of a folded plantaris tendon autograft between June 2017 and January 2020. For clinical evaluation, a visual analog scale (VAS), American Shoulder and Elbow Surgeons (ASES) score, Disabilities of the Arm, Shoulder, and Hand (DASH) score, Constant-Murley score, and range of motion values were collected. For radiographic evaluation, standardized magnetic resonance imaging and ultrasonography were performed to check the integrity of the interposed tendon.
**Results:** A statistically significant improvement at the final follow-up was evident in scores for the VAS (−3.0, P=0.003), ASES (24.9, P=0.002), D ASH (−20.6, P=0.001), and Constant-Murley values (14.2, P=0.010). In addition, significant improvement was shown in postoperative flexion (17.3°, P=0.026) and external rotation (27.7°, P<0.001). In postoperative radiologic evaluations, the interposed tendons were intact at the last examination in 12 of the 13 patients. No complications related to donor sites were reported.
**Conclusions:** An arthroscopic bridging graft for irreparable RCTs using a modified Mason-Allen stitch and a plantaris autograft resulted in improved short-term radiological and clinical outcomes. Graft integrity was maintained for up to 2 years in most patients.
**Level of evidence:** IV.

**Keywords:** Autograft; Plantaris muscle; Rotator cuff tear

## INTRODUCTION

Surgical treatment of a massive rotator cuff tear (RCT) is always a challenge for orthopedic surgeons [1]. Irreparable RCTs are characterized by a lack of mobility, which precludes complete repair of native rotator-cuff tendons on the footprint [2]. Poor tissue quality of a retracted rotator cuff precludes mechanically sufficient repair, and unavoidable tension may predispose the tissue to repair failure [3]. Conventional techniques for soft-tissue release are often insufficient for tension-free repair, and the failure risk may increase if excessive tension is applied during the repair process [4-6]. Several treatment options, such as rotator-cuff augmentation with allografts, biceps rerouting, tendon transfer, and reverse total-shoulder arthroplasty have been proposed to

Received: December 20, 2022 Revised: April 13, 2023 Accepted: April 15, 2023
Correspondence to: Sam-Guk Park
Department of Orthopedic Surgery, Yeungnam University Medical Center, Yeungnam University College of Medicine, 170 Hyeonchung-ro, Nam-gu, Daegu 42415, Korea
Tel: +82-53-620-36400, Fax: +82-53-628-4020, E-mail: radiorth@ynu.ac.kr, ORCID: https://orcid.org/0000-0002-1135-5179

Copyright© 2023 Korean Shoulder and Elbow Society.
This is an Open Access article distributed under the terms of the Creative Commons Attribution Non-Commercial License (http://creativecommons.org/licenses/by-nc/4.0/) which permits unrestricted non-commercial use, distribution, and reproduction in any medium, provided the original work is properly cited.

deal with these consequences of an irreparable RCT [2,7-12]. A superior capsular reconstruction technique introduced by Mihata et al. [13] has been widely performed and clinical outcomes have been reported. However, the technique suffers from a long operative duration, donor-site morbidity, and technical difficulties [14]. Biceps rerouting cannot be used in cases of a completely torn long head of the biceps tendon [14]. Another viable option may be a bridge graft that spans the residual stump of the rotator cuff and tuberous bone [11,15-17]. This configuration is typically used to decrease repair tensions for irreparable RCTs [15,16].

Several systematic reviews have reported that the bridging procedure may provide superior tendon healing, although the clinical outcomes of the bridging grafts were not significantly better than those of patch augmentation [15-17]. Another systematic review reported that a bridging graft merely closes a defect with no possibility of restoring the muscle-tendon unit's length-tension relationships. The graft would serve as a primary load-bearing structure between the rotator cuff and the humerus [16]. Although the biocompatibility of artificial grafts and xenografts that can be used for patch augmentation is spreading with technological advances, these materials run the risk of causing inflammatory reactions and potentially resorbing over time [18]. A modified Mason-Allen stitch can hypothetically fix a long tendon autograft securely to the rotator-cuff tissue, and the other side of the tendon may be robustly anchored to the humeral bone with Bio-Tenodesis screws. Various tendons were considered for the autograft, but plantaris, which can be harvested without changing the lateral position for arthroscopy, is relatively easy to harvest, and is an effective choice for passing the rotator cuff, was judged to be the most suitable. This study reports the clinical and radiological outcomes of patients who underwent bridging grafts with a long tendon graft for an irreparable RCT.

## METHODS

This study was approved by the Institutional Review Board of Yeungnam University Hospital (No. YUMC 2019-05-017). The requirement for informed consent was waived because of its retrospective and observational nature. All methods were carried out in accordance with national guidelines and regulations. We performed a retrospective study of a case series of irreparable RCT repairs performed by a single surgeon (SGP) from June 2017 to January 2020 using arthroscopic bridging graft procedures and a postoperative rehabilitation protocol.

An arthroscopic bridging graft with a modified Mason-Allen stitch using a tendon autograft was indicated for patients diagnosed with an irreparable RCT. The findings of preoperative magnetic resonance imaging (MRI) had to be consistent with an irreparable RCT, with a full-thickness medial retraction greater than 5 cm, grade 3 or greater fatty infiltration of the su-

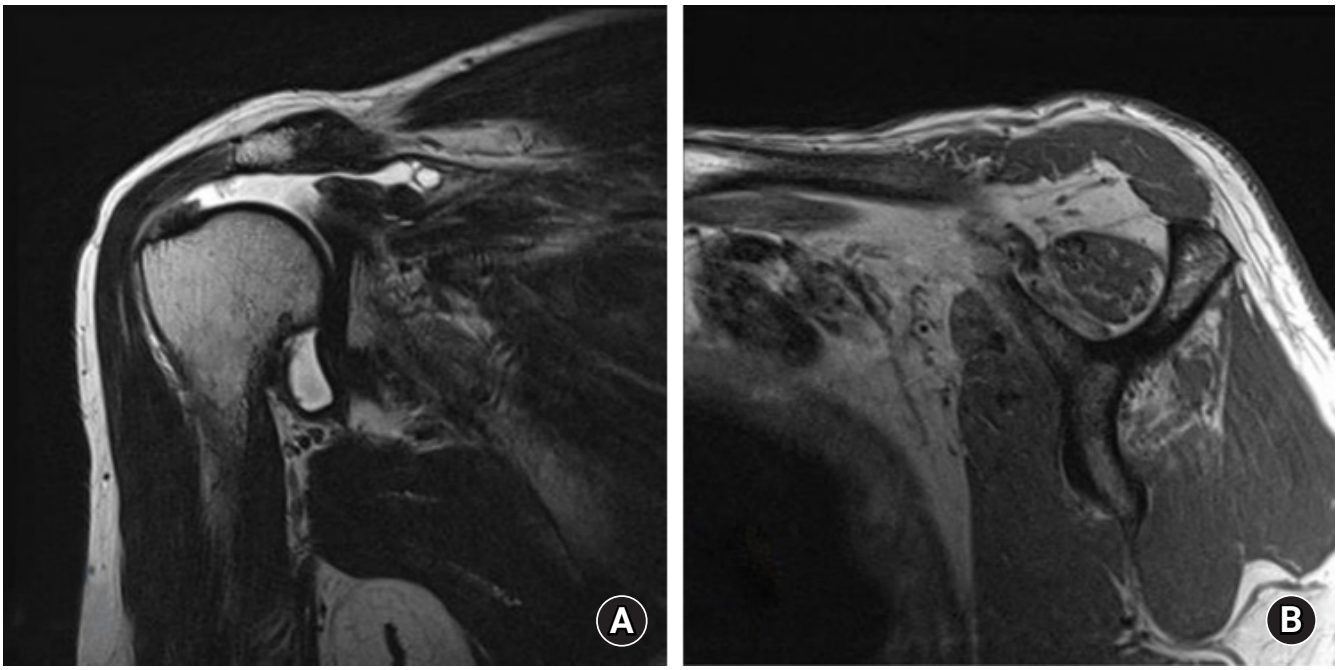


**Fig. 1.** An magnetic resonance imaging (MRI) taken before the surgery. (A) In a coronal view of preoperative MRI, the size of tear retraction is measured in T2-weighted images. (B) In a sagittal view of preoperative MRI, the degree of fatty infiltration in the supraspinatus and infraspinatus muscles is measured in most sagittal image.

praspinatus, and grade 2 or greater change of the infraspinatus on T2-weighted sagittal oblique imaging (Fig. 1) [1]. During diagnostic arthroscopy, the irreparability of the tears was confirmed by the inability of the torn edge of the rotator cuff to attach to the medial margin of the footprint with less than 30 N of tension after maximum mobilization [5]. All surgeries were performed by one surgeon (SGP), who also measured the tension.

Exclusion criteria included glenohumeral arthritis or inflammatory arthropathy based on preoperative radiographs and/or MRI, a rotator cuff that was reducible to the medial footprint under appropriate tension, a RCT with complete subscapularis tendon tear (Lafosse types IV and V) [19], and incomplete follow-up data or MRI evaluation. A total of 13 patients met the study criteria.

## Operative Technique

The operative technique described in a technical note previously reported by the authors was used in this study [20]: (1) intra-articular and subacromial debridement, (2) plantaris tendon harvesting and graft preparation, (3) plantaris graft fixation, and (4) final repairable rotator-cuff repair. As detailed explanations with videos and figures describing the technique are provided in the technical note, here we focus on describing the plantaris tendon harvesting and the Mason-Allen suture process [20].

### *Plantaris tendon harvesting and graft preparation*

First, the plantaris tendon on the opposite side of the shoulder to be operated on was harvested. After making a 3 cm incision on the skin covering the distal portion of the plantaris tendon, blind subcutaneous dissection was performed until the tendon was reached (Fig. 2A). After the distal insertion of the plantaris tendon was transected, the distal portion of the tendon was prepared for stripping with a No. 2 Ethibond suture (Ethicon) (Fig. 2B). The tendon stripper was advanced slowly and proximally until the muscle-tendon connection was severed and the tendon was retrieved. Approximately 30 cm of the tendon (diameter of approximately 3 mm) was harvested. The tendons were then folded into a Y-shaped graft 15 cm long and the three ends were pre-ligated with Ethibond or FiberWire sutures (Fig. 2C).

### *Mason-Allen suture using plantaris tendon*

After routine bursectomy and preparation of the footprint of the greater tuberosity, a cannulated reamer 6.5 mm in diameter was passed through the portal to drill a hole for Bio-Tenodesis screw and the folded end of the Y-shaped graft. The folded end of the graft was fixed into the hole with SwiveLock (Arthrex) Tenodesis bicomposite anchors (Fig. 3A and B). A BirdBeak suture passer (Arthrex) was inserted along the posterior edge of the irreversible portion of the tear, 5 to 10 mm more proximal than a conventional suture site. First, one limb of the harvested graft was passed through the cuff in the articular-to-bursal direction. The passed limb of the tendon was retrieved through the posterior portal. For the second passage, the BirdBeak passer was reloaded with thread and passed through the cuff 1 cm anterior to the first passage, and the limb retrieved through the posterior portal was passed in the bursal-to-articular direction by the same method. Next, a transverse loop was made in the bursal side of the cuff (Fig. 3C). For the third passage, the passed graft limb should be situated at the articular side of the cuff. After that, the limb can be passed from the articular-to-bursal direction to form a modified Mason-Allen stitch (Fig. 3D) [9]. A lateral pilot hole was made using a punch at a point where no excessive tension was applied to the rotator cuff. The two FiberWire strands threaded to the first limb of the graft were loaded through the Bio-Swive-

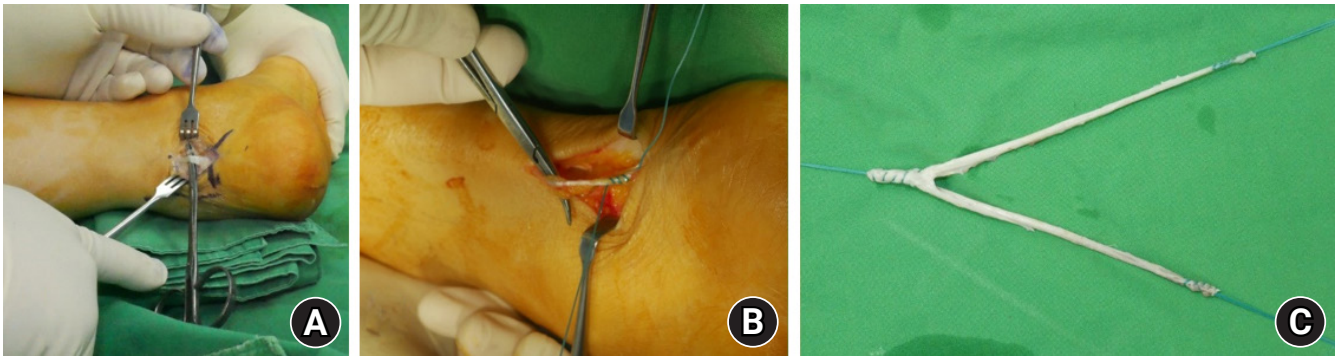


**Fig. 2.** Plantaris tendon harvesting and graft preparation in lateral position. (A) Making a 3-cm incision on the skin covering the distal portion of the plantaris tendon, a blind subcutaneous dissection is performed until the tendon was reached. (B) Distal insertion of the plantaris tendon is transected, the distal portion of the tendon was prepared for stripping with Ethibond. (C) The harvested tendon is folded in a Y-shaped graft, and the three ends are pre-threaded with Ethibond.


https://doi.org/10.5397/cise.2022.01445

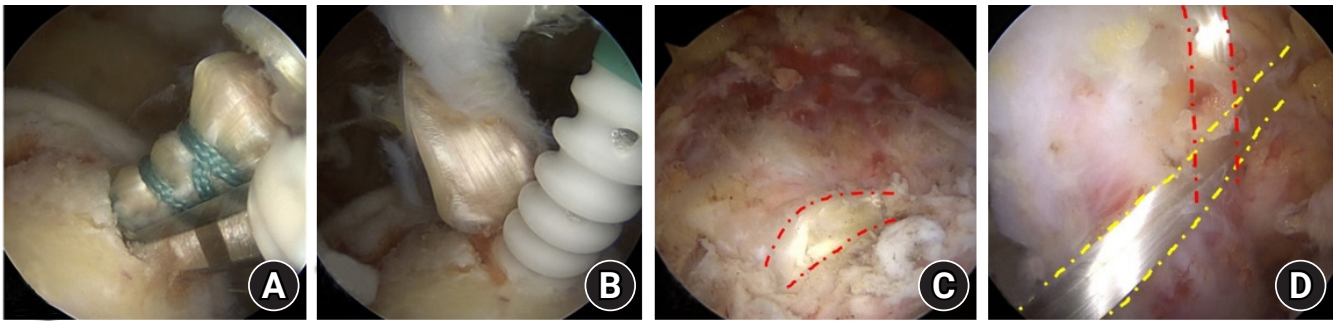


**Fig. 3.** A modified Mason-Allen stitch using a plantaris autograft. The procedure for the right shoulder is performed in a lateral decubitus position. The lateral portal was used as the viewing portal and the anterolateral portal as the working portal. (A, B) The folded end of the graft is engaged in the hole with Swivelock tenodesis bio-composite anchor. (C) One limb of the graft is passed in the articular-to-bursal direction through the rotator cuff and passed through the cuff at 1 cm anterior from the first passage. Transverse loop (red dotted lines) is made on the bursal surface of the cuff. (D) The passed graft limb is re-passed to the bursal side just medial to the transverse loop to complete Mason-Allen stitch (red and yellow dotted lines).

Lock eyelet. The first limb of the graft was then engaged in the desired position. The procedure was repeated with the other graft limb while moving anteriorly to the anterior edge of the irreparable portion of the cuff tear to be grafted.

### Postoperative Rehabilitation

After surgery, the shoulder was immobilized for 6 weeks in a sling with an abduction brace. Only exercises of the elbow, wrist, and hand were allowed for the first 4 weeks. Passive range of motion (ROM) exercises began 4–6 weeks post-surgery, and active training was initiated after 6 weeks. Daily activities, including overhead lifting, were allowed after 12 weeks, with a return to a full range activities after 6 months.

### Clinical and Radiographic Evaluations

Clinical results were evaluated before and after surgery using subjective and objective outcome measures at 12 and 24 months, and at the latest follow-up. The mean follow-up duration was 36.2 months (range, 24–53 months), with a minimum of 2 years. Subjective outcome measures included the visual analog scale (VAS), American Shoulder and Elbow Surgeons (ASES), and Disabilities of the Arm, Shoulder, and Hand (DASH). Objective outcome measures included active ROM, including forward flexion, abduction, external rotation at 90° of shoulder abduction, and Constant-Murley scores. For radiographic evaluation, 11 of the 13 patients underwent standardized MRI examinations (MAGNETOM Tim Trio, Siemens). Due to the presence of coronary stents, the other two underwent ultrasonography before surgery and a minimum of 2 years after surgery. Radiologic evaluations were performed approximately 2 years after surgery. Ultrasound imaging was performed and interpreted by a musculoskeletal radiologist with 20 years of experience. The radiological examinations were reviewed using the Picture Archiving and Communications System (Marosis, Infiniti) in a blinded fashion by two independent physicians; one (JKY) was a musculoskeletal radiologist and the other (HGS) was an orthopedic surgeon with 5 years of experience. The physicians identified both the native rotator-cuff tendon and the graft.

The repairs were classified as "intact," "partially failed," or "failed" based on the number of interposed tendons found in the interval between the torn edge of the remnant rotator-cuff tendon medially and the footprint of the rotator cuff laterally. An "intact" construct was indicated by at least 3 of the 4 interposed tendons remaining in tension in the interval or by tendons that were transformed into the membranous patch with no visible defects at the tendon-graft and graft-bone interfaces (Fig. 4). "Partially failed" was indicated by one or two intact tendons in the interval. "Failed" meant a full-thickness defect with no working interposed tendons attached to the native tendon and humeral footprint. Supraspinatus muscle atrophy and the degree of fatty infiltration in the supraspinatus and infraspinatus muscles were measured in most lateral T2-weighted oblique sagittal images, where the scapular spine was in contact with the scapular body (the "Y-view").

Supraspinatus atrophy was divided into three grades based on MRI quantitative evaluation of the occupation ratio (R) described by Rulewicz et al. [21] (grade I, $1 > R \geq 0.6$; grade II, $0.6 > R \geq 0.4$; and grade III, $R < 0.4$). The degree of fatty infiltration was categorized as a Goutallier index modified to use MRI by Lippe et al. [22].

### Statistical Analyses

Statistical analyses were conducted using IBM SPSS ver. 23.0 (IBM Corp.). Paired t-tests were used to compare the preopera-

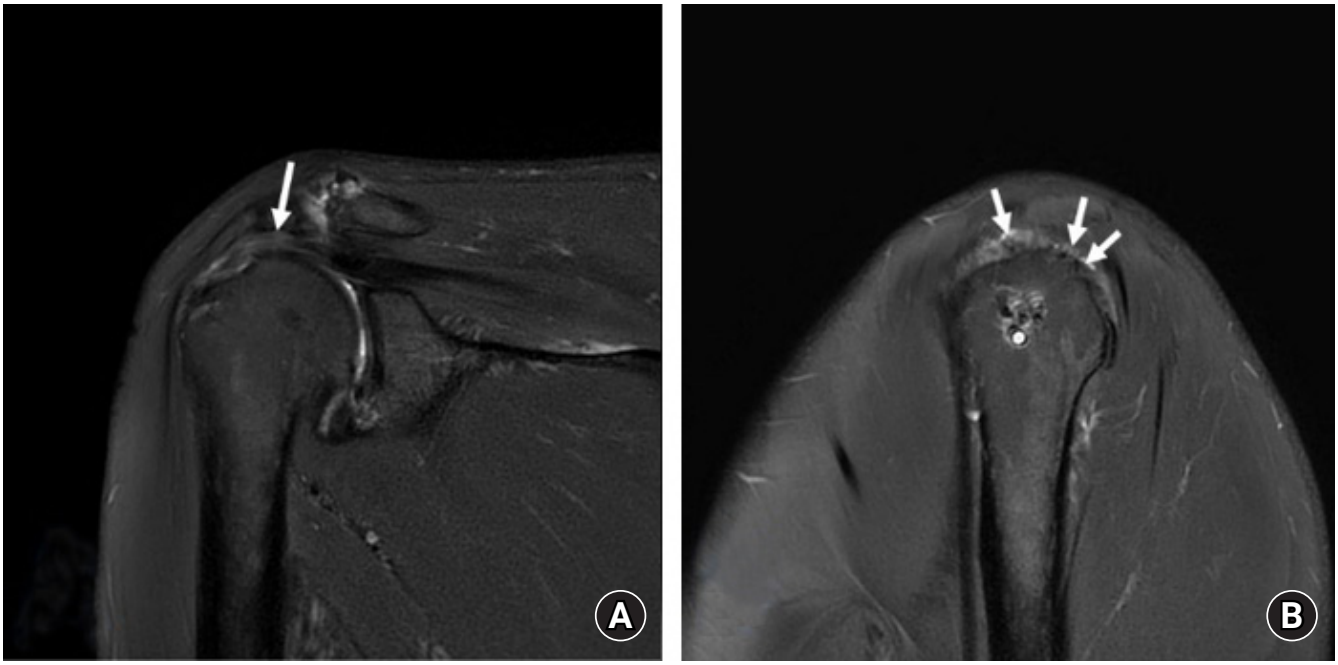


**Fig. 4.** An magnetic resonance imaging (MRI) scan taken after surgery to check the integrity of the interposed tendon. (A) In coronal view of postoperative MRI, tendons are transformed into the membranous patch, with no visible defects at the tendon-graft, and graft-bone interfaces (white arrow). (B) In a sagittal view of postoperative MRI, three of the four interposed tendons remain tensioned in the interval (white arrows). Those are evaluated as "intact."

tive and postoperative clinical scores. P-values $<0.05$ were considered statistically significant.

## RESULTS

The mean age of the patients was 68.5 years (range, 58–79 years). The mean tear size was 44.1 mm × 44.5 mm (i.e., the medial-to-lateral defect times the anterior to posterior distance described by Davidson et al. [23]. In 12 of the 13 patients, the biceps tendons were ruptured and difficult to find. A tenotomy was performed in one patient with an intact tendon of the biceps brachii. A summary of the demographic characteristics and preoperative evaluations is provided in Table 1.

Statistically significant improvements were seen in all measured functional scores at the final follow-up: VAS (4.9 ± 1.8 to 1.9 ± 1.7, P = 0.003), Constant-Murley score (60.2 ± 19.0 to 74.5 ± 9.1, P = 0.01), ASES (57.8 ± 17.1 to 82.7 ± 11.5, P = 0.002), and DASH scores (32.9 ± 15.6 to 12.3 ± 7.4, P = 0.001). Forward flexion (132.3° ± 44.2° to 149.6° ± 30.7°, P = 0.003), abduction (121.5° ± 45.4° to 145.8° ± 25.2°, P = 0.009), internal rotation (68.5° ± 20.8° to 75° ± 12.2°, P = 0.325), and external rotation (50.4° ± 17.5° to 78.1° ± 17.5°, P < 0.001) were also improved post-surgery compared with the preoperative range. However, there was a statistically significant difference only in the forward flexion and external rotation measurements. Table 2 lists the improvement in clinical outcomes at final follow-up.

MRI or ultrasonography was performed 2 years after surgery to verify the integrity of each graft; the interposed tendons were intact in 12 of the 13 patients. Only one patient had a partial failure of the interposed tendons. The patient with a partial failure was satisfied at their last clinical follow-up because their motion limitation and pain were significantly relieved. No harvest-site morbidity was reported in any patients. Table 3 lists the radiological and clinical outcomes at the final follow-up.

## DISCUSSION

This case series of 13 consecutive patients who underwent arthroscopic bridging graft for irreparable RCT with a modified Mason-Allen stitch and a tendon autograft showed positive clinical and radiological outcomes. Of the 13 patients, only one (7.7%) experienced failure, in a case that was evaluated as "partially failed." On follow-up MRI of the patient with partial failure, one of four strands of imposed tendon rupture was confirmed, but the clinical outcome was relatively positive. For this patient, ultrasonography was used to monitor the progression of the partial rupture at every outpatient follow-up visit, but the rupture did not progress, and the patient was satisfied with the clinical


https://doi.org/10.5397/cise.2022.01445

**Table 1.** Demographic characteristics and preoperative evaluation

| Patient no. | Sex | Age (yr) | FU (mo) | Biceps tendon | Preoperative MRI | | | | | | | Preoperative clinical score | | | | | | | | |
|---|---|---|---|---|---|---|---|---|---|---|---|---|---|---|---|---|---|---|---|---|
| | | | | | Tear size (mm) | | SST | | IST | | | | | | | | | | | |
| | | | | | AP | ML | Atr | FI | Atr | FI | | Flexion | Abduction | Internal rotation | External rotation | VAS | CS | DASH | ASES |
| 1 | F | 67 | 45 | Ruptured | 43 | 39 | - | - | - | - | | 125 | 105 | 80 | 20 | 8 | 44 | 45.7 | 33.32 |
| 2 | F | 69 | 53 | Ruptured | 42 | 45 | - | - | - | - | | 50 | 95 | 45 | 40 | 6 | 35 | 45 | 46.67 |
| 3 | M | 72 | 47 | Ruptured | 41 | 47 | 3 | 2 | 2 | 3 | | 140 | 115 | 80 | 55 | 5 | 60 | 28.4 | 56.66 |
| 4 | M | 67 | 42 | Ruptured | 50 | 39 | 3 | 3 | 2 | 3 | | 140 | 110 | 70 | 55 | 5 | 60 | 25.8 | 63.32 |
| 5 | M | 64 | 41 | Intact | 43 | 47 | 3 | 3 | 2 | 2 | | 150 | 160 | 85 | 60 | 8 | 65 | 49.2 | 41.66 |
| 6 | F | 76 | 38 | Ruptured | 39 | 38 | 3 | 2 | 2 | 3 | | 165 | 160 | 75 | 55 | 4 | 76 | 36.2 | 60.00 |
| 7 | F | 66 | 35 | Ruptured | 37 | 38 | 2 | 2 | 3 | 4 | | 170 | 165 | 80 | 60 | 2 | 74 | 12.9 | 86.66 |
| 8 | F | 77 | 35 | Ruptured | 45 | 47 | 3 | 2 | 1 | 2 | | 120 | 130 | 80 | 45 | 5 | 53 | 42.2 | 53.32 |
| 9 | M | 58 | 34 | Ruptured | 51 | 50 | 3 | 2 | 1 | 2 | | 170 | 165 | 85 | 60 | 2 | 86 | 1.7 | 88.33 |
| 10 | M | 58 | 33 | Ruptured | 42 | 42 | 3 | 2 | 1 | 2 | | 140 | 60 | 45 | 55 | 4 | 67 | 42.2 | 61.65 |
| 11 | M | 79 | 29 | Ruptured | 46 | 49 | 3 | 3 | 3 | 4 | | 30 | 15 | 15 | 10 | 6 | 17 | 53.3 | 33.20 |
| 12 | M | 65 | 26 | Ruptured | 49 | 46 | 2 | 1 | 2 | 3 | | 155 | 150 | 75 | 55 | 4 | 75 | 15.5 | 64.98 |
| 13 | F | 72 | 24 | Ruptured | 42 | 36 | 3 | 2 | 1 | 2 | | 165 | 150 | 75 | 50 | 5 | 71 | 30.2 | 61.64 |

FU: follow-up, MRI: magnetic resonance imaging, SST: supraspinatus, IST: infraspinatus, AP: anteroposterior, ML: mediolateral, Atr: atrophy, FI: fatty infiltration, VAS: visual analog scale, CS: Constant-Murley score, DASH: Disabilities of the Arm, Shoulder, and Hand, ASES: American Shoulder and Elbow Surgeons.

**Table 2.** Clinical outcomes of all the patients (n=13)

| Variable | Preoperative | Postoperative | Improvement: mean difference (P-value) |
|---|---|---|---|
| Flexion (°) | 132.3 ± 44.2 | 149.6 ± 30.7 | 17.3 (0.026) |
| Abduction (°) | 121.5 ± 45.4 | 145.8 ± 25.2 | 24.3 (0.092) |
| Internal rotation (°) | 68.5 ± 20.8 | 75.0 ± 12.2 | 6.5 (0.325) |
| External rotation (°) | 50.4 ± 17.5 | 78.1 ± 17.5 | 27.7 (< 0.001) |
| VAS score | 4.9 ± 1.8 | 1.9 ± 1.7 | −3.0 (0.003) |
| CS score | 60.2 ± 19.0 | 74.5 ± 9.1 | 14.2 (0.010) |
| DASH score | 32.9 ± 15.6 | 12.3 ± 7.4 | −20.6 (0.001) |
| ASES score | 57.8 ± 17.1 | 82.7 ± 11.5 | 24.9 (0.002) |

Values are presented as mean ± standard deviation.
VAS: visual analog scale, CS: Constant-Murley, DASH: Disabilities of the Arm, Shoulder, and Hand, ASES: American Shoulder and Elbow Surgeons.

outcome.

Successful surgical remedies for a massive irreparable RCT continue to present significant clinical challenges. Primary repair of a massive RCT is likely under at least some degree of tension despite releases, and unavoidable tension on the construct may predispose the patient to pain and repair failure [4-6,24]. For a massive RCT in which primary repair is impossible, various procedures such as muscle transfer and superior capsular reconstruction have been devised, but each has its limitations.

Latissimus dorsi muscle transfer in some young patients may improve external rotation. In patients who underwent a latissimus dorsi transfer procedure, functional scores and ROM improved at both the short-term and long-term follow-ups of >9 years on average [25,26]. This finding is similar to the results of our study using a bridging graft. However, latissimus dorsi transfers in patients with a ruptured subscapularis resulted in poor clinical outcomes and a high complication rate [25].

A superior capsular reconstruction technique has been widely reported, but long-term results are not available; issues regarding failure, graft elongation, persistent superior migration of humeral head, and suture anchor loosening are under debate [27-29]. Denard et al. [29], who used superior capsule reconstruction for irreparable RCTs, reported that ASES scores improved from 43.6 to 77.5 and pain decreased from 5.8 to 1.7. They also reported a 6.8% complication rate. ASES scores improved from 56.9 to 82.7, pain decreased from 4.9 to 1.9, and the complication rate was 14.2%.

The biodegradable subacromial balloon is a relatively new option, but long-term follow-up data are lacking [30]. Senekovic et al. [31] reported on 24 patients who had received a subacromial balloon for an irreparable RCT. At 60 months postoperation, 84.62% of the patients showed a clinically significant improve-

**Table 3.** Radiological and clinical outcomes at the final follow-up

| Patient no. | POD (mo) | Final follow-up MRI | | | | | Final follow-up clinical score | | | | | | | |
|---|---|---|---|---|---|---|---|---|---|---|---|---|---|---|
| | | Graft | SST | | IST | | Flexion | Abduction | Internal rotation | External rotation | VAS | CS | DASH | ASES |
| | | | Atr | FI | Atr | FI | | | | | | | | |
| 1 | 33 | Intact (US) | - | - | - | - | 160 | 155 | 75 | 70 | 1 | 77 | 6.9 | 89.99 |
| 2 | 41 | Intact (US) | - | - | - | - | 175 | 170 | 80 | 85 | 3 | 78 | 9.5 | 81.66 |
| 3 | 26 | Partially failed | 2 | 2 | 2 | 3 | 140 | 145 | 80 | 85 | 6 | 67 | 15.5 | 59.98 |
| 4 | 36 | Intact | 3 | 3 | 2 | 3 | 180 | 175 | 85 | 90 | 1 | 82 | 7.8 | 89.99 |
| 5 | 28 | Intact | 3 | 3 | 2 | 2 | 170 | 165 | 80 | 90 | 0 | 85 | 7.8 | 94.99 |
| 6 | 24 | Intact | 3 | 2 | 2 | 3 | 170 | 100 | 50 | 40 | 2 | 63 | 27.6 | 71.66 |
| 7 | 24 | Intact | 2 | 2 | 3 | 4 | 155 | 120 | 50 | 60 | 4 | 71 | 23.3 | 64.97 |
| 8 | 26 | Intact | 3 | 2 | 1 | 2 | 135 | 135 | 80 | 75 | 3 | 69 | 17.2 | 73.31 |
| 9 | 26 | Intact | 3 | 2 | 1 | 2 | 150 | 150 | 85 | 90 | 1 | 82 | 0.9 | 93.33 |
| 10 | 25 | Intact | 3 | 2 | 1 | 1 | 160 | 150 | 80 | 85 | 1 | 80 | 10.0 | 91.66 |
| 11 | 27 | intact | 3 | 3 | 3 | 4 | 110 | 100 | 65 | 45 | 1 | 54 | 14.7 | 84.99 |
| 12 | 24 | Intact | 2 | 1 | 2 | 3 | 170 | 165 | 80 | 85 | 2 | 78 | 5.2 | 88.33 |
| 13 | 24 | intact | 3 | 2 | 1 | 2 | 170 | 165 | 85 | 90 | 0 | 82 | 13.8 | 89.99 |

POD: postoperative day, MRI: magnetic resonance imaging, SST: supraspinatus, IST: infraspinatus, Atr: atrophy, FI: fatty infiltration, VAS: visual analog scale, CS: Constant-Murley score, DASH: Disabilities of the Arm, Shoulder, and Hand, ASES: American Shoulder and Elbow Surgeons, US: ultrasonography.

ment, and improvement in ROM was noted in 75% of the subjects. A systematic review [30] described subacromial balloon spacer placement as a minimally invasive and a technically simple procedure with low rates of perioperative complications and favorable outcomes at a limited short-term follow-up.

According to available systematic reviews on patch augmentation and bridging grafts for massive RCTs, despite the tendency to create a more severe tear, bridging grafts exhibit a high healing rate due to the low tension of the repair construct. However, the clinical outcomes were not significantly superior to those for patch augmentation, suggesting that a bridging procedure may provide superior tendon healing but may not necessarily improve function [15-17]. Ono et al. [16] suggested that this may be caused by the fact that a bridging graft merely "closes a hole" without attempting to restore the length-tension relation of the functional, contractile, musculotendinous unit, which may provide a more favorable biomechanical vector for the deltoid muscle.

We hypothesized that an arthroscopic bridging graft for an irreparable RCT with a modified Mason-Allen stitch using a tendon autograft could be used to decrease the tension on the repair of an irreparable RCT and restore the length-tension relationship of the musculotendinous unit. Modified Mason-Allen stitches, with the use of the plantaris tendon securely anchored to the relatively healthy proximal portion of the remaining rotator cuff—and the other side of the graft—could be robustly fixed to the humeral bone with bioabsorbable interference screws. Consequently, the grafts were designed to withstand the rotation and tension stresses of the rotator cuff and may transport force couples from the rotator cuff to the humeral head in a manner similar to that of healthy rotator-cuff tendons. The bridging graft technique produced similar clinical outcomes while providing superior biomechanical advantages that other procedures, such as latissimus dorsi and superior capsule reconstruction, could not provide.

Mori et al. [32] compared a fascia lata autograft group and a partial repair group. The study reported that the fascia lata autograft group had significantly superior clinical outcomes and a lower re-tear rate. The use of a GraftJacket Max graft on 16 patients, evaluated by Bond et al. [33], showed significant postoperative improvement in University of California, Los Angles scores. The outcomes in our study were similar. Awad et al. [34], who used an acellular dermal matrix in 49 patients, reported significant improvements in both Western Ontario Rotator Cuff and Disabilities of the Arm, Shoulder and Hand scores at a mean follow-up of 5.3 years. Comparing the results of this case series with that of previous studies, arthroscopic bridging graft for irreparable RCT with a modified Mason-Allen stitch produced outcomes comparable to those of other techniques.


https://doi.org/10.5397/cise.2022.01445

### Advantages and Disadvantages of Plantaris Tendon

The nature of materials that would be appropriate for this procedure is an important element of this study. An ideal graft must be securely anchored to the remaining rotator-cuff tissue as it must develop a robust bony attachment at the footprint to withstand rotation and tension stresses. In addition, it should promote cell recruitment and adherence, facilitating tendon regrowth. To satisfy these conditions, we proposed an autograft of the plantaris tendon that can provide sufficient length and tension and can readily engraft [35]. Plantaris autografts have several potential advantages: the tendon is easy to harvest and has a strong potential for biological superiority compared with allograft materials that may enhance healing with no inflammatory reactions. The width of the tendon (approximately 3 mm) makes it easy to pass through the rotator cuff, and its length (approximately 30 cm) allows for complex stitches such as modified Mason-Allen sutures [36]. It also costs less than allografts. The disadvantages of this techniques include tedious graft preparation, longer operating time, the absence of the plantaris tendons, and possible donor-site morbidities. Because harvesting and tendon preparation are necessary, the operating time inevitably increases by approximately 30 minutes. Although excluded from this study, failure in a patient who underwent a bridging graft using the semitendinosus tendon due to lack of plantaris was confirmed by MRI at 2 years. No further surgery was performed because the patient refused. No morbidity at the harvest site was reported in any case.

### Limitations

Our study had some limitations. First, the retrospective design of this study could introduce selection bias and potential confounding variables. Second, this study had a relatively low statistical power due to the short-term follow-up and small sample size. Additional follow-up observations are needed to determine if this method does not completely cover rotator-cuff defects. However, the short-term clinical outcomes at our institution have shown promising results. Larger studies with long-term follow-ups are required to further evaluate the efficacy of this technique.

## CONCLUSIONS

This case series shows that an arthroscopic bridging graft for irreparable RCTs using a modified Mason-Allen stitch and a plantaris tendon autograft resulted in improved short-term radiological and clinical outcomes. Graft integrity in most patients was maintained for up to 2 years after surgery. The technique can be considered for the treatment of a massive RCT. Further studies and follow-ups are required to determine the success of this technique.

## NOTES

### ORCID

Hyun-Gyu Seok https://orcid.org/0000-0002-7244-2698
Sam-Guk Park https://orcid.org/0000-0002-1135-5179

### Author contributions

Conceptualization: HGS, SGP. Investigation: HGS. Methodology: HGS, SGP. Project administration: HGS. Resources: SGP. Software: SGP. Supervision: SGP. Validation: HGS. Writing – original draft: HGS. Writing – review & editing: HGS, SGP.

### Conflict of interest

Sam-Guk Park is an editorial board member of the journal but was not involved in the peer reviewer selection, evaluation, or decision process of this article. No other potential conflict of interest relevant to this article was reported.

### Funding

None.

### Data availability

Contact the corresponding author for data availability.

### Acknowledgments

The authors would specially thank Jung kyoung Yoon, who works as a musculoskeletal radiologist at Nazareth General Hospital, for her assistance in the radiologic examination.

## REFERENCES

1. Yoo JC, Ahn JH, Yang JH, Koh KH, Choi SH, Yoon YC. Correlation of arthroscopic repairability of large to massive rotator cuff tears with preoperative magnetic resonance imaging scans. Arthroscopy 2009;25:573–82.
2. Warner JJ, Parsons IM 4th. Latissimus dorsi tendon transfer: a comparative analysis of primary and salvage reconstruction of massive, irreparable rotator cuff tears. J Shoulder Elbow Surg 2001;10:514–21.
3. Muench LN, Kia C, Jerliu A, et al. Clinical outcomes following biologically enhanced patch augmentation repair as a salvage procedure for revision massive rotator cuff tears. Arthroscopy 2020;36:1542–51.
4. Hersche O, Gerber C. Passive tension in the supraspinatus musculotendinous unit after long-standing rupture of its tendon: a preliminary report. J Shoulder Elbow Surg 1998;7:393–6.
5. Park SG, Shim BJ, Seok HG. How much will high tension ad-

versely affect rotator cuff repair integrity. Arthroscopy 2019;35:2992–3000.
6. Burkhart SS, Johnson TC, Wirth MA, Athanasiou KA. Cyclic loading of transosseous rotator cuff repairs: tension overload as a possible cause of failure. Arthroscopy 1997;13:172–6.
7. Rhee SM, Youn SM, Park JH, Rhee YG. Biceps rerouting for semirigid large-to-massive rotator cuff tears. Arthroscopy 2021;37:2769–79.
8. Jones CR, Snyder SJ. Massive irreparable rotator cuff tears: a solution that bridges the gap. Sports Med Arthrosc Rev 2015;23:130–8.
9. Rhee YG, Cho NS, Parke CS. Arthroscopic rotator cuff repair using modified Mason-Allen medial row stitch: knotless versus knot-tying suture bridge technique. Am J Sports Med 2012;40:2440–7.
10. Delaney RA, Lin A, Warner JJ. Nonarthroplasty options for the management of massive and irreparable rotator cuff tears. Clin Sports Med 2012;31:727–48.
11. Lee KW, Choi HG, Yang DS, Yu YT, Kim WS, Choy WS. Achilles tendon allograft for superior capsule reconstruction in irreparable massive rotator cuff tears. Clin Orthop Surg 2021;13:395–405.
12. Lee KW, Lee GS, Yang DS, Park SH, Chun YS, Choy WS. Clinical outcome of arthroscopic partial repair of large to massive posterosuperior rotator cuff tears: medialization of the attachment site of the rotator cuff tendon. Clin Orthop Surg 2020;12:353–63.
13. Mihata T, Lee TQ, Watanabe C, et al. Clinical results of arthroscopic superior capsule reconstruction for irreparable rotator cuff tears. Arthroscopy 2013;29:459–70.
14. Kim YS, Lee HJ, Park I, Sung GY, Kim DJ, Kim JH. Arthroscopic in situ superior capsular reconstruction using the long head of the biceps tendon. Arthrosc Tech 2018;7:e97–103.
15. Steinhaus ME, Makhni EC, Cole BJ, Romeo AA, Verma NN. Outcomes after patch use in rotator cuff repair. Arthroscopy 2016;32:1676–90.
16. Ono Y, Dávalos Herrera DA, Woodmass JM, Boorman RS, Thornton GM, Lo IK. Graft augmentation versus bridging for large to massive rotator cuff tears: a systematic review. Arthroscopy 2017;33:673–80.
17. Bailey JR, Kim C, Alentorn-Geli E, et al. Rotator cuff matrix augmentation and interposition: a systematic review and meta-analysis. Am J Sports Med 2019;47:1496–506.
18. Chalmers PN, Frank RM, Gupta AK, et al. All-arthroscopic patch augmentation of a massive rotator cuff tear: surgical technique. Arthrosc Tech 2013;2:e447–51.
19. Maqdes A, Abarca J, Moraiti C, et al. Does preoperative subscapularis fatty muscle infiltration really matter in anterosuperior rotator cuff tears repair outcomes? A prospective multicentric study. Orthop Traumatol Surg Res 2014;100:485–8.
20. Park SG, Seok HG. Use of an arthroscopic bridging graft for irreparable rotator cuff tears with the modified Mason-Allen stitch using a tendon autograft. Arthrosc Tech 2022;11:e857–61.
21. Rulewicz GJ, Beaty S, Hawkins RJ, Kissenberth MJ. Supraspinatus atrophy as a predictor of rotator cuff tear size: an MRI study utilizing the tangent sign. J Shoulder Elbow Surg 2013;22:e6-10.
22. Lippe J, Spang JT, Leger RR, Arciero RA, Mazzocca AD, Shea KP. Inter-rater agreement of the Goutallier, Patte, and Warner classification scores using preoperative magnetic resonance imaging in patients with rotator cuff tears. Arthroscopy 2012;28:154–9.
23. Davidson JF, Burkhart SS, Richards DP, Campbell SE. Use of preoperative magnetic resonance imaging to predict rotator cuff tear pattern and method of repair. Arthroscopy 2005;21:1428.
24. Reilly P, Bull AM, Amis AA, et al. Passive tension and gap formation of rotator cuff repairs. J Shoulder Elbow Surg 2004;13:664–7.
25. Gerber C, Maquieira G, Espinosa N. Latissimus dorsi transfer for the treatment of irreparable rotator cuff tears. J Bone Joint Surg Am 2006;88:113–20.
26. Weening AA, Willems WJ. Latissimus dorsi transfer for treatment of irreparable rotator cuff tears. Int Orthop 2010;34:1239–44.
27. Zastrow RK, London DA, Parsons BO, Cagle PJ. Superior capsule reconstruction for irreparable rotator cuff tears: a systematic review. Arthroscopy 2019;35:2525–34.e1.
28. Mihata T, Lee TQ, Fukunishi K, et al. Return to sports and physical work after arthroscopic superior capsule reconstruction among patients with irreparable rotator cuff tears. Am J Sports Med 2018;46:1077–83.
29. Denard PJ, Brady PC, Adams CR, Tokish JM, Burkhart SS. Preliminary results of arthroscopic superior capsule reconstruction with dermal allograft. Arthroscopy 2018;34:93–9.
30. Stewart RK, Kaplin L, Parada SA, Graves BR, Verma NN, Waterman BR. Outcomes of subacromial balloon spacer implantation for massive and irreparable rotator cuff tears: a systematic review. Orthop J Sports Med 2019;7:2325967119875717.
31. Senekovic V, Poberaj B, Kovacic L, et al. The biodegradable spacer as a novel treatment modality for massive rotator cuff tears: a prospective study with 5-year follow-up. Arch Orthop Trauma Surg 2017;137:95–103.
32. Mori D, Funakoshi N, Yamashita F. Arthroscopic surgery of irreparable large or massive rotator cuff tears with low-grade fatty


https://doi.org/10.5397/cise.2022.01445

degeneration of the infraspinatus: patch autograft procedure versus partial repair procedure. Arthroscopy 2013;29:1911–21.
33. Bond JL, Dopirak RM, Higgins J, Burns J, Snyder SJ. Arthroscopic replacement of massive, irreparable rotator cuff tears using a GraftJacket allograft: technique and preliminary results. Arthroscopy 2008;24:403–9.e1.
34. Awad MA, Sparavalo S, Ma J, King JP, Wong I. Interposition graft bridging reconstruction of irreparable rotator cuff tears using acellular dermal matrix: medium-term results. Arthroscopy 2022;38:692–8.
35. Josipović M, Vlaić J, Serdar J, et al. Plantaris tendon: a novel graft for anterolateral ligament reconstruction and additional reinforcement for anterior cruciate ligament autografts in combined reconstructive procedures. Knee Surg Sports Traumatol Arthrosc 2020;28:2604–8.
36. Yammine K, Saghie S, Assi C. A meta-analysis of the surgical availability and morphology of the plantaris tendon. J Hand Surg Asian Pac Vol 2019;24:208–18.

Original Article

Clin Shoulder Elbow 2023;26(4):416-422
https://doi.org/10.5397/cise.2022.01403

CiSE
Clinics in Shoulder and Elbow

eISSN 2288-8721

# The impact of modern airport security protocols on patients with total shoulder replacements

Michael D. Scheidt[1], Neal Sethi[2], Matthew Ballard[2], Michael Wesolowski[3], Dane Salazar[1], Nickolas Garbis[1]

[1]*Department of Orthopedic Surgery and Rehabilitation, Loyola University Medical Center, Maywood, IL, USA*
[2]*Stritch School of Medicine, Loyola University Chicago, Maywood, IL, USA*
[3]*Clinical Research Office Biostatistics Collaborative Core, Loyola University Chicago, Maywood, IL, USA*

**Background:** Advancements in airport screening measures in response to 9/11 have resulted in increased false alarm rates for patients with orthopedic and metal implants. With the implementation of millimeter-wave scanning technology, it is important to assess the changes in airport screening experiences of patients who underwent total shoulder arthroplasty (TSA).
**Methods:** Here, 197 patients with prior anatomic and reverse TSA completed between 2013 and 2020 responded to a questionnaire regarding their experiences with airport travel screening after their operation. Of these patients, 86 (44%) stated that they had traveled by plane, while 111 (56%) had not. The questionnaire addressed several measures including the number of domestic and international flights following the operation, number of false alarm screenings by the millimeter-wave scanner, patient body habitus, and presence of additional metal implants.
**Results:** A total of 53 patients (62%) responded "yes" to false screening alarms due to shoulder arthroplasty. The odds of a false screening alarm for patients with other metal implants was 5.87 times that of a false screening alarm for patients with no other metal implants (P<0.1). Of a reported 662 flights, 303 (45.8%) resulted in false screening alarms. Greater body mass index was not significantly lower in patients who experienced false screening alarms (P=0.30).
**Conclusions:** Patients with anatomic and reverse TSA trigger false alarms with millimeter-wave scanners during airport screening at rates consistent with prior reports following 9/11. Patient education on the possibility of false alarms during airport screening is important until improvements in implant identification are made.
**Level of evidence:** IV.

**Keywords:** Total shoulder arthroplasty; Reverse total shoulder arthroplasty; Airport screening; False alarm; Millimeter-wave scanner

## INTRODUCTION

In response to the terrorist attacks that occurred on September 11, 2001, the federal government established new legislation via the Transportation Security Administration to protect passenger safety. The Transportation Security Administration reinforced efforts that required several changes in airport security procedures. One change that carried significant weight was the federalization of passenger screening through increased sensitivity of airport screening devices. The fallout from this, as explained in a study by Blalock et al. [1] was added time and effort on the part of the passengers. This ultimately resulted in a 6% decrease in passenger volume on all flights and a 9% decrease on flights departing from the 50 busiest airports in the United States [1].

Received: December 4, 2022 Revised: March 4, 2023 Accepted: March 10, 2023
Correspondence to: Michael D. Scheidt
Department of Orthopedic Surgery and Rehabilitation, Loyola University Medical Center, 2160 S. First Ave, Maywood, IL 60153, USA
Tel: +1-414-630-9640, E-mail: mscheidt@luc.edu, ORCID: https://orcid.org/0000-0003-0213-6537

Copyright© 2023 Korean Shoulder and Elbow Society.
This is an Open Access article distributed under the terms of the Creative Commons Attribution Non-Commercial License (http://creativecommons.org/licenses/by-nc/4.0/) which permits unrestricted non-commercial use, distribution, and reproduction in any medium, provided the original work is properly cited.

An important development in airport security procedures included implementation of millimeter waves in airport screening devices throughout all United States airports starting in 2009. As detailed by Mohammadzade et al. [2], millimeter-wave technology has been utilized in airport screening devices in order to recognize critical objects in hidden cases without having the adverse effects on civilian health due to their non-ionizing features. Through the emission of electromagnetic waves ranging from 30 to 300 GHz, millimeter-wave scanners capture the wave energy reflected off of the body to generate images with similar resolution to conventional optical imaging [3]. However, the millimeter-wave scanners deployed for airport screening display areas of potential threats on a generic human figure using standard Automatic Target Recognition software rather than reconstructed full-body images to reduce privacy concerns [4]. Additionally, prior studies have demonstrated that millimeter-wave scanners can recognize 45.5% of a type of critical object at a 34.2% false alarm rate, demonstrating a high rate of false positives [2]. This begs the question of the burden of a high rate of false positives from airport screening devices on people with orthopedic implants.

Literature on the effect of orthopedic implants triggering airport devices has been relatively scarce, with only a few studies being published since the development of stricter security measures post-9/11 [5-15]. However, recent studies highlight the concern of high false-positive alarms in airport screening for orthopedic patients. In particular, false-alarm rates of patients with orthopedic implants have been reported between 0% and 70% [5-13]. Additionally, only one study since 9/11 has assessed the experiences of airport screening in patients with shoulder arthroplasty implants [7]. In 2007, Dines et al. [7] demonstrated an overall false-alarm rate of 52% for patients both with isolated total shoulder arthroplasties and with multiple orthopedic implants. Furthermore, 59 patients with isolated total shoulder arthroplasty (TSA) demonstrated false alarm rates of 55.4%. This is inconvenient to many patients with orthopedic implants, as patients are frequently subjected to more extensive searches, including showing their operative scar, searches in private rooms, and travel delays greater than 25 minutes [11].

While technology in airport screening has advanced over time, including standardized implementation of millimeter wave scanners across all United States airports occurring following the publication of Dines et al. [7], it is important to assess if airport travel screening for orthopedic patients has improved corresponding to the new technologic advances. The purpose of our study was to examine the effect of heightened airport security measures son patients with anatomic or reverse total shoulder arthroplasties, and other orthopedic implants. We hypothesized that false alarm rates would continue to be high despite screening technology advancements.

# METHODS

The present study was provided expedited approval by Institutional Review Board of Loyola University Chicago Health Sciences Division (No. 213508), and informed consent from patients was obtained.

### Retrospective Review

This study was a retrospective review of patients that underwent anatomic TSA or reverse TSA (RTSA) at a tertiary academic center between 2013 and 2020. Patients were provided a questionnaire either by telephone or by email asking whether they had traveled by airplane since their last operation, which is similar to prior studies by Dines et al [7]. Of the 408 patients contacted, 197 responded to the survey (48%). Of these patients, 86 stated they had traveled by airplane since their operation, while 111 stated they had not.

### Patient Survey

A summary of the patient survey is present in Table 1. Additional pertinent health information from their medical record, including current age, height, weight, and body mass index (BMI), was collected for further analysis. The number of travel experiences was only included following the patient's last total shoulder replacement or operation, including implant of a metal device. The questionnaires were completed over a period of three months

**Table 1.** Patient survey

| Patient survey questionnaire |
|---|
| 1. Is the type of shoulder implant you have from a TSA or reverse TSA? |
| 2. Do you have any other metal implant(s) in your body including prior open reduction internal fixation with standard orthopedic plates and screws or prior elbow, hip, knee, or ankle arthroplasties? |
| 3. Since your procedure, how many times have you traveled by plane? |
| 4. If you have traveled by plane, how many times have you traveled domestically or internationally? |
| 5. Have you utilized TSA pre-check or have access to any other form of expedited screening while traveling? |
| 6. Since your procedure, how many times have you triggered a false alarm during airport screening with the millimeter wave scanner? |
| 7. While traveling by plane, did you have a note from your physician stating you have metal implants? |
| 8. Were you educated by your physician that you may trigger false alarms during airport travel? |

TSA: total shoulder arthroplasty.

and were anonymously compiled on a spreadsheet with complete deidentification.

### Statistical Analysis

Frequencies and percentages of patient responses to the questionnaire are reported for categorical variables. Means and standard deviations (SDs) are reported for continuous variables. Frequencies and column percentages are reported to describe the bivariate associations between patient demographic, orthopedic, and travel predictors and false airport screening alarms due to arthroplasties or other orthopedic implants. Univariable binary logistic regression models were used to estimate the unadjusted effects of predictors on false screening alarms. Wald 95% confidence intervals and Wald chi-square P-values are reported for each odds ratio estimate. Total false alarm rate was estimated based upon the reported total number of flights and total false alarm experiences provided by each patient in their survey response.

Presence of false screening alarms in relation to patient BMI were evaluated utilizing a two-sample independent t-test assuming equal variances comparing BMI by false screening alarms with an associated box plot as a visual aid.

## RESULTS

### Patient Sample Characteristics

A summary of patient sample data is included in Table 2. A total of 86 of 197 patients surveyed responded yes to traveling by plane following their last TSA or most recent metallic orthopaedic implant. Of this subset, 53 patients (62%) responded "yes" to false screening alarms due to shoulder arthroplasty. The majority of these patients were female (59%), had other metal orthopedic implants (69%), had taken a domestic flight since their shoulder arthroplasty (94%), and had not taken an international flight since their shoulder arthroplasty (67%). The average patient age in this sample was 68.05 years (SD, 10.07), and the average patient BMI in this sample was 31.57 (SD, 6.11).

### False Alarm Rate

A summary of data regarding false alarm rate is presented in Table 3. A reported total of 662 flights were taken following the patients' most recent shoulder arthroplasty, including 570 (86.1%) domestic flights and 92 (13.9%) international flights. Across all patient-reported flights, there was an estimated false alarm rate of 45.8% (303/662) during airport screening.

### Predictors for False Screening Alarms

A summary of predictors for false screening alarms is available in Table 4. The presence of other metal orthopedic implants ($P < 0.01$) was the only predictor that demonstrated a significant effect on false screening alarm. The odds of a false screening alarm for patients with other metal implants was 5.87 times that of patients with no other metal implants ($P < 0.1$).

### BMI and Screening

A summary of comparison between false alarms and patient BMI

**Table 2.** Summary of patient demographics, orthopedic procedures, and airplane travel

| Variable | Value (n = 86) |
|---|---|
| Sex | |
| Female | 51 (59) |
| Male | 35 (40) |
| Type of shoulder arthroplasty | |
| Total | 41 (48) |
| Reverse | 45 (52) |
| Other metal implants | |
| Yes | 59 (69) |
| No | 27 (31) |
| Domestic flights following shoulder arthroplasty | |
| Yes | 81 (94) |
| No | 5 (6) |
| International flights following shoulder arthroplasty | |
| Yes | 28 (33) |
| No | 58 (67) |
| TSA pre-check use following shoulder arthroplasty | |
| Yes | 39 (45) |
| No | 47 (55) |
| False screening alarm due to shoulder arthroplasty | |
| Yes | 53 (62) |
| No | 33 (38) |
| Advised that implant might set off airport alarms | |
| Unsure | 10 (12) |
| Yes | 24 (28) |
| No | 52 (60) |
| Physician note regarding metal implants | |
| Yes | 17 (20) |
| No | 69 (80) |
| Age (yr) | 68.05 ± 10.07 |
| Body mass index (kg/m$^2$) | 31.57 ± 6.11 |

Values are presented as number (%) or mean ± standard deviations.

**Table 3.** Summary of total flights and false alarm rate

| Variable | No. (%) |
|---|---|
| Patient flight | |
| Domestic | 570 (86.1) |
| International | 92 (13.9) |
| Total | 662 |
| False alarm occurrence | |
| Yes | 303 (45.8) |
| No | 359 (54.2) |


https://doi.org/10.5397/cise.2022.01403

**Table 4.** Unadjusted effects of patient predictors on false screening alarms

| Variable | False screening alarm due to shoulder arthroplasty | | OR (95% CI) | P-value* |
|---|---|---|---|---|
| | Yes | No | | |
| No. (%) | 53 (62) | 33 (38) | - | - |
| Sex | | | 0.60 (0.25–1.49) | 0.27 |
| Female | 29 (55) | 22 (67) | | |
| Male (Ref) | 24 (45) | 11 (33) | | |
| Type of shoulder arthroplasty | | | 1.09 (0.45–2.66) | 0.85 |
| Total | 25 (47) | 16 (48) | | |
| Reverse (Ref) | 28 (53) | 17 (52) | | |
| Other metal implants | | | 5.87 (2.18–15.82) | < 0.01 |
| Yes | 44 (83) | 15 (45) | | |
| No (Ref) | 9 (17) | 18 (55) | | |
| International flights following shoulder arthroplasty | | | 1.26 (0.49–3.21) | 0.64 |
| Yes | 19 (36) | 9 (27) | | |
| No (Ref) | 34 (64) | 24 (73) | | |
| TSA pre-check use following shoulder arthroplasty | | | 1.48 (0.61–3.58) | 0.38 |
| Yes | 26 (49) | 13 (39) | | |
| No (Ref) | 27 (51) | 20 (61) | | |
| Advised that implant might set off airport alarms | | | 1.22 (0.45–3.30) | 0.69 |
| Yes | 15 (33)† | 9 (29)† | | |
| No (Ref) | 30 (67) | 22 (71) | | |
| Physician note regarding metal implants | | | 1.64 (0.52–5.17) | 0.40 |
| Yes | 12 (23) | 5 (15) | | |
| No (Ref) | 41 (77) | 28 (85) | | |
| Age (yr) | 67.16 ± 8.87 | 69.39 ± 11.68 | 0.89 (0.71–1.12)‡ | 0.32 |
| Body mass index (kg/m$^2$) | 32.14 ± 6.11 | 30.71 ± 6.10 | 1.22 (0.84–1.77)‡ | 0.30 |

Values are presented as number (%) or mean ± standard deviation. Frequencies and column percentages are reported to describe the bivariate associations between patient demographic, orthopedic, and travel predictors and false airport screening alarms due to arthroplasty. Predictors were based upon "yes" or "no" responses, rather than total.
OR: odds ratio, CI: confidence interval, Ref: reference.
*Fisher's exact test P-value, significance defined as less than 0.05; †Incomplete data due to lack of survey response; ‡Per 5-unit increase.

**Table 5.** Comparison of BMI by false screening alarm

| | False screening alarm (n = 53) | No false screening alarm (n = 33) | P-value* |
|---|---|---|---|
| BMI (kg/m$^2$) | 32.14 ± 6.11 | 30.71 ± 6.10 | 0.30 |

Values are presented as mean ± standard deviation.
BMI: body mass index.
*Significant at α = 0.05 level.

is present in Table 5 and Fig. 1. BMI was higher among patients reporting having experienced a false screening alarm (Mean ± SD, 32.14 ± 6.11) compared to patients reporting no false screening alarm (mean ± SD, 30.71 ± 6.10), but the difference was not significant. There was no statistically significant difference in BMI by false screening alarm (P = 0.30). Additionally, the substantial overlap and lack of separation between the stratified distributions for BMI suggest no significant difference in BMI by false screening alarm.

## DISCUSSION

The increased awareness of terrorism threats following the events of 9/11 has resulted in drastic changes to airport security measures in the United States and around the world. The concomitant increase in air travel screening sensitivity has resulted in a greater incidence of false alarms for patients with metal implants from prior orthopedic procedures, most notably total joint arthroplasty [6]. The increased rate of false alarms for orthopedic patients leads to anxiety and uncertainty of unexpected travel delays and more extensive searches [11]. Determining methods to

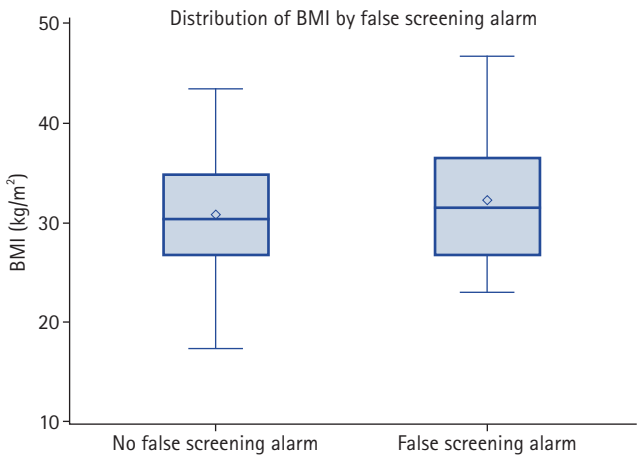


**Fig. 1.** Distribution of body mass index (BMI) by false screening alarm stratified box plot analysis. There was no significant difference observed in BMI by false screening alarm (P=0.30).

reduce the need for extensive screening measures for patients with orthopedic implants is imperative to improve overall postoperative satisfaction and quality of life. The activation of metal detector devices, including arch and handheld metal detector devices, has been discussed in orthopedic literature over the last 20 years [5-15]. However, as time has passed, no definitive solutions have been developed to decrease the rate of additional screening measures for patients with orthopedic implants.

To our knowledge, only one prior survey regarding airport travel experiences in TSA patients has been published since the events of 9/11, while none have been published prior to these events. In 2007, Dines et al. [7] reported a false alarm rate of 52% for domestic travel and 42% for international travel. Furthermore, patients with only one total shoulder implant were subjected to false alarms in 55.4% of all flights (245 total) [7]. While this is inconvenient, there is added burden as patients who set off gate alarms are subsequently subjected to wand inspection, which showed false positives in 240/245 (97.9%) occasions [7]. While advancements in imaging technology, including the standard millimeter wave-scanners, have been implemented across all airports since 2009 to increase the accuracy and security associated with travel screening [4], our data suggest that travelers with total shoulder replacements and other metal orthopedic implants continue to experience false alarms, extensive searches, and travel delays at consistent rates. In our cohort of 86 patients, 62% reported delays during airport travel due to false alarm screening, with one patient reported a 45.8% total false alarm rate (303/662 reported flights).

While several risk factors for false alarms in patients with orthopedic implants have been described in the literature, including implant mass and metal composition [16], the sensitivity of millimeter-wave body scanners for orthopedic implants remains unclear. Unsurprisingly, our study demonstrated a statistically greater incidence of false alarms in patients with multiple metal implants, including non-shoulder joint replacements, plates, and screws in addition to TSA. While each non-shoulder arthroplasty implant was not stratified for analysis, the overall finding was that patients with additional metal implants experience more frequent false-alarm risk, consistent with findings of prior studies [16].

Most common rates of false-alarms have been noted in patients with total joint arthroplasty, including that of the shoulder, knee, and hip (31%–100%), while reduced rates of false alarms are observed in patients with hand, foot, ankle, and spine implants; intramedullary nails; wire; and screws (0%–40%) [7,9,10,16-18]. One possible contributory factor of differing detection rates is implant composition. Implants composed of cobalt-chromium alloys appear to result in more false alarms during airport screening than do titanium-based or stainless-steel-based implants [8-10,16]. Although implant composition was not directly assessed in our study, we observed no statistically significant difference in detection rates between anatomic TSA and RTSA implants. This may be attributed to the similar mass and general composition of reverse and anatomic TSA implants. Additionally, studies in the past have suggested that "soft-tissue masking" from greater patient BMI may result in lower false alarm rates in patients with orthopedic implants [13]. However, more recent studies suggest that BMI does not significantly affect the rate of detection [5,7,8,19]. This corresponds with the findings of our study, where greater patient BMI was not significantly higher in patients who experienced false alarms in comparison to those who did not. However, further studies focusing on more objective assessment of BMI and false screening alarms are necessary to see if "soft-tissue masking" has an effect on overall detection rates during airport screening.

Several studies have suggested the use of identification cards as a method for reducing extensive screening measures during air travel. Ali et al. [11] surveyed 50 patients with prior hip and knee total joint arthroplasties on their experiences with airport travel following their operation. Of the patient population, there was a reported false positive rate of 86% (43/50), with 70% (30/43) of these patients being subjected to more extensive searches, including showing their operative scar (30/43) and being transferred to private rooms (15/43). Of these people, 84% stated that an identification card provided by their physician would have helped with the screening process. Additionally, of 10 airport security officials surveyed, 90% stated that implant identification cards would be useful during airport screening [11]. Possible limitations to or-


https://doi.org/10.5397/cise.2022.01403

thopedic implant identification cards include ease in reproducibility and falsification, which could pose a threat to general airport security measures. One plausible solution was presented by Fong and Zhuang [20], where they described the use of a biometrics medical card containing patient medical history for user identity authentication. The use of such technology could provide a secure method of confirming orthopedic implantation during airport screening. Additionally, Ali et al. [11] discussed the use of biometric data available on ePassports or orthocards previously distributed by the British Orthopaedic Association as possible standardized options for airport screening. However, concerns for patient medical privacy and costs associated with implementing such technology nationwide are not without reason. Nevertheless, standardized identification methods are necessary to improve patient experiences with air travel following TSA.

There are several limitations of this study, particularly related to its nature as a retrospective questionnaire. First, the responses to this questionnaire were based upon the included patient sample recalling the number of times they have traveled by air and number of false alarms during airport screening, subjecting the study to recall bias. For this reason, the comparative analysis for predictors of false alarms was limited to "yes" and "no" responses, while the estimated overall false alarm screening rate was calculated from the total flights and total false alarms from the subjective survey responses. Thus, more objective measures in future studies are required to determine more accurate false alarm rates per flight for patients with metal orthopedic implants. Second, as a retrospective survey of patients from a single tertiary medical center, this study does not represent a consecutive cohort of patient experiences in airport travel following RTSA , anatomic TSA, and other orthopedic surgeries. Third, the study population included a high number of patients with multiple metal implants, including shoulder arthroplasty. While implant number and type were identified during the survey, no formal analysis stratifying by type of additional implant was completed. However, our analysis builds upon prior studies demonstrating greater odds of false alarms with greater medical implant mass. Furthermore, it is unclear to what extent airport security screening varies among different airports, as our questionnaire grouped flights as only domestic or international. However, patients included in the study all reported screening utilizing the millimeter-wave scanner standardized in all airports during initial screening. Last, our study may be underpowered, as a formal power analysis for assessing the predictors in false screening alarms was not completed. Follow-up studies with larger patient populations and more objective measures may be required to further assess predictors for false-alarm screening.

## CONCLUSIONS

Patients with anatomic and RTSA trigger false alarms with millimeter-wave scanners during airport screening at rates consistent with prior reports following 9/11. Patient education on the possibility of false alarms during airport screening is important until improvements in implant identification are made.

## NOTES

### ORCID

Michael D. Scheidt https://orcid.org/0000-0003-0213-6537

### Author contributions

Conceptualization: MDS, DS, NG. Data curation: MDS, NS, MB. Formal Analysis: MW. Investigation: NS, MB. Methodology: MDS, NS, MB, MW, DS, NG. Resources: NG. Supervision: DS, NG. Validation: MDS, NS, MW, DS, NG. Writing – original draft: MDS, NS, MB, MW. Writing – review & editing: MDS, NS, DS, NG.

### Conflict of interest

Dr. Salazar reports personal fees from Tornier Wright Medical and from Zimmer Biomet, unrelated to the submitted work. Dr. Garbis reports personal fees from DJO, unrelated to the submitted work.

### Funding

None.

### Data availability

Contact the corresponding author for data availability.

### Acknowledgments

None.

## REFERENCES

1. Blalock G, Kadiyali V, Simon DH. The impact of post-9/11 airport security measures on the demand for air travel. J Law Econ 2007;50:731–55.
2. Mohammadzade H, Ghojogh B, Faezi S, Shabany M. Critical object recognition in millimeter-wave images with robustness to rotation and scale. J Opt Soc Am A Opt Image Sci Vis 2017; 34:846–55.
3. Laviada J, Arboleya-Arboleya A, Álvarez Y, González-Valdés B, Las-Heras F. Multiview three-dimensional reconstruction by

millimetre-wave portable camera. Sci Rep 2017;7:6479.
4. National Academies of Sciences, Engineering, and Medicine. Airport passenger screening using millimeter wave machines: compliance with guidelines. The National Academies Press; 2017.
5. Obremskey WT, Austin T, Crosby C, et al. Detection of orthopaedic implants by airport metal detectors. J Orthop Trauma 2007;21:129–32.
6. Ramirez MA, Rodriguez EK, Zurakowski D, Richardson LC. Detection of orthopaedic implants in vivo by enhanced-sensitivity, walk-through metal detectors. J Bone Joint Surg Am 2007;89:742–6.
7. Dines JS, Elkousy H, Edwards TB, Gartsman GM, Dines DM. Effect of total shoulder replacements on airport security screening in the post-9/11 era. J Shoulder Elbow Surg 2007;16:434–7.
8. Ismail A, Dancey A, Titley OG. Prosthetic metal implants and airport metal detectors. Ann R Coll Surg Engl 2013;95:211–4.
9. Chan JY, Mani SB, Williams PN, et al. Detection of in vivo foot and ankle implants by walkthrough metal detectors. Foot Ankle Int 2014;35:789–95.
10. Woon RP, Andras LM, Barrett KK, Skaggs DL. Cobalt chrome spinal constructs trigger airport security screening in 24% of pediatric patients. Spine Deform 2015;3:188–91.
11. Ali E, Kosuge D, MacDowell A. The need for an implant identification card at airport security check. Clin Orthop Surg 2017;9:153–9.
12. Fabricant PD, Robles A, Blanco JS. Airport metal detector activation is rare after posterior spinal fusion in children with scoliosis. J Child Orthop 2013;7:531–6.
13. van der Wal BC, Grimm B, Heyligers IC. Airport detectors and orthopaedic implants. Acta Orthop Belg 2005;71:379–84.
14. Naziri Q, Johnson AJ, Hooper HA, Sana SH, Mont MA. Detection of total knee prostheses at airport security checkpoints. J Arthroplasty 2012;27:1228–33.
15. Johnson AJ, Naziri Q, Hooper HA, Mont MA. Detection of total hip prostheses at airport security checkpoints: how has heightened security affected patients. J Bone Joint Surg Am 2012;94:e44.
16. Kuczmarski AS, Harris AP, Gil JA, Owens BD. Sensitivity of airport metal detectors to orthopaedic implants. JBJS Rev 2018;6:e7.
17. Basu P, Packer GJ, Himstedt J. Detection of orthopaedic implants by airport metal detectors. J Bone Joint Surg Br 1997;79:388–9.
18. Grohs JG, Gottsauner-Wolf F. Detection of orthopaedic prostheses at airport security checks. J Bone Joint Surg Br 1997;79:385–7.
19. Kamineni S, Legge S, Ware H. Metallic orthopaedic implants and airport metal detectors. J Arthroplasty 2002;17:62–5.
20. Fong S, Zhuang Y. Using medical history embedded in biometrics medical card for user identity authentication: data representation by AVT hierarchical data tree. J Biomed Biotechnol 2012;2012:539395.


https://doi.org/10.5397/cise.2022.01403

Review

Clin Shoulder Elbow 2023;26(4):423-437
https://doi.org/10.5397/cise.2022.01067

CiSE
Clinics in Shoulder and Elbow

eISSN 2288-8721

# Radiofrequency in arthroscopic shoulder surgery: a systematic review

**Neeraj Vij[1], Joseph N. Liu[2], Nirav Amin[3]**

[1]*Department of Orthopedic Surgery, University of Arizona College of Medicine, Phoenix, AZ, USA*
[2]*Department of Orthopedic Surgery, Keck Hospital of the University of Southern California, Los Angeles, CA, USA*
[3]*Premier Orthopaedic & Trauma Specialists, Pomona, CA, USA*

**Background:** Radiofrequency has seen an increase in use in orthopedics including cartilage lesion debridement in the hip and knee as well as many applications in arthroscopic shoulder surgery. The purpose of this systematic review is to evaluate the safety and usage of radiofrequency in the shoulder.
**Methods:** This systematic review was registered with PROSPERO (international registry) and followed the preferred reporting items for systematic review and meta-analysis protocols (PRISMA-P) guidelines. Embase and PubMed were searched using: "shoulder," "rotator cuff," "biceps," "acromion" AND "monopolar," "bipolar," "ablation," "coblation," and "radiofrequency ablation." The title and abstract review were performed independently. Any discrepancies were addressed through open discussion.
**Results:** A total of 63 studies were included. Radiofrequency is currently utilized in impingement syndrome, fracture fixation, instability, nerve injury, adhesive capsulitis, postoperative stiffness, and rotator cuff disease. Adverse events, namely superficial burns, are limited to case reports and case series, with higher-level evidence demonstrating safe use when used below the temperature threshold. Bipolar radiofrequency may decrease operative time and decrease the cost per case.
**Conclusions:** Shoulder radiofrequency has a wide scope of application in various shoulder pathologies. Shoulder radiofrequency is safe; however, requires practitioners to be cognizant of the potential for thermal burn injuries. Bipolar radiofrequency may represent a more efficacious and economic treatment modality. Safety precautions have been executed by institutions to cut down patient complications from shoulder radiofrequency. Future research is required to determine what measures can be taken to further minimize the risk of thermal burns.

**Keywords:** Radiofrequency; Plasma energy; Arthroscopic shoulder surgery; Safety; Efficiency

## INTRODUCTION

Radiofrequency (RF) refers to application of thermal energy to reorganize tissue on a molecular level and restore normal structure and function [1]. Traditional RF or electrocauterization refers to the use of thermal energy to treat surgical pathology by passing electrical current directly through tissue [1]. RF can be delivered through a monopolar or bipolar device [1-3]. Bipolar RF represents a safer alternative at lower temperatures, voltages, contact pressures, and contact times [1]. These devices create high-energy free radicals that can break molecular bonds and excise soft tissue at relatively low temperatures (40°C–70°C) [2]. RF systems are widely used in arthroscopic orthopedic procedures for ablation, resection, and coagulation of soft tissues [3]. RF en-

Received: June 19, 2022 Revised: September 15, 2022 Accepted: September 16, 2022
Correspondence to: Neeraj Vij
Department of Orthopedic Surgery, University of Arizona College of Medicine, 475 N. 5th St, Phoenix, AZ 85004, USA
Tel: +1-602-827-2002, Fax: +1-602-827-2074, E-mail: neerajvij@email.arizona.edu, ORCID: https://orcid.org/0000-0002-7214-0411

Copyright© 2023 Korean Shoulder and Elbow Society.
This is an Open Access article distributed under the terms of the Creative Commons Attribution Non-Commercial License (http://creativecommons.org/licenses/by-nc/4.0/) which permits unrestricted non-commercial use, distribution, and reproduction in any medium, provided the original work is properly cited.

ergy is not without its risks and does exhibit time-dependent effects that need to be considered by surgeons [4]. Next-generation RF devices utilize plasma energy fields to deliver thermal energy to minimize damage to the surrounding soft tissues [1,5].

The safety profile of RF has been studied in the knee in the context of low-grade cartilage lesions [2]. The safety of RF has also been well-studied in the hip for ablating soft tissues [6]. In the glenohumeral joint, RF was first studied in the context of instability but resulted in overtreatment [7], permanent tissue damage [7], and high failure rates necessitating capsular plication [8,9]. However, there are limited reports on the temperature profile and complications in shoulder joint RF.

In recent years, there have been many studies published regarding the use of RF energy in the surgical treatment of many shoulder pathologies. In the existing publications regarding RF use in the shoulder, the purpose of the equipment is to split and partially remove soft tissues [10-20]. However, the safety and complications of RF use to debride soft tissue have not been established. The purpose of this investigation is to conduct a systematic review of the currently available literature to evaluate the safety and complication profile of RF devices for use in the shoulder.

# METHODS

## General

This systematic review was registered in an international prospective register of systematic reviews (PROSPERO No. CRD 42021288444.) The Preferred Reporting Items for Systematic Reviews and Meta-Analyses Protocols (PRISMA-P) guidelines were followed.

## Literature Search

The literature search was performed using Embase and PubMed with the keywords displayed in Table 1. The initial literature search revealed 1,531 studies. After removal of duplicate articles, title and abstract screening was performed on 1,374 studies. Of these, 537 studies did not pertain to the use of RF in arthroscopic shoulder surgery. Finally, the full-text of 837 studies was screened (Fig. 1).

## Study Selection

Studies were selected according to the inclusion and exclusion criteria presented in Table 2. Of note, studies related to shoulder capsulorrhaphy usage were excluded, given the high complication rates of axillary nerve dysfunction, articular cartilage damage, and capsular necrosis [21]. Application of our inclusion and exclusion criteria resulted in a total of 63 studies.

## Qualitative Synthesis

Due to a limited number of high-level clinical studies on the topic and heterogeneous reporting of data, the included studies were qualitatively synthesized. The included studies were grouped into those that contained data regarding the performance profile of RF and those that did not. The performance profile was defined as any mention of the temperature profile, safety profile and

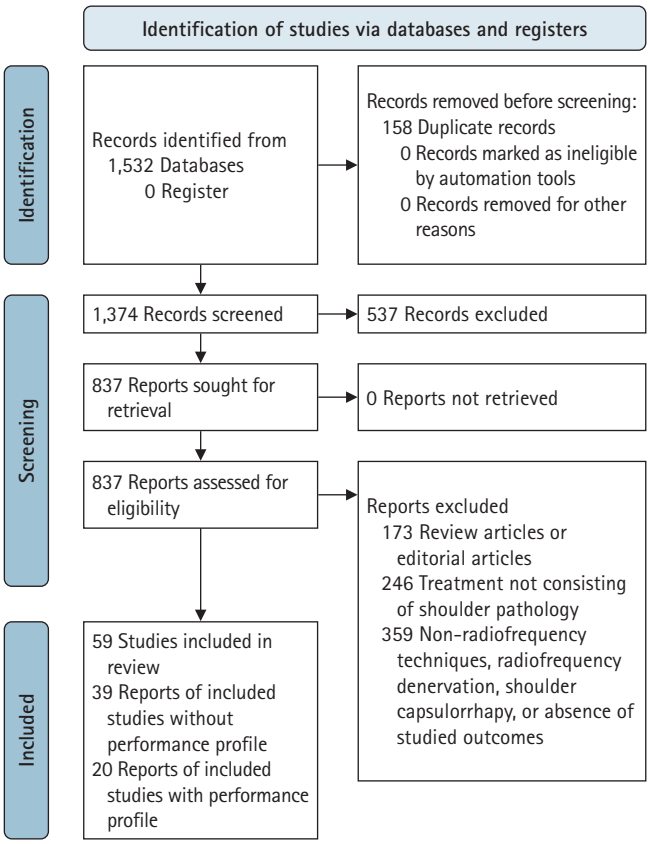


**Fig. 1.** The Preferred Reporting Items for Systematic Reviews and Meta-Analyses Protocols (PRISMA-P) flow diagram for our study.

**Table 1.** Search keywords used in the literature search

| Search term category | Keywords used |
|---|---|
| Anatomic location | 'shoulder,' 'rotator cuff,' 'biceps,' 'acromion' |
| Radiofrequency modality | 'monopolar,' 'bipolar,' 'ablation,' 'coblation,' 'turbovac,' 'radiofrequency ablation' |


https://doi.org/10.5397/cise.2022.01067

**Table 2.** Inclusion and exclusion criteria utilized for the identification of relevant studies

| Inclusion criteria | Exclusion criteria |
|---|---|
| Treatment regarding radiofrequency usage in during arthroscopic shoulder surgery | Non-radiofrequency techniques, radiofrequency denervation or shoulder capsulorrhaphy |
| Clinical, cadaveric, or animal studies | Other review articles or editorial articles |
| Inclusion of data regarding the temperature profile or the safety and complication rate | Treatment not consisting of orthopedic pathology or upper extremity |

complication rate, or clinical outcomes. These studies were grouped accordingly and descriptively summarized in the tables.

# RESULTS

## General

Of our 59 included articles, 39 did not include RF performance in terms of temperature profile or complications. The remaining 20 studies did include at least one of these measures. The studies in this review that discuss RF for shoulder arthroscopic orthopedic procedures without data on performance profile do provide insight regarding the breadth of shoulder RF use and are summarized in Table 3 [10,12-19,22-51]. Table 3 revealed bipolar RF as the most commonly used modality. Of the 39 studies depicted in Table 3, only 17 (43.6%) specified the RF modality, all of which were bipolar. The remaining 22 studies (56.4%) were unspecified.

## Performance Profile

Studies that disclosed the performance profile of RF usage in the shoulder were further analyzed. These studies were grouped by temperature profile (Table 4) [3,20,52-62] and complications (Table 5) [21,63-68].

## Temperature Profile

Our literature review identified two randomized controlled trials, two prospective cohort studies, two case series, three cadaveric studies, two animal studies, and two basic science studies exploring the temperature profile of RF ablation devices in the shoulder (Table 4).

While comparing RF instruments, Huynh et al. [3] found few differences in temperature characteristics. The peak temperature during RF usage in subacromial decompression was 32.0°C (range, 29.3 °C–43.1°C) [55]. The mean peak temperature of outflow fluid was 71.6°C, assumed to mimic wand tip temperature, which should be between 40 and 70°C [55]. During the study, Barker et al. [55] found the most crucial factor in subacromial temperature to be fluid irrigation temperature. For this reason, they recommended against the use of warmed irrigation fluid in RF. Davies et al. [56] also suggested that irrigation fluid be cooled before RF usage. In their case series of 30 patients, subacromial bursa temperature during RF with a monopolar device was assessed. Mean (27.8°C) and maximum (41.8°C) temperatures were observed well below the chondrocyte damage threshold temperature. The authors explained the isolated reading of 41.8°C to be due to blockage of the RF suction probe [56].

Good et al. [58] performed a cadaveric study regarding intraarticular temperatures during shoulder RF use. Intraarticular temperatures increased above 45°C in each trial. The highest peak temperatures were observed when the fluid flow rate was 0%, while the lowest peak temperatures were observed when the fluid flow rate was 100% [58]. No statistical differences in mean temperature were observed whether the device was immersed in fluid or in direct contact with tissue [58]. Zoric et al. [57] demonstrated three factors that were critical for maintaining safe intra-articular temperature: rate of flow, distance of device application, and duration of usage. This study also suggested that maximization of irrigation flow, shorter duration of device use, and adequate suction techniques further prevent temperature-related patient complications and injuries.

## Safety and Complications

Overall, reports of postoperative complications following RF methods were lacking (Table 5). Our literature search revealed one prospective controlled trial, one case series, and five case reports that provided significant complication rates or commented on the safety profile. The small number of reported complications from RF usage within the literature was related to increased irrigation fluid temperature and was limited to case reports [55] and case series [65]. Four cases of second-degree burns were reported by Troxell et al. [65] due to a bipolar RF device being used in an unreported number of patients over 4 years. The authors [65] attributed these four cases to lack of outflow tubing. Since changing their practice, further burn cases have not occurred.

The most common adverse events of RF use are thermal injuries due to high temperature of the fluid and surrounding tissue [3]. Many studies involve novel arthroscopic techniques with RF devices, yet parameters of its use such as safety, complications, and outcome profiles are poorly detailed within the majority of

**Table 3.** Studies included within this review article where RF device usage occurred without performance outcome disclosure by authors

| Study | Use | Study purpose | Device used | Radiofrequency mode | Amount of radiofrequency use |
|---|---|---|---|---|---|
| Baumgarten et al. [22] | Acromioclavicular joint reconstruction | To propose a novel technique for the reconstruction of acromioclavicular joint | Unspecified | Unspecified | Minor |
| Cvetanovich et al. [10] | Adhesive capsulitis | To report outcomes after 360° arthroscopic capsular release for glenohumeral adhesive capsulitis performed in the lateral decubitus position | Super Turbovac 90 (Arthrocare; Smith & Nephew, Austin, TX, USA) | Coblation | Major |
| Cvetanovich et al. [14] | Adhesive capsulitis | Description of an arthroscopic 360° capsular release method | Super Turbovac 90 (Arthrocare) | Coblation | Major |
| Arce et al. [13] | Adhesive capsulitis | To detail an arthroscopic capsular release for primary frozen shoulder syndrome | VAPR III (DePuy Mitek, Raynham, MA, USA) | Bipolar | Major |
| Katthagen et al. [23] | Anterior instability | Presentation of a novel technique in open Latarjet procedure along with an arthroscopic Hills-Sachs remplissage | Super Turbovac 90 (Arthrocare) | Coblation | Minor |
| Ganokroj et al. [24] | Anterior instability | To propose a novel arthroscopic technique called the "double row-double pulley" in the restoration of a bony Bankart lesion | Super Turbovac 90 (Arthrocare) | Coblation | Minor |
| Lewington et al. [25] | Anterior shoulder instability | To present a method for shoulder instability using lateral decubitus arthroscopic Latarjet procedure | StarVac 90 (Arthrocare) | Coblation | Minor |
| Gomes et al. [26] | Anterior shoulder instability | To present a Marfan's Syndrome patient with recurrent anterior shoulder dislocation due to hyperlaxity requiring arthroscopic treatment | Unspecified | Unspecified | Major |
| Saithna et al. [17] | Biceps pathology | Description of a novel technique to transilluminate the bicipital groove and identify long head biceps tendon | Unspecified | Unspecified | Minor |
| Shih et al. [27] | Biceps pathology | Introduction of a novel technique for arthroscopic suprapectoral biceps tenodesis utilizing an all suture method | Unspecified | Unspecified | Minor |
| Valenti et al. [19] | Biceps pathology | To present a novel technique for arthroscopic biceps tenodesis | VAPR Coolpulse 90 (DePuy Mitek) | Bipolar | Major |
| Daggett et al. [28] | Biceps pathology | To describe a novel arthroscopic technique for bicep tenodesis, the "loop lock" technique | Unspecified | Unspecified | Minor |
| Saithna et al. [29] | Biceps pathology | To present a novel method to identify the long head biceps tendon within the subacromial space | Unspecified | Unspecified | Major |
| Su et al. [18] | Biceps pathology | To introduce a novel technique utilizing a double knotless screw for tenodesis of the long head of the biceps | Unspecified | Unspecified | Minor |

(Continued to the next page)


https://doi.org/10.5397/cise.2022.01067

**Table 3.** Continued

| Study | Use | Study purpose | Device used | Radiofrequency mode | Amount of radiofrequency use |
|---|---|---|---|---|---|
| Armangil et al. [30] | Brachial plexopathy | To describe a recollection of obstetrical brachial plexus palsy released with arthroscopic technique | Unspecified | Unspecified | Minor |
| Li et al. [31] | Coracoclavicular ligament repair | Description of a novel technique for coracoclavicular ligament repair arthroscopically | Unspecified | Unspecified | Major |
| Yalizis et al. [32] | Impingement syndrome | To describe the acquisition of a panoramic view of the subacromial space arthroscopically | Unspecified device | Unspecified | Major |
| Pagán Conesa et al. [33] | Impingement syndrome | Presentation of intramuscular lipoma of supraspinatus muscle causing impingement syndrome treated arthroscopically | Unspecified device | Unspecified | Minor |
| O'Brien et al. [34] | Impingement syndrome | To introduce a novel technique of the "subdeltoid approach" for anterior shoulder arthroscopy | Unspecified "radiofrequency ablation device" | Unspecified | Minor |
| Mellano et al. [35] | Impingement syndrome | To propose an optimized technique for arthroscopic acromioplasty | Unspecified | Unspecified | Minor |
| Valenti et al. [36] | Impingement syndrome | To describe a novel technique in arthroscopic subscapularis assessment after removal of the coracoid process for shoulder impingement prophylaxis | VAPR (DePuy Mitek) | Bipolar | Minor |
| Hendrix et al. [37] | Other | To describe a novel arthroscopic technique for Pec Minor release to treat shoulder pain and dysfunction | Unspecified | Unspecified | Minor |
| Theopold et al. [38] | Other | To evaluate the accuracy of arthroscopic placement versus conventional placement of coracoclavicular tunnels | Unspecified | Unspecified | Minor |
| Scheibel et al. [39] | Other | To present cases of gracilis tendon transclavicular-transcoracoid loop technique via arthroscopic Tight-Rope | Unspecified | Unspecified | Minor |
| Almazan et al. [40] | Other | To compare and detail the results of the indirect bursal technique with the direct superior approach (the arthroscopic trans-articular distal clavicle resection) | VAPR 2 Side Effect (DePuy Mitek) | Bipolar | Minor |
| Boileau et al. [41] | Posterior instability | To introduce data from a novel arthroscopic posterior bone block technique | Unspecified | Unspecified | Minor |
| Parada et al. [15] | Posterior instability | Description of novel graft transfer technique during arthroscopic posterior glenoid reconstruction | Super Turbovac (Arthrocare) | Coblation | Minor |
| Rausch et al. [42] | Postoperative stiffness | To describe a novel arthroscopic method for restoration of shoulder mobility treatment of scapula neck fractures | Ambient Super TurboVac 90 (Arthrocare) | Coblation | Major |
| Bhatia et al. [43] | Proximal humerus fracture | Introduction of proximal humeral plate removal via arthroscopy | Unspecified | Unspecified | Minor |

(Continued to the next page)

**Table 3.** Continued

| Study | Use | Study purpose | Device used | Radiofrequency mode | Amount of radiofrequency use |
|---|---|---|---|---|---|
| Park et al. [44] | Rotator cuff disease | Introduction of a novel technique within arthroscopic rotator cuff repair | Unspecified | Unspecified | Minor |
| Shon et al. [45] | Rotator cuff disease | To describe a novel tenodesis performed via an arthroscopic suture anchor technique | Bisector Arthro Wand (Arthrocare) | Coblation | Minor |
| Petri et al. [46] | Rotator cuff disease | To describe a novel technique for open reduction internal fixation for posterosuperior rotator cuff repair and latissimus dorsi transfer | Super TurboVac 90 (Arthrocare) | Coblation | Minor |
| Laskovski et al. [47] | Rotator cuff disease | To introduce a novel technique in arthroscopic augmentation of rotator cuff repair with an acellular human dermal allograft | Unspecified | Unspecified | Minor |
| Cabarcas et al. [48] | Rotator cuff disease | To describe the surgical technique of a "double-row "arthroscopic subscapularis repair | Super TurboVac 90 (Arthrocare) | Coblation | Minor |
| Chernchujit et al. [49] | Rotator cuff disease | To present a novel arthroscopic technique for the management of high graded bursal sided rotator cuff tears | Super TurboVac 90 (Arthrocare) | Coblation | Minor |
| Boutsiadis et al. [16] | Rotator cuff disease | To propose a modification of superior capsular reconstruction with a long head bicep autograft | Super TurboVac 90 (Arthrocare) | Coblation | Minor |
| Warth et al. [50] | Sternoclavicular joint disease | To describe a novel technique for arthroscopic sternoclavicular joint resection | Unspecified | Unspecified | Minor |
| Yamakado et al. [51] | Suprascapular nerve entrapment | To quantify the learning curve using the log-linear model for arthroscopic suprascapular nerve decompression | Unspecified | Unspecified | Minor |
| Thompson et al. [12] | Adhesive capsulitis | To propose a novel technique for performing an arthroscopic capsular release | DYONICS EFLEX (Arthrocare) | Monopolar | Major |

studies [16,44-49,69]. All four studies reporting these adverse events specify second-degree burns as related to direct contact of the irrigation fluid from outflow tubing rather than from contiguous, elevated intraarticular temperatures [65-68]. Dermal burns have been reported during subacromial decompression [66]. Surgeons, however, plugged fluid outflow to increase the joint tamponade effect for better visibility, resulting in overheated irrigation fluid that burned the patient [66]. To decrease the burn risk, it is recommended that suction surveillance and high fluid outflow be maintained by surgeons [68].

## DISCUSSION

In this systematic review of the literature, 63 studies demonstrated the safety and efficacy of RF devices within the shoulder. Of these, 25 studies explicitly studied the temperature profile, safety profile, or clinical outcomes. Though the temperature and safety profile were reasonably well described, functional or patient-reported outcomes after RF treatment were sparse [10,11,13-19,22,23,25-27,29-33,35,39-45,49-51].

Our study demonstrated that the landscape of shoulder RF has changed significantly since it was originally studied in the context of shoulder instability [1,7,9]. Given the unanimous findings of poor outcomes in this setting, RF is largely used for debriding soft tissue (Table 3). Yasura et al. [70] demonstrated that bipolar RF resulted in significantly less chondrocyte death than unipolar RF in the knee. The results of our systematic review seem to be in concordance with this and demonstrate a general trend toward


https://doi.org/10.5397/cise.2022.01067

**Table 4.** Included studies for which the temperature profile was the primary outcome with regards to radiofrequency usage in the shoulder

| Study | Radiofrequency device used | Radiofrequency mode | Study type | Level of evidence | Number of patients | Use | Purpose | Main outcome | Conclusion |
|---|---|---|---|---|---|---|---|---|---|
| Faruque et al. [52] | Stryker Endoscopy Radio Frequency Ablation System (SERFAS) (Stryker, Portage, MI, USA) or Super Turbovac 90 (Arthrocare; Smith & Nephew, Austin, TX, USA) | Bipolar and Coblation | Randomized control trial | I | 40 | Rotator cuff repair | To compare intraarticular temperature profile in standard ablation versus plasma ablation RF devices for arthroscopic rotator cuff repair | Although 7 patients registered temperatures above 45 °C, no significant differences in intraarticular temperature were found between standard and plasma RF devices (P = 0.433). | Plasma ablation radiofrequency may be equivalent to standard radiofrequency. Further study is needed to determine the safety profile of plasma radiofrequency. |
| Gereli et al. [53] | Super Turbovac 90 (Arthrocare) | Coblation | Prospective cohort study | II | 41 | Subacromial decompression | To investigate the effect of irrigation fluid temperature on joint temperatures during shoulder surgery | The measured maximum temperature between the group receiving irrigation fluid of 34 °C and the group receiving 24 °C irrigation fluid was not statistically significantly different with a mean rise of 7.34 °C ± 0.7 °C with concurrent RF use. | Irrigation fluid temperature may not influence intraarticular temperature during shoulder surgery. New generation coblation devices may have a safe temperature profile. |
| Chivot et al. [54] | Ambient Super Turbovac 90 (Arthrocare) | Coblation | Prospective cohort study | II | 22 | Subacromial decompression/ rotator cuff surgery | To determine the effect of surgery site, radiofrequency modality, and other surgical details on intraarticular temperature during arthroscopic shoulder surgery | Additional portal sites reduced the temperature elevation by 3.8 °C (P < 0.05) when concurrent radiofrequency was used. Arthropump pressure plays a significant role in the intraarticular temperature as well (P < 0.05). No significant difference was found regarding radiofrequency modality choice. | It is important to be cognizant of the variables that can affect intraarticular temperature during arthroscopic shoulder surgery. Radiofrequency modality may or may not be as important as other factors. |

(Continued to the next page)

**Table 4.** Continued

| Study | Radiofrequency device used | Radiofrequency mode | Study type | Level of evidence | Number of patients | Use | Purpose | Main outcome | Conclusion |
|---|---|---|---|---|---|---|---|---|---|
| Huynh et al. [3] | Super Turbovac 90 (Arthrocare) and VAPR Mitek (DePuy Mitek, Raynham, MA, USA) | Coblation | Prospective controlled trial | II | 13 | Subacromial decompression | To investigate the temperature profile during arthroscopy within the subacromial space | No difference in temperature profile was demonstrated between VAPR and coblation within the first 40 seconds ($P > 0.05$). After 40 seconds, coblation temperatures were higher than VAPR ($P < 0.05$). All trials displayed temperatures below the chondrocyte threshold damage of 45 °C. | There is minimal concern for temperature violation with both VAPR and coblation. |
| Barker et al. [55] | Super Turbovac 90 (Arthrocare) | Coblation | Case series | IV | 15 | Subacromial decompression | To investigate if the bipolar RF ablation wand causes excess heating | The mean peak temperature was 32.0 °C in the subacromial bursa and 71.6 °C in the outflow fluid during arthroscopic subacromial decompression. Baseline temperature of irrigation fluid most influenced bursal temperature | Bipolar RF can be safely used below the temperature threshold in the shoulder. |
| Davies et al. [56] | Ablator-S (Arthrocare) | Monopolar | Case series | IV | 30 | Impingement syndrome | To assess subacromial space temperatures during RF ablation of subacromial bursa | Both the mean and maximum temperatures reached in 30 case series patients were below the experimental thresholds for chondrocyte damage. | Radiofrequency can be used safely in the shoulder below the temperature limit. |

(Continued to the next page)



https://doi.org/10.5397/cise.2022.01067

**Table 4.** Continued

| Study | Radiofrequency device used | Radiofrequency mode | Study type | Level of evidence | Number of patients | Use | Purpose | Main outcome | Conclusion |
|---|---|---|---|---|---|---|---|---|---|
| Zoric et al. [57] | Super Turbovac (Arthrocare) | Coblation | Cadaveric study (10 cadavers) | NA | NA | NA | To investigate factors that impact joint temperature profiles with RF usage | Three factors are crucial in influencing joint capsule temperature: application duration, application distance, and flow rate, with the flow rate being the most important factor. | Maintaining appropriate joint temperature during shoulder radiofrequency treatment is important. These factors better enable clinicians to do so. |
| Good et al. [58] | VAPR3 (DePuy Mitek) | Bipolar | Cadaveric study (30 cadavers) | NA | NA | NA | To assess glenohumeral fluid temperature during shoulder arthroscopy and the effect RF energy has upon it | In this cadaveric study using VAPR3, joint temperatures rose above 45 °C in all trials. A flow rate of 100% had reduced temperatures compared to a flow rate of 0%. | Bipolar radiofrequency has the potential to raise the intraarticular temperature, which can be detrimental to chondrocyte viability. Clinicians must keep this in mind while pursuing radiofrequency treatment in the shoulder. |
| Edwards et al. [59] | ArthroCare System 2000 (Arthrocare) and Vulcan EAS | Monopolar | Animal study | NA | NA | NA | To compare and contrast cartilage matrix temperatures between the monopolar and bipolar RF energy devices | Monopolar RF devices were associated with lower temperatures and at greater depths within the cartilage | Monopolar radiofrequency can be safely used without violating the temperature limit of the shoulder. |

(Continued to the next page)

**Table 4.** Continued

| Study | Radiofrequency device used | Radiofrequency mode | Study type | Level of evidence | Number of patients | Use | Purpose | Main outcome | Conclusion |
|---|---|---|---|---|---|---|---|---|---|
| Valet et al. [60] | SuperTurbo Vac 90 (Arthrocare) | Coblation | Basic science study | NA | NA | NA | To determine an optimal technique for prevention of damaging suture material in RF tissue ablation | High-strength ultra-high molecular weight polyethylene sutures were less sensitive to RF treatment than polyester sutures. By maintaining the distance between the probe and suture, damage can be reduced to sutures. | Suture choice can affect the safety of radiofrequency treatment in the shoulder. |
| Shah et al. [61] | Orthopedic Procedure Electrosurgical System (Arthrex, Naples, FL, USA) | Monopolar | Basic science study | NA | NA | NA | To evaluate different sutures and the effect RF energy exerts on their mechanical properties | This study demonstrates that exposure to electrocautery damages and weakens sutures. | Radiofrequency has the potential to affect the integrity of all sutures tested and should be used with care around sutures. |
| Lemos et al. [20] | Ambient Super TurboVac 90 (Arthrocare) | Coblation | Cadaveric study (17 specimens) | NA | NA | Biceps tenodesis or tenotomy | To describe a novel technique of outlet biceps tenodesis | In comparison to traditional tenotomy on cadavers, biomechanical testing showed favorable pullout force results from this technique. | Radiofrequency use was used in a novel biceps tenodesis technique that did not result in any adverse effects. |
| Ficklscherer et al. [62] | OPES CoolCut (Arthrex) | Bipolar | Animal study (189 rats undergoing rotator cuff repair) | NA | NA | NA | To investigate footprint preparations in rotator cuff repair along with their histological and biomechanical outcomes | RF in comparison to spongialisation of the footprint was associated with poorer biomechanical and histological outcomes. | RF cannot be advised in place of spongialisation for rotator cuff repair. |

RF: radiofrequency, NA: not applicable.


https://doi.org/10.5397/cise.2022.01067

**Table 5.** Studies included within the review article that investigated complications and safety profile of radiofrequency use in the shoulder

| Study | Radiofrequency device | Radiofrequency mode | Study type | Level of evidence | Number of patients | Use | Purpose | Main outcome | Conclusion |
|---|---|---|---|---|---|---|---|---|---|
| Nho et al. [21] | VAPR Mitek (DePuy Mitek, Raynham, MA) and OraTec Vulcan EAS (OraTec, Manassas, VA, USA) | Bipolar | Prospective randomized clinical trial | I | 50 | Varied | To investigate if RF energy devices originally from coagulation and soft tissue ablation cause thermal injury to the bone | With MRI, no cases of osteonecrosis or bone edema occurred with monopolar or bipolar RF devices. | There may not be any injury or insult that is detectable on imaging studies after utilization of radiofrequency in the shoulder. |
| Jerosch et al. [63] | VAPR (DePuy Mitek) | Bipolar | Case report | IV | 1 | Capsular release | To present a case of chondrolysis post arthroscopic capsular release for adhesive capsulitis with a bipolar VAPR RF energy probe | Glenohumeral chondrolysis occurred after treatment with the bipolar VAPR RF probe, although rare. A surface replacement was required. | Chondrolysis can occur as a complication of bipolar radiofrequency in the shoulder. |
| Bonsell et al. [64] | Unspecified device | Bipolar | Case report | IV | 1 | Subacromial decompression | To present a case of deltoid detachment that occurred during arthroscopic subacromial decompression | Overaggressive use of the bipolar RF was attributed to deltoid detachment by the authors. | Bipolar radiofrequency use is not without its risks. The practicing shoulder surgeon needs to be aware of these risks. |
| Troxell et al. [65] | SuperTurbo Vac 90 (Arthrocare; Smith & Nephew,Austin, TX, USA) | Coblation | Case series | IV | 4 | Subacromial decompression | To present reports of shoulder arthroscopy bipolar RF-induced burn injuries within patients | Four patients over 4 years suffered second-degree burns after irrigation fluid from outflow tubing contacted the patients. | Orthopedic surgeons need to be cognization of burn risk during radiofrequency of the shoulder. |
| Chahar et al. [66] | VAPR (DePuy Mitek) | Bipolar | Case report | IV | 1 | Rotator cuff repair | To present a dermal burn case that occurred after a radiofrequency procedure | The suction device was removed leading intraarticular fluid temperature to increase. Dermal burns occurred as a consequence of RF subacromial decompression. | Practitioners need to be aware of the complication of thermal burns. |

(Continued to the next page)

**Table 5.** Continued

| Study | Radiofrequency device | Radiofrequency mode | Study type | Level of evidence | Number of patients | Use | Purpose | Main outcome | Conclusion |
|---|---|---|---|---|---|---|---|---|---|
| Talati et al. [67] | Stryker endoscopy radio Frequency Ablation System (Stryker Endoscopy Radio Frequency Ablation System [SERFAS]; Stryker, Portage, MI, USA) | Bipolar | Case report | IV | 1 | Impingement syndrome | To describe a report of skin burn from contact with an RF device with a spinal needle during acromioplasty | A patient received skin burns from the contact of the spinal needle with the RF device during an arthroscopic subacromial decompression. | Orthopedic surgeons should use caution when using radiofrequency in order to minimize the risk of superficial dermal burns. |
| Kouk et al. [68] | SuperTurbo Vac 90 (Arthrocare) | Coblation | Case report | IV | 1 | Subacromial decompression | To report a case of overheating irrigation fluid from RF causing second-degree burns on the patient's chest wall and shoulder | Author details forgetting to close the valve and place the suction, thus allowing heated irrigation fluid to drip onto the patient and cause second-degree burns. | Bipolar radiofrequency use is not without its risks, which are increased by user error. |

RF: radiofrequency, MRI: magnetic resonance imaging.

the use of bipolar RF in recent years. Though a few studies in our literature review demonstrate adverse thermal effect profiles, these are limited to case reports [65-67], case series, and cadaveric studies [58]. Shoulder joint temperature increases with the use of RF technologies [3,55,58]. The flow of irrigation fluid [55,57,58], length of application [55,57], device used [3], and proximity of the thermometer to the RF wand [57,58] all impact the temperature profile.

The incidence of RF complications was appropriately reported [21,63-68,71] and generally comprised superficial burns related to fluid irrigation temperature [65-68]. All of the Level III or higher studies reporting temperature profile demonstrate a favorable profile (Table 5). This is in concordance with the literature on RF use in the knee [1,5] and hip [6]. Maintenance of inflow and outflow circulation, avoidance of plugged arthroscopic fluid outflow, avoidance of excess use of coagulation mode [54], and monitoring overheating of the tubing can be performed to reduce burn complications with RF in the shoulder. It is well known that cartilage is more heat-sensitive than other tissues in the human body, and this must be considered when treating cartilage lesions [1].

It is important to consider economic efficiency when determining the RF modality of choice. Efficiency and cost between monopolar RF and bipolar RF in 40 arthroscopic subacromial decompression patients were investigated by Diab et al. [72]. The mean operative time in the bipolar group was 13 minutes (5–25 minutes), while it was 21 minutes (10–35 minutes) for the monopolar RF device group. Bipolar RF decreased the average procedure time by 8 minutes ($p < 0.0001$), while simultaneously decreasing cost by 83 British Pounds (111 European Euros) per case ($p < 0.003$) in comparison to monopolar RF [72]. Based on these results, the authors recommended bipolar RF when clinical judgment deems it appropriate.

This systematic review is not without its limitations. As a systematic review of level I–level IV evidence, the findings are limited to level IV. Due to heterogeneous data reporting, this is a comprehensive summary of all studies delineating the use of RF in the shoulder as defined by the inclusion and exclusion criteria. However, many of the studies included were limited by unspecified use of RF. Further, our study is unable to comment on the clinical outcomes of RF based on the inclusion criteria regarding temperature profile and safety/complications of shoulder RF. The results pertaining to safety and complication are based on a limited subset of select articles. Thus, the findings of this study may be limited by selection bias.


https://doi.org/10.5397/cise.2022.01067

## CONCLUSIONS

Shoulder RF has a wide scope of application in various shoulder pathologies. Although shoulder RF is safe, it requires practitioners to be cognizant of the potential for thermal burn injuries. Protocols regarding irrigation fluid temperature and outflow rates should be set by individual institutions to further reduce minor patient complications of shoulder RF. Future research is required to determine measures to minimize further the risk of thermal burn injuries.

## NOTES

**ORCID**

Neeraj Vij https://orcid.org/0000-0002-7214-0411

**Author contributions**

Conceptualization: NV, JNL, NA. Data curation: NV, JNL, NA. Formal Analysis: NV, JNL, NA. Investigation: NV, JNL, NA. Methodology: NV, JNL, NA. Project administration: JNL, NA. Resources: NV, JNL, NA. Software: NV, JNL, NA. Supervision: JNL, NA. Validation: NV, JNL, NA. Visualization: NV, JNL, NA. Writing – original draft: NV, JNL, NA. Writing – review & editing: NV, JNL, NA.

**Conflict of interest**

None.

**Funding**

None.

**Data availability**

None.

**Acknowledgments**

None.

## REFERENCES

1. Anderson SR, Faucett SC, Flanigan DC, Gmabardella RA, Amin NH. The history of radiofrequency energy and Coblation in arthroscopy: a current concepts review of its application in chondroplasty of the knee. J Exp Orthop 2019;6:1.
2. Lu Y, Zhang Q, Zhu Y, Jiang C. Is radiofrequency treatment effective for shoulder impingement syndrome?: a prospective randomized controlled study. J Shoulder Elbow Surg 2013;22:1488–94.
3. Huynh V, Barbier O, Bajard X, Bouchard A, Ollat D, Versier G. Subacromial temperature profile during bipolar radiofrequency use in shoulder arthroscopy: comparison of Coblation® vs. VAPR®. Orthop Traumatol Surg Res 2017;103:489–91.
4. Peng L, Li Y, Zhang K, et al. The time-dependent effects of bipolar radiofrequency energy on bovine articular cartilage. J Orthop Surg Res 2020;15:106.
5. Kosy JD, Schranz PJ, Toms AD, Eyres KS, Mandalia VI. The use of radiofrequency energy for arthroscopic chondroplasty in the knee. Arthroscopy 2011;27:695–703.
6. Schenker ML, Philippon MJ. The role of flexible radiofrequency energy probes in hip arthroscopy. Tech Orthop 2005;20:37–44.
7. Hayashi K, Markel MD. Thermal capsulorrhaphy treatment of shoulder instability: basic science. Clin Orthop Relat Res 2001;(390):59–72.
8. Hawkins RJ, Krishnan SG, Karas SG, Noonan TJ, Horan MP. Electrothermal arthroscopic shoulder capsulorrhaphy: a minimum 2-year follow-up. Am J Sports Med 2007;35:1484–8.
9. D'Alessandro DF, Bradley JP, Fleischli JE, Connor PM. Prospective evaluation of thermal capsulorrhaphy for shoulder instability: indications and results, two- to five-year follow-up. Am J Sports Med 2004;32:21–33.
10. Cvetanovich GL, Leroux TS, Bernardoni ED, et al. Clinical outcomes of arthroscopic 360° capsular release for idiopathic adhesive capsulitis in the lateral decubitus position. Arthroscopy 2018;34:764–70.
11. Li T, Yang ZZ, Deng Y, Xiao M, Jiang C, Wang JW. Indirect transfer of the sternal head of the pectoralis major with autogenous semitendinosus augmentation to treat scapular winging secondary to long thoracic nerve palsy. J Shoulder Elbow Surg 2017;26:1970–7.
12. Thompson SR, Lebel ME. Use of a hip arthroscopy flexible radiofrequency device for capsular release in frozen shoulder. Arthrosc Tech 2012;1:e75–8.
13. Arce G. Primary frozen shoulder syndrome: arthroscopic capsular release. Arthrosc Tech 2015;4:e717–20.
14. Cvetanovich GL, Leroux T, Hamamoto JT, Higgins JD, Romeo AA, Verma NN. Arthroscopic 360° capsular release for adhesive capsulitis in the lateral decubitus position. Arthrosc Tech 2016;5:e1033–8.
15. Parada SA, Shaw KA. Graft transfer technique in arthroscopic posterior glenoid reconstruction with distal tibia allograft. Arthrosc Tech 2017;6:e1891–5.
16. Boutsiadis A, Chen S, Jiang C, Lenoir H, Delsol P, Barth J. Long head of the biceps as a suitable available local tissue autograft for superior capsular reconstruction: "the Chinese way". Arthrosc Tech 2017;6:e1559–66.

17. Saithna A, Longo A, Leiter J, MacDonald P, Old J. Biceps tenoscopy: arthroscopic evaluation of the extra-articular portion of the long head of biceps tendon. Arthrosc Tech 2016;5:e1461–5.
18. Su WR, Ling FY, Hong CK, Chang CH, Chung KC, Jou IM. An arthroscopic technique for long head of biceps tenodesis with double knotless screw. Arthrosc Tech 2015;4:e375–8.
19. Valenti P, Benedetto I, Maqdes A, Lima S, Moraiti C. "Relaxed" biceps proximal tenodesis: an arthroscopic technique with decreased residual tendon tension. Arthrosc Tech 2014;3:e639–41.
20. Lemos D, Esquivel A, Duncan D, Marsh S, Lemos S. Outlet biceps tenodesis: a new technique for treatment of biceps long head tendon injury. Arthrosc Tech 2013;2:e83–8.
21. Nho SJ, Freedman KB, Bansal SL, et al. The effect of radiofrequency energy on nonweight-bearing areas of bone following shoulder and knee arthroscopy. Orthopedics 2005;28:392–9.
22. Baumgarten KM, Altchek DW, Cordasco FA. Arthroscopically assisted acromioclavicular joint reconstruction. Arthroscopy 2006;22:228.
23. Katthagen JC, Anavian J, Tahal DS, Millett PJ. Arthroscopic remplissage and open latarjet procedure for the treatment of anterior glenohumeral instability with severe bipolar bone loss. Arthrosc Tech 2016;5:e1135–41.
24. Ganokroj P, Keyurapan E. Arthroscopic bony bankart repair using a double-row double-pulley technique. Arthrosc Tech 2018;8:e31–6.
25. Lewington MR, Urquhart N, Wong IH. Lateral decubitus all-arthroscopic Latarjet procedure for treatment of shoulder instability. Arthrosc Tech 2015;4:e207–13.
26. Gomes N, Hardy P, Bauer T. Arthroscopic treatment of chronic anterior instability of the shoulder in Marfan's syndrome. Arthroscopy 2007;23:110.
27. Shih CA, Chiang FL, Hong CK, et al. Arthroscopic transtendinous biceps tenodesis with all-suture anchor. Arthrosc Tech 2017;6:e705–9.
28. Daggett M, Stepanovich B, Meyers A, Geraghty B. Arthroscopic on-lay biceps tenodesis: the loop-lock technique. Arthrosc Tech 2019;8:e935–9.
29. Saithna A, Longo A, Leiter J, MacDonald P, Old J. Safety of the "inside-out" radiofrequency ablation technique for rapid localization of the biceps tendon in the subacromial space. Tech Shoulder Elbow Surg 2016;17:98–9.
30. Armangil M, Akan B, Basarir K, Bilgin SS, Gürcan S, Demirtas M. Arthroscopic release of the subscapularis for shoulder contracture of obstetric palsy. Eur J Orthop Surg Traumatol 2012;22:25–8.
31. Li X, Padmanabha A, Koh J, Cusano A. All-arthroscopic coracoclavicular ligament reconstruction surgical technique using a semitendinosus allograft and tenodesis screws. Arthrosc Tech 2017;6:e413–7.
32. Yalizis M, Kruse K 2nd, Godenèche A. Arthroscopic "panorama" view of the subacromial space via deltoid fascia release. Arthrosc Tech 2016;5:e935–9.
33. Pagán Conesa A, Verdú Aznar C, Herrera MR, Lopez-Prats FA. Arthroscopic marginal resection of a lipoma of the supraspinatus muscle in the subacromial space. Arthrosc Tech 2015;4:e371–4.
34. O'Brien SJ, Taylor SA, DiPietro JR, Newman AM, Drakos MC, Voos JE. The arthroscopic "subdeltoid approach" to the anterior shoulder. J Shoulder Elbow Surg 2013;22:e6–10.
35. Mellano CR, Virk MS, Shin JJ, Aiyash S, Romeo AA. Tips and technical pearls for performing an arthroscopic acromioplasty in a reproducible and accurate manner. Tech Shoulder Elbow Surg 2015;16:59–62.
36. Valenti P, Maroun C, Schoch B, Arango SO, Werthel JD. Arthroscopic Trillat coracoid transfer procedure using a cortical button for chronic anterior shoulder instability. Arthrosc Tech 2019;8:e199–204.
37. Hendrix ST, Hoyle M, Tokish JM. Arthroscopic pectoralis minor release. Arthrosc Tech 2018;7:e589–94.
38. Theopold J, Marquass B, von Dercks N, et al. Arthroscopically guided navigation for repair of acromioclavicular joint dislocations: a safe technique with reduced intraoperative radiation exposure. Patient Saf Surg 2015;9:41.
39. Scheibel M, Ifesanya A, Pauly S, Haas NP. Arthroscopically assisted coracoclavicular ligament reconstruction for chronic acromioclavicular joint instability. Arch Orthop Trauma Surg 2008;128:1327–33.
40. Almazan A, Sierra L, Cruz F, et al. Arthroscopic transarticular distal clavicle resection. Tech Shoulder Elbow Surg 2006;7:206–9.
41. Boileau P, McClelland WB Jr, O'Shea K, et al. Arthroscopic Hill-Sachs remplissage with Bankart repair: strategy and technique. JBJS Essent Surg Tech 2014;4:e4.
42. Rausch V, Königshausen M, Schildhauer TA, Seybold D, Gessmann J. Arthroscopic lateral border resection in medialized scapula neck fractures. Arthrosc Tech 2017;6:e1619–23.
43. Bhatia DN, de Beer JF, van Rooyen KS, du Toit DF. Arthroscopic suprascapular nerve decompression at the suprascapular notch. Arthroscopy 2006;22:1009–13.
44. Park YB, Park YE, Koh KH, Lim TK, Shon MS, Yoo JC. Subscapularis tendon repair using suture bridge technique. Arthrosc Tech 2015;4:e133–7.
45. Shon MS, Koh KH, Lim TK, Lee SW, Park YE, Yoo JC. Arthroscopic suture anchor tenodesis: loop-suture technique. Ar-


https://doi.org/10.5397/cise.2022.01067

throsc Tech 2013;2:e105–10.
46. Petri M, Greenspoon JA, Millett PJ. Arthroscopic superior capsule reconstruction for irreparable rotator cuff tears. Arthrosc Tech 2015;4:e751–5.
47. Laskovski J, Abrams J, Bogdanovska A, Taliwal N, Taylor M, Fisher M. Arthroscopic rotator cuff repair with allograft augmentation: making it simple. Arthrosc Tech 2019;8:e597–603.
48. Cabarcas BC, Garcia GH, Liu JN, Gowd AK, Romeo AA. Double-row arthroscopic subscapularis repair: a surgical technique. Arthrosc Tech 2018;7:e805–9.
49. Chernchujit B, Shahul Hamid MA, Aimprasittichai S. Knotless suture bridge technique in high-grade bursal-sided rotator cuff tears: is this the way forward. Arthrosc Tech 2017;6:e2259–63.
50. Warth RJ, Lee JT, Millett PJ. Figure-of-eight tendon graft reconstruction for sternoclavicular joint instability: biomechanical rationale, surgical technique, and a review of clinical outcomes. Oper Tech Sports Med 2014;22:260–8.
51. Yamakado K. Quantification of the learning curve for arthroscopic suprascapular nerve decompression: an evaluation of 300 cases. Arthroscopy 2015;31:191–6.
52. Faruque R, Matthews B, Bahho Z, et al. Comparison between 2 types of radiofrequency ablation systems in arthroscopic rotator cuff repair: a randomized controlled trial. Orthop J Sports Med 2019;7:2325967119835224.
53. Gereli A, Kocaoglu B, Guven O, Turkmen M. Warm irrigation fluid does not raise the subacromial temperature to harmful levels while using radiofrequency device. Int J Shoulder Surg 2015;9:99–100.
54. Chivot M, Airaudi S, Galland A, Gravier R. Analysis of parameters influencing intraarticular temperature during radiofrequency use in shoulder arthroscopy. Eur J Orthop Surg Traumatol 2019;29:1205–10.
55. Barker SL, Johnstone AJ, Kumar K. In vivo temperature measurement in the subacromial bursa during arthroscopic subacromial decompression. J Shoulder Elbow Surg 2012;21:804–7.
56. Davies H, Wynn-Jones H, De Smet T, Johnson P, Sampath S, Sjølin S. Fluid temperatures during arthroscopic subacromial decompression using a radiofrequency probe. Acta Orthop Belg 2009;75:153–7.
57. Zoric BB, Horn N, Braun S, Millett PJ. Factors influencing intra-articular fluid temperature profiles with radiofrequency ablation. J Bone Joint Surg Am 2009;91:2448–54.
58. Good CR, Shindle MK, Griffith MH, Wanich T, Warren RF. Effect of radiofrequency energy on glenohumeral fluid temperature during shoulder arthroscopy. J Bone Joint Surg Am 2009;91:429–34.
59. Edwards RB 3rd, Lu Y, Markel MD. The basic science of thermally assisted chondroplasty. Clin Sports Med 2002;21:619–47.
60. Valet S, Weisse B, Fischer B, Meyer DC. Mechanical effects of heat exposure from a bipolar radiofrequency probe on suture under simulated arthroscopic conditions. Arthroscopy 2016;32:1985–92.
61. Shah AA, Kang P, Deutsch A. Radiofrequency and its effect on suture strength. Orthopedics 2009;32:894.
62. Ficklscherer A, Serr M, Loitsch T, et al. The influence of different footprint preparation techniques on tissue regeneration in rotator cuff repair in an animal model. Arch Med Sci 2017;13:481–8.
63. Jerosch J, Aldawoudy AM. Chondrolysis of the glenohumeral joint following arthroscopic capsular release for adhesive capsulitis: a case report. Knee Surg Sports Traumatol Arthrosc 2007;15:292–4.
64. Bonsell S. Detached deltoid during arthroscopic subacromial decompression. Arthroscopy 2000;16:745–8.
65. Troxell CR, Morgan CD, Rajan S, Leitman EH, Bartolozzi AR. Dermal burns associated with bipolar radiofrequency ablation in the subacromial space. Arthroscopy 2011;27:142–4.
66. Chahar D, Chawla A, Verma N, Mittal A, Pankaj A. Dermal burn: an unusual complication of radio frequency probe in shoulder arthroscopy. J Arthrosc Joint Surg 2017;4:38–40.
67. Talati RK, Dein EJ, Huri G, McFarland EG. Cutaneous burn caused by radiofrequency ablation probe during shoulder arthroscopy. Am J Orthop (Belle Mead NJ) 2015;44:E58–60.
68. Kouk SN, Zoric B, Stetson WB. Complication of the use of a radiofrequency device in arthroscopic shoulder surgery: second-degree burn of the shoulder girdle. Arthroscopy 2011;27:136–41.
69. Jang JS, Choi HJ, Kang SH, Yang JS, Lee JJ, Hwang SM. Effect of pulsed radiofrequency neuromodulation on clinical improvements in the patients of chronic intractable shoulder pain. J Korean Neurosurg Soc 2013;54:507–10.
70. Yasura K, Nakagawa Y, Kobayashi M, Kuroki H, Nakamura T. Mechanical and biochemical effect of monopolar radiofrequency energy on human articular cartilage: an in vitro study. Am J Sports Med 2006;34:1322–7.
71. Taverna E, Battistella F, Sansone V, Perfetti C, Tasto JP. Radiofrequency-based plasma microtenotomy compared with arthroscopic subacromial decompression yields equivalent outcomes for rotator cuff tendinosis. Arthroscopy 2007;23:1042–51.
72. Diab MA, Fernandez GN, Elsorafy K. Time and cost savings in arthroscopic subacromial decompression: the use of bipolar versus monopolar radiofrequency. Int Orthop 2009;33:175–9.

Current Concept

Clin Shoulder Elbow 2023;26(4):438-444
https://doi.org/10.5397/cise.2023.00514

CiSE
Clinics in Shoulder and Elbow

eISSN 2288-8721

# Superior capsular reconstruction for irreparable rotator cuff tear: a review of current methods

**Seok Won Chung[1], Dong-Hyun Kim[2], Hyun Joo Lee[2], Won Ki Hong[2], Seung Ho Chung[2], Jong Pil Yoon[2]**

[1]*Department of Orthopedic Surgery, Konkuk University Medical Center, Seoul, Korea*
[2]*Department of Orthopedic Surgery, Kyungpook National University Hospital, Daegu, Korea*

Irreparable massive rotator cuff tears can significantly impact daily life; and these types of tears can be difficult to repair completely, especially in younger patients who are more active and have higher functional requirements. Since its introduction by Mihata and the colleagues, superior capsular reconstruction (SCR) has gained popularity in the treatment of irreparable massive rotator cuff tears and has shown promising short-term results. A variety of studies have focused on the clinical and biomechanical outcomes of this procedure. This article reviews the biomechanics, indications for the surgical procedure, graft options, surgical technique, and rehabilitation from SCR.

**Keywords:** Shoulder; Rotator cuff; Massive; Reconstruction

## INTRODUCTION

Irreparable massive rotator cuff tears are a serious, painful problem that can significantly impact daily life. Routine tasks such as bathing, dressing, sleeping, housework, meal preparation, overhead activities, and work present challenges. These types of tears can be difficult to repair completely and have a high risk of re-rupture, leading to poor postoperative results. For elderly patients with fewer functional requirements, several surgical options are available; but these options are not as suitable for younger patients who have higher functional requirements. Younger patients can only be treated with tendon transfer or patch augmentation. Reverse total shoulder arthroplasty is effective in elderly patients with severe rotator cuff tears but has a high rate of complications and failure in younger, active patients under the age of 65. For this group, this procedure is not a long-term solution [1].

Superior capsular reconstruction (SCR), a surgical technique using autologous tissue or allograft that was first proposed by Mihata et al. [2], has gained popularity in treatment of irreparable rotator cuff tears and has shown promising short-term results. Many research efforts have focused on the clinical and biomechanical outcomes of this procedure. One prior study indicated that the procedure has the potential to decrease pressure on the acromion, enhance humeral translation, and yield favorable clinical outcomes in the short term [3]. The purpose of this article is to review the biomechanics associated with the procedure; indications for performing the procedure; graft type, thickness, size, and tensioning; surgical technique; and rehabilitation from the procedure.

## BIOMECHANICS

In the glenohumeral joint, rotator cuff muscles and the deltoid

Received: June 22, 2023 Revised: August 20, 2023 Accepted: August 30, 2023
Correspondence to: Jong Pil Yoon
Department of Orthopedic Surgery, Kyungpook National University Hospital, School of Medicine, Kyungpook National University, 130 Dongdeok-ro, Jung-gu, Daegu 41944, Korea
Tel: +82-53-200-5628, Fax: +82-53-422-6605, E-mail: altjp1@gmail.com, ORCID: https://orcid.org/0000-0001-6446-6254

Copyright© 2023 Korean Shoulder and Elbow Society.
This is an Open Access article distributed under the terms of the Creative Commons Attribution Non-Commercial License (http://creativecommons.org/licenses/by-nc/4.0/) which permits unrestricted non-commercial use, distribution, and reproduction in any medium, provided the original work is properly cited.

muscle cooperate to maintain the shoulder joint balanced. The rotator cuff helps stabilize the joint and prevents the humeral head from moving upwards when the deltoid muscle contracts. A massive tear in the rotator cuff can disrupt the balance of forces in the shoulder, causing superior humeral head migration and altering the amount and direction of force at the shoulder joint. This imbalance in the shoulder joint due to a massive tear can make lifting and moving the arm difficult and decrease the overall function of the shoulder joint. If the imbalance continues, further damage to the rotator cuff and degeneration of the shoulder joint are the result [4].

Beneath the rotator cuff, a thin layer of continuous collagen sheet, the superior capsule, is present. This capsule extends from the glenoid labrum medially to the humerus laterally. A previous anatomical study showed that maximum capsular thickness should be 9.1 mm at its attachment to the greater tuberosity for stabilizing superior humeral head translation [5]. Ishihara et al. [6] previously demonstrated that the capsule also plays a significant role in glenohumeral joint function. The capsule is also completely torn in cases of massive rotator cuff tear, causing the superior migration of the humeral head. Therefore, reconstructing the superior capsule through SCR is an appropriate way to restore superior stability in the glenohumeral joint.

## SURGICAL INDICATIONS

There have been few SCR studies, and thus the indications for SCR surgery have not been thoroughly established. However, based on current evidence, SCR is a viable option for patients with massive and irreparable rotator cuff tears with severe muscle atrophy and fat infiltration. These patients should have minimal to no rotator cuff arthropathy (Hamada grade 1, 2). Young patients in whom RSA is not an acceptable option, particularly those with minimal rotator cuff tear arthropathy (Hamada grade 1, 2) in whom rotator cuff repair was unsuccessful, are candidates for SCR. Mihata et al. [7] demonstrated that SCR was able to reverse preoperative pseudoparalysis in patients with irreparable rotator cuff tears. Therefore, patients with preoperative pseudoparalysis who are not suited for RSA could be potential candidates for SCR. However, SCR is not recommended for patients who have severe cuff tear arthropathy (Hamada grade ≥3) or who have a non-functional deltoid muscle. When patients have severe cuff tear arthropathy, a SCR will not restore the glenohumeral joint space; affected patients can be better served with shoulder arthroplasty [8]. If deltoid function is insufficient, the force generated by the deltoid is weakened; and, as a result, the humeral head moves downward, the stability of the glenohumeral joint is damaged, and the acromiohumeral distance is widened. Thus, a functional deltoid is essential for SCR [9]. Further study is especially needed for elderly patients with irreparable rotator cuff tears without severe cuff tear arthropathy.

## GRAFT TYPE

Mihata et al. [2] initially reported using a fascia lata autograft for SCR. This method showed promising early results, but the thickness of the fascia lata graft was not sufficient and required doubling of the construct. Additionally, concerns were raised regarding potential complications at the donor site resulting from the large incision required for graft harvesting. Acellular dermal allografts have been suggested as an alternative. These are potentially stronger and virtually eliminate donor site morbidity [10]. Acellular dermal allografting has minimal immunologic risk, and these grafts have been shown to integrate well, provide a scaffold for neovascularization, and maintain structural integrity. The advantages of this graft include no donor site morbidity, ease of preparation, thickness and strength of the construct, and biologic incorporation. Several studies have reported on the biomechanical properties and clinical outcomes of these grafts. In a cadaveric study comparing two different types of grafts for use in SCR, a fascia lata allograft totally restored superior stability in the shoulder joint; however, an acellular dermal allograft only partially restored the stability [11]. Another biomechanical study compared the use of two different thicknesses of acellular dermal allografts in SCR. In this study, a graft with a thickness of 6 mm demonstrated superior restoration of joint position and forces compared to a graft with a thickness of 3 mm [12]. A third study compared three different types of grafts, fascia lata allograft, double layered acellular dermal allograft, and single layered acellular dermal allograft, used in SCR and found that all three were able to restore superior humeral translation and subacromial contact pressure and varying glenohumeral abduction angle. The fascia lata allograft and double layer dermal allograft were, however, more effective than the single layer dermal allograft [13]. Furthermore, the utilization of a 6-mm-thick dermal allograft proved to be equally effective as a fascia lata allograft in terms of restoring the subacromial space and minimizing peak subacromial contact pressures [14]. Mihata et al. [15] conducted a study to evaluate the clinical and radiological outcomes of SCR after 5 years of follow-up. The results showed that SCR was successful in restoring shoulder function and allowing patients to return to sports and work. None of the patients who experienced successful healing of the graft exhibited worsening of cuff tear arthropathy. However, three patients who experienced graft failure showed progression

of cuff tear arthropathy by the end of the 5-year follow-up period [15]. In a recent systematic review, five studies were analyzed. In two, the patients underwent a fascia lata autograft procedure; in the other three, the patients received an acellular dermal allograft. All the studies showed statistically significant improvements in active elevation, American Shoulder and Elbow Surgeons (ASES) score, and Constant score after a mean follow-up of 12 to 48 months postoperatively. The graft tear rate in those receiving a fascia lata autograft ranged from 5% to 32%, while the graft tear rate in those receiving an acellular dermal allograft ranged from 20% to 75% [16]. Another systematic review analyzed nine clinical studies involving the use of fascia lata autografts and human dermal allografts for SCR. The fascia lata autograft studies showed improvements in the ASES score, forward elevation, external rotation, and acromiohumeral distance. Acellular dermal allograft studies showed improvements in forward elevation, acromiohumeral distance, ASES score, and visual analog scale score [17]. Recently, some groups reported studies related to a new graft type based on the fascia lata autograft reinforced with a non-resorbable suture mesh that precludes the need for large amounts of fascia lata autograft. These studies showed improvements in clinical outcome scores and the range of motion [18]. Dermal allograft and fascia lata autograft for SCR showed similar improvements in results, and the rates of graft tear and reoperation were clinically similar. One notable disadvantage of fascia lata autograft is donor site morbidity, and recent advances such as minimally invasive harvesting have reduced the rates of donor site morbidity. Donor site morbidities include slightly lower functional scores of the affected thigh, subjective loss of strength, and local complications [19]. These results suggest that donor site morbidity after fascia lata autograft is an important consideration when choosing graft type but should not disqualify the use of fascia lata autograft for SCR. The previous studies regarding graft type are summarized in Tables 1 and 2 [16,18,20-35].

## GRAFT THICKNESS AND SIZE

A previous study reported that the thickness of the superior capsule ranged from 4.1 to 9.1 mm [5]. Biomechanically, using a fascia lata allograft that was either 4-mm- or 8-mm-thick reduced subacromial peak pressure. However, only an 8-mm-thick fascia lata allograft was successful in decreasing the superior translation of the shoulder joint [36]. A human dermal allograft with 6-mm thickness had equivalent results in terms of maximum abduction angle, subacromial peak pressure, superior translation, and cumulative force of the deltoid muscle compared to the normal state. However, comparing 3-mm-thick to 6-mm-thick allografts, there were significant differences in superior translation of the glenohumeral joint [12]. Also, a single 6-mm-thick acellular dermal allograft was just as effective as a 8-mm-thick fascia lata allograft in terms of peak subacromial pressures and acromiohumeral distance [14]. The results showed that the thickness of the graft material affects the amount of superior translation of the humeral head, and a graft thickness of 6 mm or more is optimal.

**Table 1.** Summary of previous clinical studies using tensor fascia-lata autograft for superior capsular reconstruction

| Study | Graft type | Graft thickness (mm) | Graft tensioning (position of shoulder during fixation) | Margin convergence | Fixation technique |
|---|---|---|---|---|---|
| Mihata et al. (2018) [20] | Tensor fascia lata autograft | 6–8 | 30°–45° Abduction | Yes (anterior, posterior) | Med, 2 anchors; Lat, 2 by 2 double row |
| Yoon et al. (2018) [21] | Tensor fascia lata autograft | NA | NA | Yes (anterior, posterior) | Med, 2 anchors; Lat, 2 by 2 double row |
| Lee and Min (2018) [22] | Tensor fascia lata autograft | 6 | 30° Abduction | Yes (posterior) | Med, 2 anchors; Lat, 2 anchors single row |
| Lim et al. (2019) [23] | Tensor fascia lata autograft | > 6 | NA | Yes (posterior) | Med, 2 or 3 anchors; Lat, 2 by 2 double row |
| Gracitelli et al. (2019) [24] | Tensor fascia lata allograft | 4–6 | 45° Abduction | Yes (posterior) | Med, 2 anchors; Lat, 2 anchors single row |
| de Campos Azevedo et al. (2020) [16] | Tensor fascia lata autograft | 5–8 | 10° Abduction | Yes (anterior, posterior) | Med, 2 anchors; Lat, 2 by 2 double row |
| Kholinne et al. (2020) [25] | Tensor fascia lata autograft with mesh | > 6 | NA | Yes (anterior, posterior) | Med, 3 anchors; Lat, 2 by 2 double row |
| Polacek et al. (2020) [18] | Tensor fascia lata autograft with mesh | 6–8 | 30° Abduction | Yes (anterior, posterior) | Med, 2 anchors; Lat, 2 by 2 double row |

Med: medial, Lat: lateral, NA: not available.


https://doi.org/10.5397/cise.2023.00514

**Table 2.** Summary of previous clinical studies using acellular dermal allograft for superior capsular reconstruction

| Study | Graft type | Graft thickness (mm) | Graft tensioning (position of shoulder during fixation) | Margin convergence | Fixation technique |
|---|---|---|---|---|---|
| Petri et al. (2015) [26] | Acellular dermal allograft | 3 | NA | Yes (anterior, posterior) | Med, 3 anchors; Lat, 2 by 2 double row |
| Sutter et al. (2017) [27] | Acellular dermal allograft | 3.5 | 30° Abduction | Yes (posterior) | Med, 2 anchors; Lat, 2 by 2 double row |
| Andersen et al. (2017) [28] | Acellular dermal allograft | 1.5, 3.5 | NA | Yes (anterior, posterior) | Med, 2 anchors; Lat, 2 by 2 double row |
| Pogorzelski et al. (2017) [29] | Acellular dermal allograft | 3 | NA | Not available | Not available |
| Denard et al. (2018) [30] | Acellular dermal allograft | 1–3 | 20°–30° Abduction | Yes (anterior, posterior) | Med, 2 anchors; Lat, 2 by 2 double row |
| Tokish et al. (2018) [31] | Acellular dermal allograft | NA | NA | Yes (posterior) | Med, 3 anchors; Lat, 2 anchors single row |
| Altintas et al. (2018) [32] | Acellular dermal allograft | 2.5 | NA | Yes (anterior, posterior) | Med, 3 anchors; Lat, 2 by 2 double row |
| Laskovski et al. (2018) [33] | Acellular dermal allograft | 3.5 | 30° Abduction | Yes (anterior, posterior) | Med, 2 anchors; Lat, 2 anchors single row |
| Pennington et al. (2018) [34] | Acellular dermal allograft | 3 | 45° Abduction | Yes (anterior, posterior) | Med, 3 anchors; Lat, 2 by 2 double row |
| Burkhart et al. (2020) [35] | Acellular dermal allograft | 3 | 20°–30° Abduction | Yes (anterior, posterior) | Med, 2 anchors; Lat, 2 by 2 double row |

NA: not available, Med: medial, Lat: lateral.

## GRAFT TENSIONING

Graft tensioning is important for proper glenohumeral contact fixation. According to recent studies, the ideal abduction angles during graft fixation vary depending on the type of material used. The method of graft tensioning involves abduction of the glenohumeral joint while performing the fixation process [36]. Mihata et al. [36] reported that an arm abduction angle ranging from 15° to 45° during reconstruction are important for successful reconstruction of the superior capsule. Different abduction angles using acellular dermal allografts have been reported; the best angle and graft tension for SCR has yet to be determined [10]. In a biomechanical study, Adams et al. [37] showed that when the SCR was tensioned at 15° of glenohumeral abduction, the deltoid muscle required similar amounts of force to abduct as in the intact state. Dyrna et al. [38] conducted a study involving 10 cadaveric shoulders and found that using a tensioned graft for SCR resulted in a statistically significant increase in maximum shoulder abduction compared to a non-tensioned graft. However, the maximum abduction achieved was still less than that of an intact shoulder. Specifically, using a tensioned SCR helped to restore a maximum abduction of 81% of the normal range of motion [38].

In practice, many surgeons follow Mihata et al.'s guidance to fix SCR grafts at shoulder abduction angles ranging from 10° to 45°. However, there is insufficient clinical evidence to determine the best abduction angle to use for different types of SCR grafts.

## SURGICAL TECHNIQUES

Since Mihata et al.'s technique [2] was first described, various techniques have been developed for SCR. An arthroscopic procedure was developed to confirm the rotator cuff tear pattern and severity, especially the extent of retraction and mobility of the rotator cuff tendon. After the rotator cuff tear is determined to be irreparable, acromioplasty is performed to create a smoother surface and prevent potential damage to the repaired tissue after the surgery. Mihata et al. [2] recommend including acromioplasty during SCR as acromioplasty can decrease the subacromial contact area. However, according to other studies, acromioplasty is not always necessary in SCR and was not conducted in all studies [39]. Surgeons may choose to perform acromioplasty if there is evidence of abrasion below the acromion. The subscapularis needs to be examined and, if necessary, repaired. Then, either a biceps tenodesis or tenotomy is performed. All soft tissues around the superior glenoid and footprint of the greater tuberosity are debrided. After performing decortication around the footprint of the greater tuberosity, graft sizing is conducted with the shoulder abducted. Two suturing devices are placed in the upper part of the glenoid. The initial anchor in the glenoid is inserted

behind the edge of the remaining interval tissue or subscapularis, while the second glenoid anchor is inserted in front of the edge of the remaining infraspinatus or teres minor tissue. Then, two suture anchors are positioned next to the joint margin. For preparation of the graft, the graft is folded in half, creating a 6-mm thickness with its fold oriented towards the back. Precision is ensured during hole creation in the graft using an 11-blade scalpel, leaving approximately 3 to 5 mm of the graft at its respective edge. The graft is inserted into the subacromial area under the guidance of suture threads passed through the lateral portal. The medial portion of the graft is tied with a knot; and during the fixation, the medial edge of the graft is firmly attached to the glenoid neck inferior to any residual rotator cuff tissue. The lateral portion of the graft is secured using a double-row or single-row suture bridge technique. To our knowledge, no clinical outcome studies have compared double-row to single-row SCR graft fixation for the lateral portion of graft. However, in one study in which single-row SCR graft fixation was used, a high magnetic resonance imaging graft failure rate and high reoperation rate were observed. This suggests that greater tuberosity fixation should be performed with an equivalent double-row transosseous fixation [22]. Margin convergence sutures are placed between the graft and the remaining infraspinatus or teres minor posteriorly and the interval tissue or subscapularis anteriorly. Anterior margin convergence can aid in graft tensioning, but the rotator interval tissues may sometimes be absent. Care should be taken not to over-constrain the shoulder anteriorly by attaching the graft to the subscapularis. This would be equivalent to closing the rotator interval. Posterior margin convergence is necessary to prevent subluxation of the humeral head and to allow restoration of the rotator cable. Furthermore, posterior or anterior margin convergence may increase the survival rate of graft by accelerating the vascularization, which results in graft structural strength reinforcement. Mihata et al. [2] suggested that using side-to-side suturing between the graft and the infraspinatus or subscapularis tendons is beneficial. However, a biomechanical study reported that SCR without additional side-to-side suturing did not significantly reduce the superior translation of the glenohumeral joint.

Nevertheless, the inclusion of side-to-side suturing resulted in the restoration of superior stability to a level comparable to that of the normal state [40].

## REHABILITATION

After undergoing SCR, the rehabilitation protocol is similar to that of repairing massive rotator cuff tear. The shoulder is maintained in a stable position for a duration of 6 weeks using a shoulder abduction brace set at an angle of 30° to 45° of abduction [41]. Pendulum exercises with passive elevation are allowed 6 weeks after surgery. If the expected range of motion is achieved at 3 months after surgery, then the next exercises need to focus on strengthening the rotator cuff and muscles around the shoulder. Complete participation in sports activities are permitted around 6 months after the surgical procedure [42].

## CONCLUSIONS

The treatment of irreparable rotator cuff tears remains challenging. SCR is a promising treatment option especially for certain indications. After its introduction by Mihata et al., various studies of its biomechanical properties and clinical outcomes have been conducted. Further research on long-term clinical outcomes and other contributing properties are needed to fully understand the factors that can affect SCR outcomes.

## NOTES


### ORCID

| | |
|---|---|
| Seok Won Chung | https://orcid.org/0000-0002-8221-9289 |
| Dong-Hyun Kim | https://orcid.org/0000-0001-9078-5953 |
| Hyun Joo Lee | https://orcid.org/0000-0003-2837-3434 |
| Won Ki Hong | https://orcid.org/0000-0003-1076-9369 |
| Seung Ho Chung | https://orcid.org/0000-0001-7432-724X |
| Jong Pil Yoon | https://orcid.org/0000-0001-6446-6254 |


### Author contributions

Conceptualization: SWC, JPY. Data curation: SWC, DHK, HJL, WKH, SHC. Resources: SWC. Supervision: SWC, JPY. Validation: SWC. Writing – original draft: SWC, DHK, WKH, SHC, JPY. Writing – review & editing: SWC, DHK, WKH, SHC, JPY.

### Conflict of interest

Jong Pil Yoon is an editorial board member of the journal but was not involved in the peer reviewer selection, evaluation, or decision process of this article. No other potential conflict of interest relevant to this article was reported.


### Funding

This study was supported by the National Research Foundation of Korea (NRF) grant funded by the Korean government (MSIT) (NRF-2022R1A2C1005374).


### Data availability

None.


https://doi.org/10.5397/cise.2023.00514

**Acknowledgments**
None.

## REFERENCES

1. Otto RJ, Clark RE, Frankle MA. Reverse shoulder arthroplasty in patients younger than 55 years: 2- to 12-year follow-up. J Shoulder Elbow Surg 2017;26:792–7.
2. Mihata T, Lee TQ, Watanabe C, et al. Clinical results of arthroscopic superior capsule reconstruction for irreparable rotator cuff tears. Arthroscopy 2013;29:459–70.
3. Smith TJ, Gowd AK, Kunkel J, Kaplin L, Waterman BR. Superior capsular reconstruction provides sufficient biomechanical outcomes for massive, irreparable rotator cuff tears: a systematic review. Arthroscopy 2021;37:402–10.
4. Thompson WO, Debski RE, Boardman ND 3rd, et al. A biomechanical analysis of rotator cuff deficiency in a cadaveric model. Am J Sports Med 1996;24:286–92.
5. Nimura A, Kato A, Yamaguchi K, et al. The superior capsule of the shoulder joint complements the insertion of the rotator cuff. J Shoulder Elbow Surg 2012;21:867–72.
6. Ishihara Y, Mihata T, Tamboli M, et al. Role of the superior shoulder capsule in passive stability of the glenohumeral joint. J Shoulder Elbow Surg 2014;23:642–8.
7. Mihata T, Lee TQ, Hasegawa A, et al. Arthroscopic superior capsule reconstruction can eliminate pseudoparalysis in patients with irreparable rotator cuff tears. Am J Sports Med 2018;46:2707–16.
8. Bernstein JM, Perez JR, Shah HA, et al. MRI of superior capsular reconstruction. Radiographics 2020;40:454–67.
9. Li H, Zhou B, Tang K. Advancement in arthroscopic superior capsular reconstruction for irreparable massive rotator cuff tear. Orthop Surg 2021;13:1951–9.
10. Tokish JM, Beicker C. Superior capsule reconstruction technique using an acellular dermal allograft. Arthrosc Tech 2015;4:e833–9.
11. Mihata T, Bui CN, Akeda M, et al. A biomechanical cadaveric study comparing superior capsule reconstruction using fascia lata allograft with human dermal allograft for irreparable rotator cuff tear. J Shoulder Elbow Surg 2017;26:2158–66.
12. Scheiderer B, Kia C, Obopilwe E, et al. Biomechanical effect of superior capsule reconstruction using a 3-mm and 6-mm thick acellular dermal allograft in a dynamic shoulder model. Arthroscopy 2020;36:355–64.
13. Cline KE, Tibone JE, Ihn H, et al. Superior capsule reconstruction using fascia lata allograft compared with double- and single-layer dermal allograft: a biomechanical study. Arthroscopy 2021;37:1117–25.
14. Shah SS, Kontaxis A, Jahandar A, et al. Superior capsule reconstruction using a single 6-mm-thick acellular dermal allograft for massive rotator cuff tears: a biomechanical cadaveric comparison to fascia lata allograft. J Shoulder Elbow Surg 2021;30:2166–76.
15. Mihata T, Lee TQ, Hasegawa A, et al. Five-year follow-up of arthroscopic superior capsule reconstruction for irreparable rotator cuff tears. J Bone Joint Surg Am 2019;101:1921–30.
16. de Campos Azevedo CI, Andrade R, Leiria Pires Gago Ângelo AC, Espregueira-Mendes J, Ferreira N, Sevivas N. Fascia lata autograft versus human dermal allograft in arthroscopic superior capsular reconstruction for irreparable rotator cuff tears: a systematic review of clinical outcomes. Arthroscopy 2020;36:579–91.
17. Makovicka JL, Chung AS, Patel KA, Deckey DG, Hassebrock JD, Tokish JM. Superior capsule reconstruction for irreparable rotator cuff tears: a systematic review of biomechanical and clinical outcomes by graft type. J Shoulder Elbow Surg 2020;29:392–401.
18. Polacek M, Nyegaard CP. Superior capsular reconstruction using 3-layered fascia lata autograft reinforced with a nonresorbable suture mesh. Arthrosc Sports Med Rehabil 2020;2:e489–97.
19. Ângelo AC, de Campos Azevedo CI. Minimally invasive fascia lata harvesting in ASCR does not produce significant donor site morbidity. Knee Surg Sports Traumatol Arthrosc 2019;27:245–50.
20. Mihata T, Lee TQ, Fukunishi K, et al. Return to sports and physical work after arthroscopic superior capsule reconstruction among patients with irreparable rotator cuff tears. Am J Sports Med 2018;46:1077–83.
21. Yoon JY, Kim PS, Jo CH. Clinical and radiological results after arthroscopic superior capsular reconstruction in patients with massive irreparable rotator cuff tears. Clin Shoulder Elb 2018;21:59–66.
22. Lee SJ, Min YK. Can inadequate acromiohumeral distance improvement and poor posterior remnant tissue be the predictive factors of re-tear?: preliminary outcomes of arthroscopic superior capsular reconstruction. Knee Surg Sports Traumatol Arthrosc 2018;26:2205–13.
23. Lim S, AlRamadhan H, Kwak JM, Hong H, Jeon IH. Graft tears after arthroscopic superior capsule reconstruction (ASCR): pattern of failure and its correlation with clinical outcome. Arch Orthop Trauma Surg 2019;139:231–9.
24. Gracitelli ME, Beraldo RA, Malavolta EA, Assunção JH, Oliveira DR, Ferreira Neto AA. Superior capsular reconstruction with

fascia lata allograft for irreparable supraspinatus tendon tears. Rev Bras Ortop (Sao Paulo) 2019;54:591–6.
25. Kholinne E, Kwak JM, Kim H, Koh KH, Jeon IH. Arthroscopic superior capsular reconstruction with mesh augmentation for the treatment of irreparable rotator cuff tears: a comparative study of surgical outcomes. Am J Sports Med 2020;48:3328–38.
26. Petri M, Greenspoon JA, Millett PJ. Arthroscopic superior capsule reconstruction for irreparable rotator cuff tears. Arthrosc Tech 2015;4:e751–5.
27. Sutter EG, Godin JA, Garrigues GE. All-arthroscopic superior shoulder capsule reconstruction with partial rotator cuff repair. Orthopedics 2017;40:e735–8.
28. Andersen WJ, Panero AA. Superior capsular reconstruction: clinical outcomes after minimum 2-year follow-up. Am J Orthop 2017;46:266–72.
29. Pogorzelski J, DelVecchio BM, Hussain ZB, Fritz EM, Godin JA, Millett PJ. Superior capsule reconstruction for massive rotator cuff tears: key considerations for rehabilitation. Int J Sports Phys Ther 2017;12:390–401.
30. Denard PJ, Brady PC, Adams CR, Tokish JM, Burkhart SS. Preliminary results of arthroscopic superior capsule reconstruction with dermal allograft. Arthroscopy 2018;34:93–9.
31. Tokish JM, Momaya A, Roberson T. Superior capsular reconstruction with a partial rotator cuff repair: a case report. JBJS Case Connect 2018;8:e1.
32. Altintas B, Higgins B, Anderson N, Millett PJ. Superior capsule reconstruction for the treatment of irreparable rotator cuff tears. Oper Tech Orthop 2018;28:226–31.
33. Laskovski JR, Boyd JA, Peterson EE, Abrams JS. Simplified technique for superior capsular reconstruction using an acellular dermal allograft. Arthrosc Tech 2018;7:e1089–95.
34. Pennington WT, Bartz BA, Pauli JM, Walker CE, Schmidt W. Arthroscopic superior capsular reconstruction with acellular dermal allograft for the treatment of massive irreparable rotator cuff tears: short-term clinical outcomes and the radiographic parameter of superior capsular distance. Arthroscopy 2018;34:1764–73.
35. Burkhart SS, Pranckun JJ, Hartzler RU. Superior capsular reconstruction for the operatively irreparable rotator cuff tear: clinical outcomes are maintained 2 years after surgery. Arthroscopy 2020;36:373–80.
36. Mihata T, McGarry MH, Kahn T, Goldberg I, Neo M, Lee TQ. Biomechanical effect of thickness and tension of fascia lata graft on glenohumeral stability for superior capsule reconstruction in irreparable supraspinatus tears. Arthroscopy 2016;32:418–26.
37. Adams CR, Comer B, Scheiderer B, et al. The Effect of glenohumeral fixation angle on deltoid function during superior capsule reconstruction: a biomechanical investigation. Arthroscopy 2020;36:400–8.
38. Dyrna F, Berthold DP, Muench LN, et al. Graft tensioning in superior capsular reconstruction improves glenohumeral joint kinematics in massive irreparable rotator cuff tears: a biomechanical study of the influence of superior capsular reconstruction on dynamic shoulder abduction. Orthop J Sports Med 2020;8:2325967120957424.
39. Badman BL, Baessler AM, Moor M. Short-term clinical outcomes and comparison of ultrasound versus magnetic resonance imaging of superior capsular reconstruction. Arthrosc Sports Med Rehabil 2020;2:e229–35.
40. Mihata T, McGarry MH, Kahn T, Goldberg I, Neo M, Lee TQ. Biomechanical role of capsular continuity in superior capsule reconstruction for irreparable tears of the supraspinatus tendon. Am J Sports Med 2016;44:1423–30.
41. Gimbel JA, Van Kleunen JP, Williams GR, Thomopoulos S, Soslowsky LJ. Long durations of immobilization in the rat result in enhanced mechanical properties of the healing supraspinatus tendon insertion site. J Biomech Eng 2007;129:400–4.
42. Trenerry K, Walton JR, Murrell GA. Prevention of shoulder stiffness after rotator cuff repair. Clin Orthop Relat Res 2005;(430):94–9.


https://doi.org/10.5397/cise.2023.00514

Current Concept

Clin Shoulder Elbow 2023;26(4):445-454
https://doi.org/10.5397/cise.2022.01396

CiSE
Clinics in Shoulder and Elbow

eISSN 2288-8721

# Arthroscopic Latarjet procedure: current concepts and surgical techniques

**Sang-Jin Shin, Jae Hyung Kim, Jonghyun Ahn**

*Department of Orthopedic Surgery, Ewha Womans University Seoul Hospital, Ewha Womans University College of Medicine, Seoul, Korea*

The Latarjet procedure is a surgical procedure that can effectively restore glenohumeral stability, especially in patients with anterior shoulder instability and glenoid bone loss. Many studies have shown comparable clinical outcomes between patients undergoing the arthroscopic Latarjet procedure and those undergoing traditional open methods or other glenohumeral joint stabilization procedures. However, the arthroscopic Latarjet procedure is a challenging technique due to the unfamiliar portal placements, proximity of neurovascular structures, and serious postoperative complications. The arthroscopic Latarjet procedure has not yet been widely applied, and a clear understanding of the anatomical structure and the precise methods is required prior to operation performance. Satisfactory clinical outcomes can be achieved by thorough preoperative planning and proper implant fixation methods.

**Keywords:** Shoulder joint; Arthroscopy; Surgical stabilization; Orthopedic surgical procedures

## INTRODUCTION

The coracoid process transfer, Latarjet, procedure was first described by Latarjet, a French physician, in 1954. The procedure is indicated for patients with recurrent shoulder instability with significant glenoid bone deficiency. The Latarjet procedure provides stability to the anterior part of the shoulder joint through three mechanisms called "triple blockings." First, the transferred coracoid process increases the surface area of the glenoid. Second, when the arm is in the abduction-external rotation position, the conjoined tendon attached to the coracoid process acts as a sling to suppress the forward translation of the humeral head. Third, the subscapularis muscle is separated and fixed by the transferred conjoined tendon, which acts as a supplement to the insufficient anterior joint capsule [1]. Traditionally, the Latarjet procedure was performed as a salvage procedure in cases of significant glenoid bone defect or recurrent instability after stabilization surgery [2]. However, the indications are expanding, especially in Europe. The Latarjet is now considered as a primary procedure in patients with recurrent shoulder dislocation, regardless of glenoid bone defect, or multidirectional instability after failed conservative treatment [3].

Use of an arthroscopic Latarjet procedure was first reported by Lafosse in 2007. In 2010, Lafosse reported satisfactory clinical outcomes, including quick return to daily activities, in 100 patients. Since then, the arthroscopic Latarjet approach has been widely applied in clinical practice due to its several advantages. This approach can assist with the observation of other pathologic lesions within the glenohumeral joint, proper localization of the coracoid graft, and prevention of technical errors such as graft

Received: November 30, 2022 Revised: January 23, 2023 Accepted: January 25, 2023
Correspondence to: Sang-Jin Shin
Department of Orthopedic Surgery, Ewha Womans University Seoul Hospital, Ewha Womans University College of Medicine, 260 Gonghang-daero, Gangseo-gu, Seoul 07804, Korea
Tel: +82-2-6956-1656, Fax: +82-2-2642-0349, Email: sjshin622@ewha.ac.kr, ORCID: https://orcid.org/0000-0003-0215-2860

Copyright© 2023 Korean Shoulder and Elbow Society.
This is an Open Access article distributed under the terms of the Creative Commons Attribution Non-Commercial License (http://creativecommons.org/licenses/by-nc/4.0/) which permits unrestricted non-commercial use, distribution, and reproduction in any medium, provided the original work is properly cited.

overhanging above the joint line. In addition, the approach can prevent postoperative joint stiffness from scar tissue; and patients can expect a faster return to activities of daily living [4-6].

## INDICATIONS

In general, marked bone defects of the glenoid and humeral head and their recurrence after Bankart repair or other joint stabilization surgery are accepted as indications for the arthroscopic Latarjet procedure. We consider the Latarjet procedure as a primary surgical choice in patients with glenoid bone loss of more than 20% or in seizure-controlled epilepsy patients. Patients with poor anterior capsulolabral tissue quality after primary repair or recurrence after Bankart revision repair are also indications. In addition, various factors such as the patient's condition and the surgeon's experience are considered before performing the Latarjet procedure. In a study of 189 patients, Yang et al. [7] compared a group that underwent arthroscopic Bankart and remplissage repair with a group that underwent the Latarjet procedure. Their findings were that those patients with less than 25% of glenoid bone loss had equivalent clinical outcomes between the two groups. Additionally, the Latarjet procedure resulted in less patient pain and low recurrence rates. In the same study, the Latarjet procedure was shown to have better clinical outcomes and lower recurrence rates in contact sports players.

## PREOPERATIVE PLANNING

A preoperative glenohumeral computed tomography scan is helpful to assess anatomical information related to the procedure. During arthroscopy, accurately measuring the required length of the screw is often difficult due to unclear vision and restriction of access. Therefore, the recommendation is to determine the length of the fixation screw to be used by measuring the anteroposterior length of the glenoid and the thickness of the coracoid process. The anatomical shape of the coracoid process should also be assessed. Since the anatomical direction and curvature of coracoid processes vary, a preoperative three-dimensional (3D) computed tomography scan can help determine the exact angle and direction when fashioning the screw hole and performing the osteotomy (Fig. 1). Hardy et al. [8] reported that preoperative computed tomography scans showed high reproducibility in identifying anatomical structures during arthroscopic Latarjet procedures. These researchers also compared the screw positions of groups with and without preoperative computed tomography and reported that the lower screw was located in a statistically unacceptable position in the group without preoperative planning, demonstrating the importance of preoperative planning [9].

### Selection of Graft Fixation Methods

The first arthroscopic Latarjet fixation method introduced by Lafosse et al. [6] required the use of two cannulated screws. However, fixation using metal screws can result in screw loosening and graft non-union. Coracoid graft fracture during screw insertion and impingement of the screw head with the humeral head due to an inappropriate screw angle can also be complications.

Because of these complications, surgeons have devised a procedure using cortical bone fixation buttons. Boileau et al. [10,11] introduced a method of passing two suture strands from the coracoid process to the posterior cortex of the glenoid through the bone tunnel and fixing the strands using the cortical buttons. In a study of 136 patients, Boileau et al. [10,11] reported that bone union was achieved in 95% of patients and that no secondary surgery was required to remove the implant. Xu et al. [12] introduced a procedure using a cortical bone fixation button and

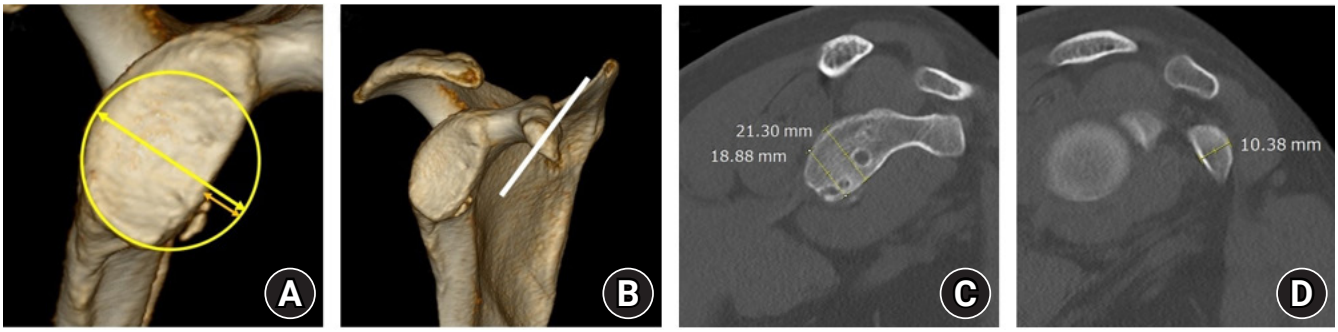


**Fig. 1.** Checklists with preoperative three-dimensional computed tomography right shoulder. (A) Glenoid bone defect is assessed on enface view using Sugaya method. (B) The approximate screw angle and location should be determined by analyzing the direction and inclination of the coracoid process. (C) The anteroposterior length of glenoid is checked. (D) The anteroposterior thickness of the coracoid process is assessed. Taken together with the anteroposterior glenoid size, this thickness estimates the approximate length of the screw.


https://doi.org/10.5397/cise.2022.01396

an anti-rotation suture anchor; they reported that 98% of 102 patients achieved bone union after an average follow-up of 40.3 months. Similarly, Castricini et al. [13] devised a procedure using four cortical bone fixation buttons.

Controversy surrounds the optimal fixation method for the graft. In a biomechanical study using a cadaver, Provencher et al. [14] reported that there were no significant differences in the maximum tensile strength and average failure strength between the metal screws and the cortical bone fixation buttons. However, Williams et al. [15] reported that the total load at failure and maximum cycle displacement for the cortical bone fixation button were significantly lower than that for a metal screw. Hardy et al. [16] analyzed 236 patients who had metal screw fixation and 72 patients who had cortical button fixation. These researchers found a significantly lower instability recurrence of 2.5% with screw fixation compared to 8.3% in patients fixed with cortical buttons, demonstrating the superiority of metal screws in fixation. However, no patient needed revision surgery with recurrence of instability after using the cortical fixation buttons. Rather, the re-operation rate was higher (5.9%) in patients with metal screws, which was due to complications such as metal screw irritation and protrusion [16]. Therefore, each fixation method has pros and cons and is selected carefully according to the surgeon's preference and the patient's condition.

## SURGICAL TECHNIQUES

We prefer the arthroscopic Latarjet procedure using two cannulated screws, the same method as that proposed by Lafosse et al. [6] The surgical procedure consists of joint space exploration, anterior glenoid preparation, exposure of the coracoid process, coracoid osteotomy, separation of the subscapularis and coracoid transfer, and fixation with cannulated screws.

### Patient Position and Portal Placement

The patient is placed in a modified beach chair position, and a surgical drape is applied to sufficiently expose the center of the sternum. The patient's upper body angle should be 30°–45°, which is lower than the general beach chair position. We use six arthroscopic portals. As with any other arthroscopy procedure, the arthroscopic Latarjet procedure requires an arthroscopic portal hole in the appropriate location and thorough use of the portal. These are crucial for successful surgery (Fig. 2). Some of these portals are unfamiliar; however, since the unfamiliar ones are anatomically safe, these are made with greater confidence as surgeons gain more experience. Since there are many procedures performed on the medial side of the conjoined tendon, anatomical knowledge is essential before performing surgery. Unlike other arthroscopic procedures, the portals in the arthroscopic Latarjet procedure do not use cannulas and move freely during the operation.

### Joint Space Exploration and Anterior Glenoid Preparation

The posterior portal, the arthroscopic examination viewing portal, for the introduction of the arthroscope is made parallel to the articular surface. After the arthroscopic examination, the anterior portal is made on the lateral side of the coracoacromial ligament. Instruments are inserted through the anterior portal; and the rotator interval, remnant anterior labral tissue, and joint capsule are debrided to create sufficient space and prevent interference between the glenoid and the transferred coracoid process. Marking the areas in the 2 and 5 o'clock positions from the expected location of the coracoid process graft attachment using an electric cautery device helps determine the location. Next, the lateral portal is made between the conjoined tendon and the subscapularis tendon in a direction parallel to the upper part of the subscapularis tendon. Ease in checking the location of the coracoid process is achieved by releasing the lateral and inferior surfaces of the coracoid process through the lateral portal using electric cautery.

When the arthroscopy is moved to the lateral portal, trimming the anterior glenoid bone surface by inserting the burr through the anterior portal is easy. This process not only provides decortication for bone union but is also an important task in matching the shape of the inferior part of the coracoid and the anterior glenoid surface to achieve perfect congruency (Fig. 3).

### Exposure of the Coracoids Process

With the lateral portal used as the viewing portal, the inferior

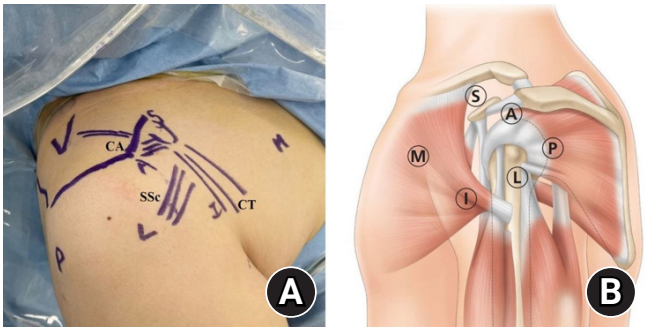


**Fig. 2.** Portals for the arthroscopic Latarjet procedure. (A) Surface anatomy and portals location of right shoulder. P: posterior portal, A: anterior portal, L: lateral portal, I: inferior portal, M: medial portal, S: superior portal, CA: coracoacromial ligament, CT: conjoined tendon, SSc: subscapularis tendon. (B) Schematics of portals for arthroscopic Latarjet procedure [17].

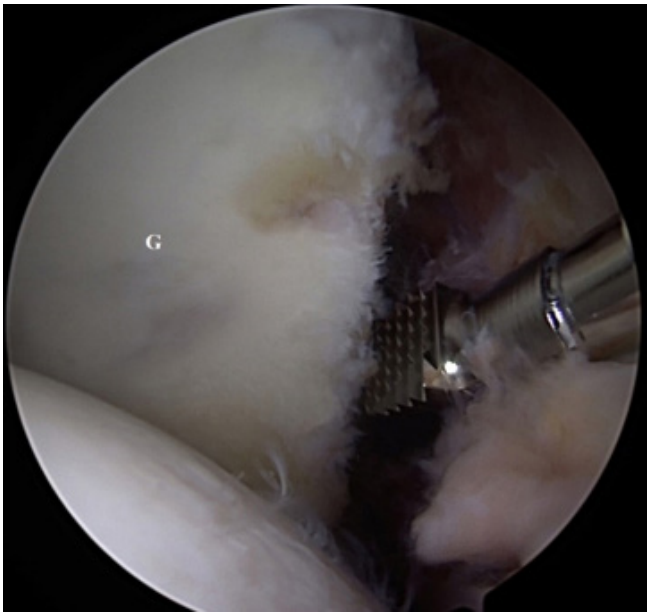


**Fig. 3.** Anterior glenoid preparation (viewing portal: lateral, working portal: anterior, right shoulder). An electrocautery device and burr are inserted through the anterior portal to trim the transplant site of anterior glenoid. G: glenoid.

portal is created in the long axis of the conjoined tendon, which is near the axillary pouch at the surface anatomical perspective. Using the inferior portal as the working portal, the soft tissue of the lateral and superior surface of the coracoid, including the coracoacromial ligament, is released. Inserting a Wissinger rod into the anterior portal assists in the exposure of the superior surface of the coracoid and in securing sufficient space by sustaining the deltoid and thoracic muscles.

After moving the arthroscopy to the inferior portal, the soft tissues on the superior and inferior surfaces of the coracoid are released as much as possible using the lateral portal as a working portal. Especially because the inferior surface of the coracoid will be attached to the anterior glenoid at a later stage of the operation, decortication can be performed in advance. Afterwards, the medial portal is made using a spinal needle in a position that can be entered in parallel to the glenoid articular surface. Using the medial portal as the working portal, the medial side of the coracoid is exposed. Since the musculocutaneous nerve is located medially to the coracoid, the pectoralis minor muscle is detached with caution so as not to damage the nerve. All soft tissue on the slope of the coracoid is removed, and the superior surface is exposed to the border of the coracoclavicular ligament base. The medial and lateral sides of the conjoined tendon are also released to facilitate the transfer of the coracoid.

### Coracoid Osteotomy

After the exposure to the coracoid is completed, a superior portal is formed for the osteotomy. Since the superior portal is used not only for osteotome insertion but also for making a screw hole in the coracoid, the location and size of the portal should be considered carefully. With the inferior portal as the viewing portal, a guide is inserted through the superior portal to select the location to be drilled on the upper surface of the coracoid. Since the length and shape of coracoid processes differ between individuals, the use of preoperative 3D computed tomography is beneficial to determine the direction of the coracoid that can be most congruently attached to the joint when inserting a guide. In addition, not positioning the guide too far is important to avoid distal cortical bone fractures. This is accomplished by identifying the interface between the tendon and the bone. The guide is positioned 7 mm inward from the lateral surface of the coracoid, two proximal and distal guide wires are inserted along the guide, and drilling is performed along the guide wire. After drilling, a top hat is inserted in each hole to prevent the metal screw head from being inserted into the coracoid cortical bone and causing a fracture when pressure is applied during close contact with the anterior glenoid bone. The coracoid holding wire is then inserted; this plays an important role in helping to connect the coracoid positioning double cannula after the coracoid osteotomy. The coracoid holding wire passes through the proximal top hat and the inferior surface of the coracoid, returns to the distal top hat, and is withdrawn via the proximal and distal ends through the medial portal (Fig. 4).

Next, an osteotome is inserted through the superior portal to perform coracoid process osteotomy. If the burr is inserted through the lateral portal, decorticating the area in which the osteotomy is to be made can prevent fracture in an unexpected direction. When the osteotomy is performed completely, the arthroscope can be moved to the lateral portal, and two 3.5-mm coracoid screws are connected to the coracoid thorough a double cannula along the coracoid holding wire to manipulate the coracoid process (Fig. 5). The sharp boundaries of the osteotomized site and the inferior surface of the coracoid are trimmed to fit the shape of the glenoid and decorticated to facilitate bone union.

### Subscapularis Muscle Separation and Coracoids Transfer

The lateral portal is used as the viewing portal and the inferior portal as the working portal. The separation location is generally acceptable for the boundary between the upper 2/3 and the lower 1/3 of the subscapularis tendon. However, separating the middle part of the subscapularis muscle does not affect the clinical outcome. Limiting separation to the muscle as much as possible is


https://doi.org/10.5397/cise.2022.01396

**Fig. 4.** Exposure of the coracoid process (viewing portal: inferior, working portal: lateral and medial, right shoulder). The coracoacromial ligament and pectoralis minor tendon were released from the lateral and medial side of the coracoid process, respectively. Then two top hats were inserted in the coracoid holes after making holes in appropriate positions using the guide. T: top hat, C: coracoid process, CT: conjoined tendon.

recommended. However, if the size of the graft is large or if the patient has bulky muscles, separating some tendinous parts of the muscle may be necessary. Since the axillary nerves are located medially, identifying the nerves to prevent damage is helpful. Separating the subscapularis muscle and securing a space through which the coracoid process will be transferred is important. We insert a silastic drain into the anterior portal to draw the superior part of the subscapularis and insert a Wissinger rod into the posterior portal to drag the inferior part downward (Fig. 6).

The coracoid graft connected to the double cannula is transferred through the separated subscapularis muscle to the anterior glenoid transplant site, which was marked previously. The Wissinger rod is inserted into the posterior portal and positioned parallel to the glenoid surfaces to determine the medial and lateral positions of the coracoid graft. Care must be taken not to under-hang or overhang the graft with joint surfaces.

### Fixation with Metal Screws

Once the location of the coracoid graft has been determined, each guide pin is inserted through the coracoid screw located in the double cannula for fixation. The guide pin passes through the transferred coracoid graft, the anterior and posterior cortical bones of the glenoid, and the posterior skin of the scapula and is

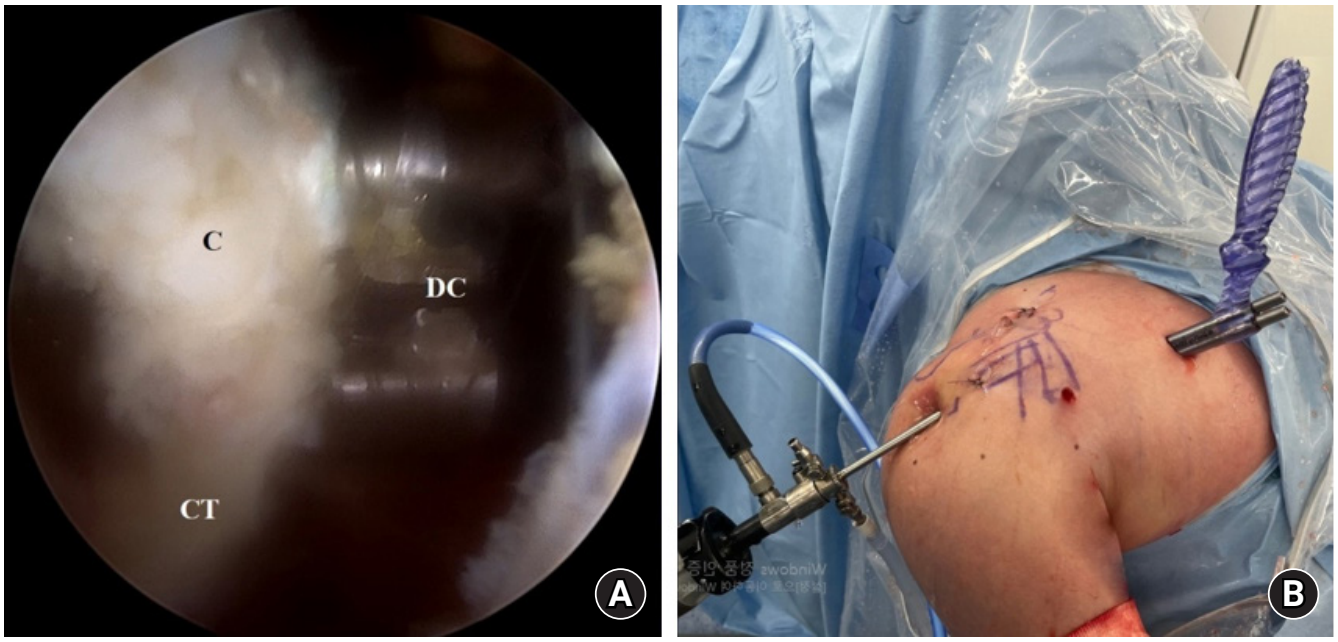


**Fig. 5.** The double cannula connected to the osteotomized coracoid process (viewing portal: inferior, working portal: medial, right shoulder). (A) The osteotomized coracoid process is connected by the double cannula for fixation to the anterior glenoid. (B) Extra-corporeal view of the double cannula. The coracoid process can be easily controlled using a double cannula inserted through the medial portal. C: coracoid process, DC: double cannula, CT: conjoined tendon.

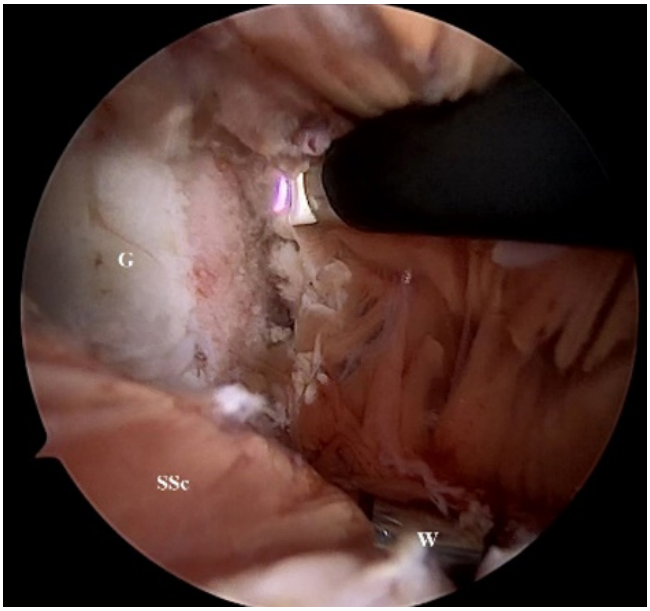


**Fig. 6.** Subscapularis muscle separation and anterior glenoid exposure (viewing portal: lateral, working portal: inferior, right shoulder). The subscapularis muscle was split using an electrocautery device, and a space was secured for the coracoid graft with a silastic drain and a Wissinger rod. G: glenoid, SSc: subscapularis muscle, W: Wissinger rod.

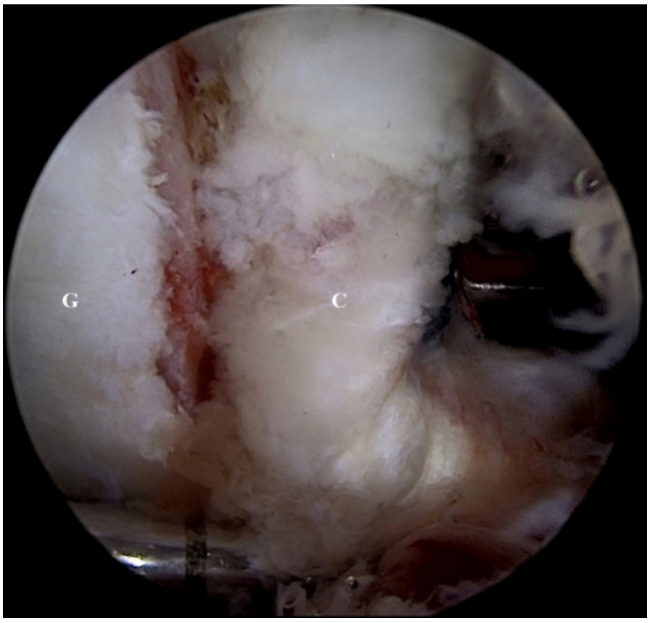


**Fig. 7.** Fixation of the coracoid process raft to anterior glenoid (viewing portal: lateral, working portal: medical, right shoulder). After inserting two guide pins, drill and insert the 3.5-mm cannulated screws. For proper compression, apply pressure alternately to the two upper and lower metal screws. The coracoid bone is fixed parallel to the glenoid surface. G: glenoid, C: coracoid process.

clamped outside the skin. This is to prevent the guide pin from pulling back during the removal of the cannulated drill. Once the guide pin is fixed, the coracoid screw is removed, and drilling is performed using a 3.2-mm cannulated drill bit through a double cannula. The length of the metal screw can be estimated by the depth of the drilling up to the posterior cortical bone. The 3.5-mm cannulated screw is inserted after drilling. After the two metal screws are partially inserted, insertion is completed by alternating compression of the two metal screws so that the coracoid graft can be properly compressed. Both the metal screw insertion and the glenoid and coracoid bone fixation status must be checked through the lateral portal (Fig. 7). This fixation assessment is to ensure that the fixation is parallel to the glenoid surface. After surgery, plain radiographs and computed tomography scans are used to confirm the location of the coracoid graft and the direction of the metal screw (Fig. 8).

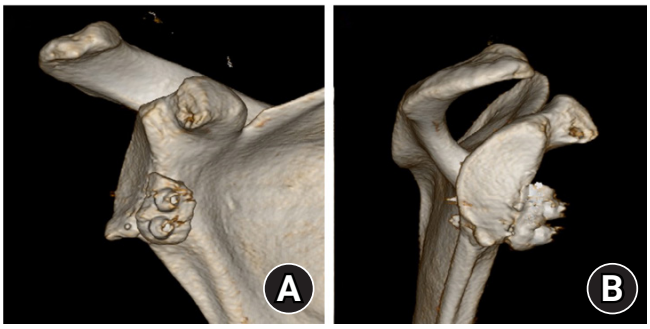


**Fig. 8.** Postoperative three-dimensional computed tomographyafter arthroscopic Latarjet procedure of right shoulder. (A) The transferred coracoid process forms proper congruency with the existing glenoid articular surface. (B) The coracoid process was well-fixed at the appropriate height in the enface view.

## DISCUSSION

### Latarjet Procedure versus Bankart Repair

Recent studies comparing mid- to long-term clinical outcomes and complication rates of Bankart repair to the Latarjet procedure showed that the Latarjet procedure was equivalent or superior to Bankart repair. According to a meta-analysis by Imam et al. [18], which included 3,275 shoulder joints, the infection rate of patients who underwent the Latarjet procedure was higher than that of those undergoing Bankart repair. However, the risk of recurrence or reoperation rate was higher in the Bankart repair group as the follow-up period lengthened.16 In a long-term follow-up study of adolescent patients with recurrent anterior shoulder dislocation, Waltenspül et al. [19] found that the treatment failure and re- operation rates were significantly higher in the patients who underwent Bankart repair; however, there was no difference in the Constant scores and subjective shoulder values between the two groups. Ernstbrunner et al. [20] comparing patients with a mean age of 47 years reported that there were no


https://doi.org/10.5397/cise.2022.01396

differences in subject shoulder values, glenohumeral arthritis grades at the final follow-up, and revision rates; but the rates of re-dislocation or subluxation were higher in the Bankart repair group. Rossi et al.'s study [21] of rugby players with less than 20% glenoid bone defects also found that the Latarjet procedure had lower recurrence and reoperation rates than Bankart repair despite no differences in the range of motion, Rowe scores, Athletic Shoulder Outcome Scoring System scores, and time of return to sports. Rodkey et al. [22] reported that the recurrence of instability was lower in the primary Latarjet group than with the Latarjet revision patients who failed after Bankart repair, emphasizing the importance of the Latarjet procedure as a primary surgery.

### Comparison of Open versus Arthroscopic Latarjet Procedure

The biggest difference between open and arthroscopic Latarjet procedures is that in open surgery, the anterior joint capsule is reconstructed using the coracoacromial ligament. This is not true of the arthroscopic procedure. To compensate for this, one study reported good results by performing anterior capsular reconstruction using anchors in arthroscopic surgery [23]. In the results of biomechanical studies using cadavers to compare these differences, Schulze-Borges et al. [24] showed that the translation was significantly decreased in the abduction position in open surgery compared to the arthroscopic procedure. However, there was no difference between the two groups in the abduction-external rotation position. Kleiner et al. [25] reported that there was no difference in the translation of the shoulder joint regardless of reconstruction of the anterior capsule and that the range of external rotation movement decreased in the group that underwent anterior capsular reconstruction.

### Clinical Outcomes of Arthroscopic Latarjet Procedure

Recently, many clinical trials have been reported to show satisfactory outcomes. Zhu et al. [23] reported that graft union was achieved in all 52 patients after an arthroscopic Latarjet procedure with anterior shoulder instability. Dumont et al. [26] also reported satisfactory clinical outcomes in a study with at least 5 years of follow-up. In addition, several prospective studies have reported equivalent clinical outcomes between arthroscopic and open Latarjet surgery, drawing more attention to its effectiveness [27-30]. Other studies comparing the clinical outcomes of arthroscopic and open Latarjet surgery have been reported recently (Table 1) [27-34]. Hurley et al. [31] compared clinical outcomes of 102 patients with an average of 51.3 months of follow-up and reported that there was no significant difference between open and arthroscopic surgery. Ali et al. [32] observed 48 patients with open and arthroscopic Latarjet surgery for an average of 30.5 months and compared the range of motion, strength, visual analog scale (VAS) scores, Rowe scores, and Western Ontario Shoulder Instability (WOSI) scores. Postoperative computed tomography was used to evaluate the Gerber index, Sugaya index, and superoinferior position of the graft bone, as well as screw angle with glenoid surface in axial images (a-angle). Graft resorption and glenohumeral arthritis grade at final follow-up were also evaluated. These researchers reported that internal rotation was significantly reduced, the WOSI score was higher at final follow-up, and the screw tended to be angulated more medially in the arthroscopic Latarjet group. In a prospective study that analyzed 184 patients, Nourissat et al. [29] compared postoperative pain and WOSI scores and reported less pain on postoperative days 3 and 7 and better WOSI scores at 3 months postoperatively in the arthroscopic group. Marion et al. [27] evaluated VAS scores in the first week after surgery, the position of the graft using computed tomography in the third month after surgery, and WOSI scores in 58 patients. This group observed that patients had less pain in the first week after the surgery and a better equatorial position in arthroscopic surgery; there were no significant difference in the WOSI scores between the two groups. Zhu et al. [30] examined 44 patients with open surgery and 46 patients with arthroscopic surgery for at least 2 years of follow-up and evaluated the shoulder function and 1-year postoperative graft resorption. In that study, the coracoid graft was in a more proper superoinferior position in open surgery, but there were no significant differences in other measures. Graft resorption occurred to a lesser extent in arthroscopic surgery, which may be accounted for by the maintenance of soft tissue and blood supply around the coracoid process.

### Complications of Arthroscopic Latarjet Procedure

A systematic review of 89 clinical papers, including 7,175 patients, demonstrated that the short-term complication rate of the arthroscopic Latarjet procedure was 6.8%, which was not significantly different from the 6.1% complication rate of open surgery [35]. As for the types of complications, 3.2% of graft-related complications were coracoid fractures or non-unions, 1.9% were implant-related problems, 0.7% were neurological complications, 0.5% were infections, and 0.5% were other complications. However, while the graft-related complication was mainly non-union after the open surgery, arthroscopic surgery was performed mainly due to the fracture of the coracoid graft. This may be due to the technical difficulties of arthroscopic surgery. In a study on the learning curve of the arthroscopic method reported by Kordasiewicz et al. [34], complications such as graft fracture appeared at the beginning of the learning curve. In a systematic re-

**Table 1.** Studies comparing open vs. arthroscopic Latarjet procedures

| Study | Study design | Sample size | | Mean age (yr) | Follow-up (mo) | Clinical outcome (Arthro:Open) | Complication (%) (Arthro:Open) | Recurrence (%) | |
|---|---|---|---|---|---|---|---|---|---|
| | | Arthro | Open | | | | | Arthro | Open |
| Cunningham et al. (2016) [33] | Retrospective | 28 | 36 | 26 ± 7.6 | 6.6 ± 5.9 | Walch-Duplay score (88:91) | Intraop (0:0)<br>Postop (29:11) | 3.6 | 0 |
| Metais et al. (2016) [28] | Prospective | 286 | 104 | 22.7 ± 4.1 | 22.7 ± 4.1 | Walch Duplay score (92.8:85.9)<br>Rowe score (93.4:83.9) | Intraop (1.4:3.9)<br>Postop (12.5:8.4) | 4.1 | 1.0 |
| Nourissat et al. (2016) [29] | Prospective | 99 | 85 | Not specified | Not specified | VAS score (1.2:1.6)<br>Symptom WOSI score (13%:18%)<br>Sports/recreation/work WOSI score (15%:24%) | NA | NA | |
| Marion et al. (2017) [27] | Prospective | 36 | 22 | 26.9 ± 7.7 | 29.8 ± 4.4 | VAS score (1.2:2.5)<br>WOSI score (372.1:451) | Intraop (0:0)<br>Postop (5.6:0) | 2.8 | 0 |
| Zhu et al. (2017) [30] | Prospective | 44 | 46 | 30.1 | 28.8 | ASES score (93.3:93.0)<br>Constant score (96.5:95.0)<br>Rowe score (97.1:95.4) | No complications | No complications | |
| Kordasiewicz et al. (2019) [34] | Retrospective | 62 | 48 | 26.9 | 36.8 | Walch-Duplay score (92.8:85.9)<br>Rowe score (78.9:87.8)<br>VAS score (1.38:0.77)<br>Patient's satisfaction (91.9%:96.8%)<br>Residual apprehension (31%:28.7%) | NA | NA | |
| Ali et al. (2020) [32] | Retrospective | 33 | 15 | 29.5 | 30.5 | WOSI score (448:670)<br>VAS score (1:2.5)<br>Rowe score (80:78) | Postop (15:20) | 3.0 | 13.3 |
| Hurley et al. (2021) [31] | Retrospective | 30 | 72 | 30.6 | 51.6 | WOSI score (27.1%:24.9%)<br>VAS score (1.3:1)<br>VAS during sports (2.2:1.5)<br>SSV score (75.7:74.1)<br>SIRSI score (66.7:67)<br>Patient's satisfaction (85.6:88.3) | Overall (6.7:11.1) | 6.7 | 6.9 |

Arthro: arthroscopic Latarjet procedure, Intraop: intraoperative, Postop: postoperative, VAS: visual analog scale, NA: not available, WOSI: Western Ontario Shoulder Instability, ASES: American Shoulder and Elbow Surgeons, SSV: subjective shoulder value, SIRSI: shoulder instability-return to sport after injury.



https://doi.org/10.5397/cise.2022.01396

view of 35 clinical papers, Cho et al. [36] analyzed the complications of the Latarjet procedure by categorizing them as intraoperative, postoperative, and instability-related. Intraoperative complications such as graft fractures were higher for the arthroscopic procedure, while instability-related complications were higher for open surgery.

## CONCLUSIONS

The arthroscopic Latarjet procedure is a surgical method with several advantages and can result in equivalent levels of patient shoulder function and complication rates compared with open surgery. However, since the Latarjet arthroscopic techniques compared to general arthroscopic techniques are relatively difficult and the learning curves are slow, surgery should be performed by surgeons with advanced anatomical knowledge and abundant experience.

## NOTES

### ORCID

| | |
|---|---|
| Sang-Jin Shin | https://orcid.org/0000-0003-0215-2860 |
| Jae Hyung Kim | https://orcid.org/0000-0003-3455-8689 |
| Jonghyun Ahn | https://orcid.org/0000-0002-0624-0502 |

### Author contributions

Conceptualization: SJS. Data curation: JHK. Formal analysis: JHK, JA. Investigation: SJS, JHK, JA. Project administration: JHK, JA. Supervision: SJS. Validation: SJS, JA. Writing–original draft: JHK. Writing–review & editing: SJS, JHK.

### Conflict of interest

None.

### Funding

None.

### Data availability

None.

### Acknowledgments

None.

## REFERENCES

1. Provencher MT, Bhatia S, Ghodadra NS, et al. Recurrent shoulder instability: current concepts for evaluation and management of glenoid bone loss. J Bone Joint Surg Am 2010;92 Suppl 2:133–51.
2. Bishop JY, Hidden KA, Jones GL, Hettrich CM, Wolf BR; MOON Shoulder Group. Factors influencing surgeon's choice of procedure for anterior shoulder instability: a multicenter prospective cohort study. Arthroscopy 2019;35:2014–25.
3. Wong SE, Friedman LG, Garrigues GE. Arthroscopic Latarjet: indications, techniques, and results. Arthroscopy 2020;36:2044–6.
4. Arrigoni P, Huberty D, Brady PC, Weber IC, Burkhart SS. The value of arthroscopy before an open modified Latarjet reconstruction. Arthroscopy 2008;24:514–9.
5. Boileau P, Richou J, Lisai A, Chuinard C, Bicknell RT. The role of arthroscopy in revision of failed open anterior stabilization of the shoulder. Arthroscopy 2009;25:1075–84.
6. Lafosse L, Lejeune E, Bouchard A, Kakuda C, Gobezie R, Kochhar T. The arthroscopic Latarjet procedure for the treatment of anterior shoulder instability. Arthroscopy 2007;23:1242.
7. Yang JS, Mehran N, Mazzocca AD, Pearl ML, Chen VW, Arciero RA. Remplissage versus modified Latarjet for off-track Hill-Sachs lesions with subcritical glenoid bone loss. Am J Sports Med 2018;46:1885–91.
8. Hardy A, Loriaut P, Granger B, et al. Reliability of a CT reconstruction for preoperative surgical planning in the arthroscopic Latarjet procedure. Knee Surg Sports Traumatol Arthrosc 2018;26:40–7.
9. Hardy A, Gerometta A, Granger B, et al. Preoperative CT planning of screw length in arthroscopic Latarjet. Knee Surg Sports Traumatol Arthrosc 2018;26:24–30.
10. Boileau P, Gendre P, Baba M, et al. A guided surgical approach and novel fixation method for arthroscopic Latarjet. J Shoulder Elbow Surg 2016;25:78–89.
11. Boileau P, Saliken D, Gendre P, et al. Arthroscopic Latarjet: suture-button fixation is a safe and reliable alternative to screw fixation. Arthroscopy 2019;35:1050–61.
12. Xu J, Liu H, Lu W, et al. Modified arthroscopic Latarjet procedure: suture-button fixation achieves excellent remodeling at 3-year follow-up. Am J Sports Med 2020;48:39–47.
13. Castricini R, Taverna E, Guarrella V, De Benedetto M, Galasso O. Arthroscopic Latarjet procedure: a technique using double round ENDOBUTTONs and specific glenoid and coracoid guides. Arthrosc Tech 2020;9:e995–1001.
14. Provencher MT, Aman ZS, LaPrade CM, et al. Biomechanical comparison of screw fixation versus a cortical button and self-tensioning suture for the Latarjet procedure. Orthop J Sports Med 2018;6:2325967118777842.
15. Williams RC, Morris RP, El Beaino M, Maassen NH. Cortical

suture button fixation vs. bicortical screw fixation in the Latarjet procedure: a biomechanical comparison. J Shoulder Elbow Surg 2020;29:1470–8.
16. Hardy A, Sabatier V, Schoch B, Vigan M, Werthel JD; Study Investigators. Latarjet with cortical button fixation is associated with an increase of the risk of recurrent dislocation compared to screw fixation. Knee Surg Sports Traumatol Arthrosc 2020;28:2354–60.
17. Shin SJ, Park I, Lee SH, Kim IW, Kim MS. The art of shoulder arthroscopy. Panmun educations; 2022.
18. Imam MA, Shehata MS, Martin A, et al. Bankart repair versus Latarjet procedure for recurrent anterior shoulder instability: a systematic review and meta-analysis of 3275 shoulders. Am J Sports Med 2021;49:1945–53.
19. Waltenspül M, Ernstbrunner L, Ackermann J, Thiel K, Galvin JW, Wieser K. Long-term results and failure analysis of the open Latarjet procedure and arthroscopic Bankart repair in adolescents. J Bone Joint Surg Am 2022;104:1046–54.
20. Ernstbrunner L, De Nard B, Olthof M, et al. Long-term results of the arthroscopic Bankart repair for recurrent anterior shoulder instability in patients older than 40 years: a comparison with the open Latarjet procedure. Am J Sports Med 2020;48:2090–6.
21. Rossi LA, Tanoira I, Gorodischer T, Pasqualini I, Ranalletta M. Recurrence and revision rates with arthroscopic Bankart repair compared with the Latarjet procedure in competitive rugby players with glenohumeral instability and a glenoid bone loss < 20. Am J Sports Med 2021;49:866–72.
22. Rodkey DL, Colantonio DF, LeClere LE, Kilcoyne KG, Dickens JF. Latarjet after failed arthroscopic Bankart repair results in twice the rate of recurrent instability compared with primary Latarjet. Arthroscopy 2021;37:3248–52.
23. Zhu YM, Jiang C, Song G, Lu Y, Li F. Arthroscopic Latarjet procedure with anterior capsular reconstruction: clinical outcome and radiologic evaluation with a minimum 2-year follow-up. Arthroscopy 2017;33:2128–35.
24. Schulze-Borges J, Agneskirchner JD, Bobrowitsch E, et al. Biomechanical comparison of open and arthroscopic Latarjet procedures. Arthroscopy 2013;29:630–7.
25. Kleiner MT, Payne WB, McGarry MH, Tibone JE, Lee TQ. Biomechanical comparison of the Latarjet procedure with and without capsular repair. Clin Orthop Surg 2016;8:84–91.
26. Dumont GD, Fogerty S, Rosso C, Lafosse L. The arthroscopic Latarjet procedure for anterior shoulder instability: 5-year minimum follow-up. Am J Sports Med 2014;42:2560–6.
27. Marion B, Klouche S, Deranlot J, Bauer T, Nourissat G, Hardy P. A prospective comparative study of arthroscopic versus mini-open Latarjet procedure with a minimum 2-year follow-up. Arthroscopy 2017;33:269–77.
28. Metais P, Clavert P, Barth J, et al. Preliminary clinical outcomes of Latarjet-Patte coracoid transfer by arthroscopy vs. open surgery: prospective multicentre study of 390 cases. Orthop Traumatol Surg Res 2016;102(8S):S271–6.
29. Nourissat G, Neyton L, Metais P, et al. Functional outcomes after open versus arthroscopic Latarjet procedure: a prospective comparative study. Orthop Traumatol Surg Res 2016;102(8S):S277–9.
30. Zhu Y, Jiang C, Song G. Arthroscopic versus open Latarjet in the treatment of recurrent anterior shoulder dislocation with marked glenoid bone loss: a prospective comparative study. Am J Sports Med 2017;45:1645–53.
31. Hurley ET, Ben Ari E, Lorentz NA, et al. Both open and arthroscopic Latarjet result in excellent outcomes and low recurrence rates for anterior shoulder instability. Arthrosc Sports Med Rehabil 2021;3:e1955–60.
32. Ali J, Altintas B, Pulatkan A, Boykin RE, Aksoy DO, Bilsel K. Open versus arthroscopic Latarjet procedure for the treatment of chronic anterior glenohumeral instability with glenoid bone loss. Arthroscopy 2020;36:940–9.
33. Cunningham G, Benchouk S, Kherad O, Lädermann A. Comparison of arthroscopic and open Latarjet with a learning curve analysis. Knee Surg Sports Traumatol Arthrosc 2016;24:540–5.
34. Kordasiewicz B, Kiciński M, Małachowski K, Boszczyk A, Chaberek S, Pomianowski S. Arthroscopic Latarjet stabilization: analysis of the learning curve in the first 90 primary cases: early clinical results and computed tomography evaluation. Arthroscopy 2019;35:3221–37.
35. Hurley ET, Schwartz LB, Mojica ES, et al. Short-term complications of the Latarjet procedure: a systematic review. J Shoulder Elbow Surg 2021;30:1693–9.
36. Cho CH, Na SS, Choi BC, Kim DH. Complications related to Latarjet shoulder stabilization: a systematic review. Am J Sports Med 2023;51:263–70.


https://doi.org/10.5397/cise.2022.01396

Current Concept

Clin Shoulder Elbow 2023;26(4):455-461
https://doi.org/10.5397/cise.2022.01291

CiSE
Clinics in Shoulder and Elbow

eISSN 2288-8721

# Improving visualization in shoulder arthroscopy

**Emily R. McDermott[1], David J. Tennent[2], Daniel J. Song[2]**

[1]*Department of Orthopedic Surgery, San Antonio Military Medical Center, San Antonio, TX, USA*
[2]*Department of Orthopedic Surgery, Evans Army Community Hospital, Fort Carson, CO, USA*

Arthroscopic shoulder procedures are one of the most common procedures used to restore function through minimally invasive techniques. With the demand for shoulder arthroscopic procedures comes the need for safe, effective, and efficient surgery that maximizes patient outcomes while minimizing complications. Many variables contribute to visualization in shoulder arthroscopy including vascular anatomy, blood pressure control, arthroscopic pump systems, turbulence control, epinephrine, and tranexamic acid. Furthermore, patient positioning can have a dramatic effect on visualization with both the beach chair position and lateral decubitus positioning having various strengths and weaknesses depending on the intended procedure being performed. The purpose of this review is to examine the benefits and complications reported in the literature for improving visualization in shoulder arthroscopy.

**Keywords:** Shoulder; Arthroscopy; Visualization; Surgery; Review

## INTRODUCTION

Arthroscopic shoulder procedures are one of the most common procedures used to restore function through minimally invasive techniques. The 2006 National Survey of Ambulatory Surgery estimated that 529,689 rotator cuff repairs and shoulder arthroscopic procedures were performed that year [1,2]. A more recent study examined this number by geographic location and determined the rates of shoulder arthroscopy and arthroscopic rotator cuff repair to be 64.96– 623.6 per 100,000 persons [2]. With the demand for shoulder arthroscopic procedures comes the need for safe, effective, and efficient surgery that maximizes patient outcomes while minimizing complications.

Visualization in shoulder arthroscopy is crucial to efficiency, effectiveness, and safe surgery. Poor visualization can lead to surgeon frustration and unintended complications. Increased operative time can lead to a larger amount of fluid extravasation, neck swelling, chest-wall swelling, and respiratory distress [3]. Many variables contribute to visualization quality during shoulder arthroscopy including vascular anatomy, patient positioning, blood-pressure control, arthroscopic pump systems, turbulence control, epinephrine (EPI), and tranexamic acid (TXA). In particular, patient positioning, including the beach chair position (BCP) and lateral decubitus position (LDP), can have a dramatic effect on visualization, and the positions have various strengths and weaknesses depending on the procedure being performed [4].

Visualization is hard to define but encompasses the clarity necessary during surgery to perform the procedure in a safe, effective manner. Historically, most studies utilized a subjective visualization scoring, but recent efforts have aimed to establish an objective measurement tool to assess visual clarity during shoulder arthroscopy. The visual analog scale, graded 0–10, and the Shoulder Arthroscopy Grading Scale, graded 1–4, have been proposed as objective tools, with one study noting strong-to-ex-

Received: October 14, 2022 Revised: December 16, 2022 Accepted: December 27, 2022
Correspondence to: Emily R. McDermott
Department of Orthopedic Surgery, San Antonio Military Medical Center, 3551 Roger Brooke Drive, San Antonio, TX 78234, USA
Tel: +1-508-505-7293, E-mail: emily.r.mcdermott@gmail.com, ORCID: https://orcid.org/0000-0001-8418-7893

Copyright© 2023 Korean Shoulder and Elbow Society.
This is an Open Access article distributed under the terms of the Creative Commons Attribution Non-Commercial License (http://creativecommons.org/licenses/by-nc/4.0/) which permits unrestricted non-commercial use, distribution, and reproduction in any medium, provided the original work is properly cited.

cellent interobserver reliability [5]. The purpose of this review is to examine the benefits and complications reported in the literature for improving visualization in shoulder arthroscopy.

## ANATOMY

Knowledge of normal and abnormal shoulder anatomy is critical when performing arthroscopic shoulder surgery. Understanding the reported vascular anatomy in the shoulder allows the surgeon to avoid potential bleeding and improve visualization during shoulder arthroscopy [6]. Anatomical understanding is also paramount in portal placement to avoid iatrogenic injury. The posterior viewing portal is often established on the posterolateral corner of the acromion in the raphe of the infraspinatus and may vary according to patient size, positioning, and intended procedure [7,8]. Structures at risk in posterior portal placement include the infraspinatus and teres minor muscles, suprascapular artery, and axillary and suprascapular nerves [9]. A standard anterior rotator interval portal is commonly used and is typically established using needle localization just lateral to the coracoid process and is created under direct visualization [8]. Cadaveric dissection of standard shoulder arthroscopic portals revealed that the most at risk structure in anterior portal placement is the cephalic vein; while still at risk, the axillary artery and nerve are further away [9].

Yepes et al. [6] performed a cadaveric study to identify the arteries in the subacromial space as well as their corresponding landmarks. They examined the vascular patterns through the use of gross inspection, angiograms, and photographs. The authors found a constant vascularity pattern in 60% of the shoulders. They found that heavy bleeding can be expected if the coracoacromial ligament is transected and the inferior deltoid fascia is exposed, injuring the acromial branch of the thoracoacromial artery. During arthroscopic distal clavicle resection, Yepes et al. [6] suggest avoiding capsular damage to prevent bleeding from the anterior and posterior vessels of the acromioclavicular joint. Light bleeding may be expected from the coracoacromial arterioles during acromioplasty and rarely presents a major issue. They also found that the suprascapular artery runs over the neck of the glenoid and is at risk of injury when instrumentation advanced beyond 20 mm from the glenoid rim [6]. Understanding these vascular areas of the subacromial space can help a surgeon minimize bleeding and improve visualization during arthroscopic shoulder surgery.

## POSITIONING

Patient positioning during shoulder arthroscopy can affect visualization. Both BCP and LDP are commonly used in shoulder arthroscopy and are often chosen based on a combination of factors including surgeon and comfort level and type of surgery being performed. Each position has advantages regarding pathology and visualization. For example, the authors utilize the LDP position for cases with shoulder instability but prefer BCP for rotator-cuff pathology. The current authors prefer LDP for cases of stability and BCP for rotator cuff, biceps, and subacromial pathology.

The BCP is commonly used due to its standard anatomic relationship and ease of access to the patient's airway [4]. Another reported benefit of this position is that it allows easier visualization for rotator cuff repairs and open surgical procedures due to its more anatomic orientation. Proponents of this position claim that BCP affords easier portal placement due to better palpation of external anatomic landmarks, and they report no difficulty with visualization of the glenohumeral or subacromial spaces [10]. The BCP also allows manipulation of the arm in various directions to improve visualization of the intended structure. For example, forward flexion can aid in posterior portal placement while internal and external rotation can aid in visualizing the respective posterior and anterior aspects of the shoulder from a posterior viewing portal. This position also allows for easy conversion to an open procedure if required, without additional repositioning or instrumentation.

BCP setup uses an operating-room table in conjunction with a padded articulating headrest. Additionally, there are several commercially available seated positioners. Once in the seated position, the contralateral arm of the patient is placed in an arm holder or tucked and padded to protect the ulnar nerve as well as the common peroneal nerve in the lower extremities. The hips are typically flexed to 45°–60° with the knees flexed to 30° to relieve tension on the sciatic nerve. A mechanical arm holder can be used to hold the operative extremity and typically does not involve traction [4,10-12]. It is crucial that the head remain neutral with regard to extension and rotation to maintain vertebral artery blood flow [4,12].

Potential complications of the BCP include cerebral hypoperfusion and ischemia, cerebral desaturation events, stroke, vision loss, nerve injury, and even death [4,12-14]. These complications are commonly seen during the initial positioning and can be minimized through more gradual movement from a supine to seated position [8]. There is no reported increased risk of mortality for this position [14]. A systolic blood pressure >90 mmHg and the maximum reduction of both systolic blood pressure and mean arterial pressure within <20% of baseline is typically recommended for BCP to decrease the incidence of cerebral hy-


https://doi.org/10.5397/cise.2022.01291

poperfusion while maximizing visualization [12,13].

LDP offers improved visualization and access to the inferior glenoid with less risk of cerebral hypoperfusion and cerebral desaturation events [12,13]. This is the favored position of some surgeons to address cases with instability because of the glenoid access it permits and the ability to manipulate the humeral head out of the surgical field. Increased axial traction of the arm can aid in instability procedures by increasing the distance between the glenoid and humerus. Surgeons that favor the LDP argue that there is increased visualization of the glenohumeral joint, and that the surgeon can operate with the patient's arms at their side as opposed to the abducted BCP position. Positioning the glenoid parallel to the floor affords an anatomic reference point for orientation, and electrocautery bubbles escape laterally, out of the field of view, improving visualization [15].

Contrary to BCP, LDP can be performed with most operating-room tables with the addition of a beanbag or rigid post configuration. The peroneal nerve is carefully padded, and an axillary roll is used to prevent nerve-related complications. The surgical extremity is placed into traction with the use of a sling and weights. The amount of weight needed for appropriate visualization should be carefully considered to avoid a neurovascular traction injury. The balanced traction devices vary from pulley systems to pneumatic or mechanical devices [12,15].

Disadvantages of the LDP include neurovascular injuries related to portal placement and traction on peripheral nerves and the brachial plexus, the potential need for general endotracheal anesthesia, the possible need to re-prep and drape the patient should a conversion to an open procedure be necessary, and the need to reach around the patient for the anterior portal [4,10,15]. In their systematic review, Memon et al. [3] found that fluid extravasation is more prevalent in the LDP.

## BLOOD PRESSURE CONTROL

Blood pressure control remains a concern in shoulder arthroscopy. These concerns are more often associated with BCP as it has been associated with neurologic complications, stroke, and death [8,12,16]. There remains controversy regarding the parameters for controlled hypotension to avoid cerebral hypoperfusion. Anesthesia literature currently cites that a reduction in systolic blood pressure to no lower than 90 mmHg is adequate for cerebral perfusion [17]. Papadonikolakis et al. [18] suggest that blood pressure be carefully monitored at the heart level. The pressure gradient between the calf and heart blood pressure readings proved to be high, and reliance on calf blood pressure can result in an overaggressive decrease in blood pressure.

Studies have been performed to evaluate the effect of permissive hypotension in shoulder arthroscopy. Through accurate hypodynamic monitoring, the literature notes that patients may be able to tolerate a reduction in blood pressure in a safe and controlled manner without neurologic injury [16-18]. This permissive hypotension can be maintained through a combination of BCP, interscalene block, inhaled anesthetics, and IV medication to include beta-blockers [17]. Interscalene brachial plexus block (ISBPB) is effective in providing anesthesia for shoulder procedures, including arthroplasty and fracture work, with excellent results. The block has been shown to reduce perioperative opioid consumption, increase patient satisfaction, and decrease postoperative stay. This block, while effective in BCP, is poorly tolerated in the LDP [19].

Hypotensive bradycardic events (HBEs) and the associated hypotension are also a concern with BCP. Song and Roh [19] conducted a review to examine HBEs in shoulder arthroscopy when combined with ISBPB. They reported an incidence of HBEs under ISBPB around 13%–28%, and most events tended to be transient in nature, occurring without complications. The causative mechanisms for HBEs are not fully understood but may include carotid sinus hypersensitivity and orthostatic syncope. Treatment includes administration of alpha-agonist vasoconstrictors or ephedrine when the HBE is of unknown origin. The authors argue that preventing these events remains a challenge, and that studies aimed at ultrasonography-guided ISBPB might be promising.

## ARTHROSCOPIC PUMP SYSTEMS

There are varying types of commercially available pump systems for arthroscopy. This includes gravity systems, pressure-driven pumps, and pressure- and flow-controlled pumps. A gravity system involves hanging bags of saline several feet above the operative site, with the pressure in the joint ranging from 50–120 mmHg depending on the outflow in the system [20]. Pressure, or single-roller, pumps and pressure-and-flow, or double-roller, pumps both are commercially available to provide intra-articular pressure either by regulating the pressure alone or by regulating the pressure and flow in the system [21,22].

One of the first studies to discuss the use of infusion pumps in arthroscopy was by Bergstrom and Gillquist [23] in 1986. The study examined fluid inflow and outflow as well as postoperative circumference as means of measuring fluid extravasation in patients undergoing knee arthroscopy. They concluded that the use of an arthroscopy pump allowed controlled, higher intra-articular pressures and greater joint distention to achieve better visual-

ization and a more useful tool for arthroscopy.

In their 1995 paper, Ogilvie-Harris et al. [22] prospectively compared two pump systems. One pump allowed for pressure control but not flow, while the other allowed for control of both pressure and flow. One of the two pumps was utilized in cases of knee, ankle, or shoulder arthroscopy. Visualization and fluid extravasation were measured with a subjective scoring system. The study concluded that the pump with both pressure and flow control independently led to significantly improved visualization.

The advantage of a pump system is the ability to achieve a higher, constant, intra-articular pressure that could theoretically improve visualization [23,24]. Some systems only control pressure, while others, known as dual-roller pumps, control both pressure and fluid flow. These dual-roller pumps can decrease bleeding, decrease operative time, and improve visualization [24-26]. Complications of these systems include joint damage, fluid extravasation, increased postoperative pain, and risk of compartment syndrome [24,27]. Studies on both gravity and fluid pump systems suggest that both are safe and effective for use in arthroscopy [20,21,24].

Gravity and automated fluid pump systems are commercially available and widely used in arthroscopy. Some studies note that gravity systems are lower cost, effective, reliable, and do not deform the joint capsule with excess pressure [24,27]. Proponents of gravity systems suggest that they are safer because they are not expected to reach high intra-articular pressures and avoid excess fluid extravasation. The disadvantage is that the pressure is determined by bag height and will not yield as high intra-articular pressures as other systems and could inhibit visualization [24].

Careful understanding of automated pump systems is required to ensure safe surgery. Taha et al. [28] compared three arthroscopic pump systems and compared intraoperative pump pressures with an intra-articular spinal needle pressure measurement. Actual intra-articular pressure was significantly higher than the set pressure in all three pump machines. The authors suggested using the intra-articular spinal needle pressure measurement as a tool to calibrate commercially available pumps to allow more accurate pressure readings and to minimize the risk of intraoperative complications. The current authors utilize a pressure and flow automated fluid management system that is typically set to 35 mmHg for shoulder arthroscopy.

## TURBULENCE CONTROL

In their paper on turbulence control, Burkhart et al. [29] discuss the Bernoulli effect. According to Bernoulli's principle, a fluid stream will create a perpendicular force against itself. The moving arthroscopy fluid leaking through the anterior portal creates a suction effect on the surrounding blood vessels, resulting in mixture of blood and turbulence that obscures visualization. The authors posit that a simple cannula or digital pressure stops this pressure gradient, diminishes the Bernoulli effect, and improves visualization. Furthermore, any turbulence will decrease visualization, and steps should be taken to decrease fluid leakage and the pressure gradient. Surgical techniques that limit fluid leaking and extravasation can help increase local pressure and diminish turbulence, leading to improved visualization.

## EPINEPHRINE

Intra-articular bleeding is a major cause of decreased visualization. Conventionally, cold irrigation fluid, electrocautery, and permissive hypotension have been used to improve visual clarity by reducing bleeding because tourniquets are not technically possible in shoulder arthroscopy [30]. EPI is used as an alternative to these techniques. EPI is a vasoconstrictor that, when administered into the shoulder, acts locally to constrict blood vessels that cause bleeding in shoulder arthroscopy [30]. The addition of EPI to arthroscopy fluid to reduce bleeding and improve clarity remains a topic of interest [30-34].

Two studies found significantly increased visual clarity when comparing EPI injected into arthroscopic fluid with that into standard saline. The EPI dosage in these papers was 0.33 mg/L, though they comment that more research is needed to establish the optimal concentration. Neither study reported adverse reactions in either group [30,31].

In their systematic review and meta-analysis, Kuo et al. [32] evaluated three randomized control trials with 238 participants. They found that the use of EPI in arthroscopy fluid provided significantly better visual clarity and reduced the need for increased pump pressure compared with the group with standard saline fluid. This review also found no records of adverse events.

Another study found improved visualization but did not find a difference in operative time or volume of irrigation fluid used, prompting the question of the clinical significance of this technique [33]. Cost has also been a concern in the use of EPI, with one 30-mL bottle costing $237 in 2019. Stetson et al. [35] highlight this expenditure in their article and note that foregoing EPI lead to about $900 in cost savings per shoulder arthroscopy case. While addition of EPI to arthroscopy fluid has demonstrated promise, it is not without theoretical risk. Due to the different effects on adrenergic receptors, Chierichini et al. [36] sought to compare norepinephrine with EPI for patients in the BCP for improving visual clarity while lowering the risk of cardiovascular


https://doi.org/10.5397/cise.2022.01291

instability. They found that continuous administration of 0.66 mg/L norepinephrine in arthroscopic fluid reduced HBE incidence and similarly improved visual clarity.

Use of EPI in shoulder arthroscopy has also been associated with cardiomyopathy [37], arrhythmias [38], and encephalopathy [39], though these instances are rare. Knowledge of these potential complications is crucial for surgical and anesthesia teams to properly respond in the event of a life-threatening situation. For improved visualization, the current authors use 1mg/mL of EPI in 3 L of normal saline as arthroscopic fluid in both BCP and LDP. One author injects 10 mL of 1% lidocaine with EPI into the subacromial space prior to surgery for cases performed in the BCP.

## TRANEXAMIC ACID

TXA is an analog of the amino acid lysine and inhibits fibrinolysis by acting as a competitive inhibitor to the binding site on plasminogen [40]. It has been shown to reduce blood loss and need for transfusion [40,41]. Orthopedic literature has explored the use of TXA in trauma [42], arthroplasty [43], and spine surgery [44] and confirms promising results. TXA has been associated with reduced blood loss [43,45] and decreased hematoma formation [43] and is now being investigated for improving visualization in shoulder arthroscopy [40,46]. In shoulder arthroscopy procedures, TXA has been shown to improve visual clarity, lower postoperative hemarthrosis incidence, and decrease postoperative pain when administered via IV [40,46,47]. No significant difference was found between intra-articular and IV administration of TXA in a study on knee arthroscopy outcomes [48], though studies on shoulder arthroscopy cases are needed.

Despite being shown to be effective in different orthopedic subspecialties, TXA use remains controversial. Cited concerns for TXA use include thromboembolic events [49], myocardial infarction [50], visual disturbances [49], and chondrotoxicity [51]. However, multiple studies evaluating the safety of this drug have not found an increase in thromboembolic events regardless of administration route [43,52]. To improve visualization, the current authors administer 1 g of IV TXA after antibiotics at the start of surgery for BCP cases.

## EPI VERSUS TRANEXAMIC ACID

TXA and EPI both offer promising results when applied to shoulder arthroscopy and improved visualization. In a comparison of the two, there was no significant difference in visual clarity as determined by visual analog scale, and no adverse events were recorded in either group. The current authors conclude that the addition of TXA to irrigation fluid may provide similar visual effects as EPI [53].

## CONCLUSIONS

Shoulder arthroscopy is a common procedure that requires visual clarity for safe and effective surgery. There are many factors that may impact visualization during arthroscopic shoulder surgery, including vascular anatomy, positioning, blood pressure control, fluid flow in the joint, and adjuncts to arthroscopic irrigation fluid. Orthopedic surgeons should understand the risks and benefits of these factors as well as patient health and pathology to improve visualization during arthroscopic shoulder surgery. Understanding the anatomy, positioning, blood-pressure control, fluid flow in the joint, and adjuncts to arthroscopic irrigation fluid can all lend themselves to a more uniform, reproducible experience.

## NOTES

### ORCID

Emily R. McDermott https://orcid.org/0000-0001-8418-7893
David J. Tennent https://orcid.org/0000-0002-1740-9174
Daniel J. Song https://orcid.org/0000-0002-2214-5986

### Author contributions

Conceptualization: ERM, DJT, DJS. Data curation: ERM, DJT, DJS. Supervision: DJT, DJS. Writing – original draft: ERM. Writing – review & editing: ERM, DJT, DJS.

### Conflict of interest

None.

### Funding

None.

### Data availability

None.

### Acknowledgments

None.

## REFERENCES

1. Jain NB, Higgins LD, Losina E, Collins J, Blazar PE, Katz JN. Epidemiology of musculoskeletal upper extremity ambulatory surgery in the United States. BMC Musculoskelet Disord 2014;

15:4.
2. Jain NB, Peterson E, Ayers GD, Song A, Kuhn JE. US geographical variation in rates of shoulder and knee arthroscopy and association with orthopedist density. JAMA Netw Open 2019;2:e1917315.
3. Memon M, Kay J, Gholami A, Simunovic N, Ayeni OR. Fluid extravasation in shoulder arthroscopic surgery: a systematic review. Orthop J Sports Med 2018;6:2325967118771616.
4. Rojas J, Familiari F, Bitzer A, Srikumaran U, Papalia R, McFarland EG. Patient positioning in shoulder arthroscopy: which is best. Joints 2019;7:46–55.
5. Lands VW, Avery DM, Malige A, Stoltzfus J, Gibson BW, Carolan GF. Rating visualization in shoulder arthroscopy: a comparison of the visual analog scale versus a novel shoulder arthroscopy grading scale. J Orthop Allied Sci 2019;7:8–11.
6. Yepes H, Al-Hibshi A, Tang M, Morris SF, Stanish WD. Vascular anatomy of the subacromial space: a map of bleeding points for the arthroscopic surgeon. Arthroscopy 2007;23:978–84.
7. Crimmins IM, Mulcahey MK, O'Brien MJ. Diagnostic shoulder arthroscopy: surgical technique. Arthrosc Tech 2019;8:e443–9.
8. Higgins JD, Frank RM, Hamamoto JT, Provencher MT, Romeo AA, Verma NN. Shoulder arthroscopy in the beach chair position. Arthrosc Tech 2017;6:e1153–8.
9. Meyer M, Graveleau N, Hardy P, Landreau P. Anatomic risks of shoulder arthroscopy portals: anatomic cadaveric study of 12 portals. Arthroscopy 2007;23:529–36.
10. Peruto CM, Ciccotti MG, Cohen SB. Shoulder arthroscopy positioning: lateral decubitus versus beach chair. Arthroscopy 2009;25:891–6.
11. Mannava S, Jinnah AH, Plate JF, Stone AV, Tuohy CJ, Freehill MT. Basic shoulder arthroscopy: beach chair patient positioning. Arthrosc Tech 2016;5:e731–5.
12. Li X, Eichinger JK, Hartshorn T, Zhou H, Matzkin EG, Warner JP. A comparison of the lateral decubitus and beach-chair positions for shoulder surgery: advantages and complications. J Am Acad Orthop Surg 2015;23:18–28.
13. Murphy GS, Greenberg SB, Szokol JW. Safety of beach chair position shoulder surgery: a review of the current literature. Anesth Analg 2019;129:101–18.
14. Rozet I, Vavilala MS. Risks and benefits of patient positioning during neurosurgical care. Anesthesiol Clin 2007;25:631–53.
15. Hamamoto JT, Frank RM, Higgins JD, Provencher MT, Romeo AA, Verma NN. Shoulder arthroscopy in the lateral decubitus position. Arthrosc Tech 2017;6:e1169–75.
16. Jo YY, Jung WS, Kim HS, Chang YJ, Kwak HJ. Prediction of hypotension in the beach chair position during shoulder arthroscopy using pre-operative hemodynamic variables. J Clin Monit Comput 2014;28:173–8.
17. Gillespie R, Shishani Y, Streit J, et al. The safety of controlled hypotension for shoulder arthroscopy in the beach-chair position. J Bone Joint Surg Am 2012;94:1284–90.
18. Papadonikolakis A, Wiesler ER, Olympio MA, Poehling GG. Avoiding catastrophic complications of stroke and death related to shoulder surgery in the sitting position. Arthroscopy 2008;24:481–2.
19. Song SY, Roh WS. Hypotensive bradycardic events during shoulder arthroscopic surgery under interscalene brachial plexus blocks. Korean J Anesthesiol 2012;62:209–19.
20. West HS. Editorial commentary: to pump or not to pump?: gravity versus fluid pumps for shoulder and knee arthroscopy. Arthroscopy 2018;34:3139–40.
21. Ross JA, Marland JD, Payne B, Whiting DR, West HS. Do arthroscopic fluid pumps display true surgical site pressure during hip arthroscopy. Arthroscopy 2018;34:126–32.
22. Ogilvie-Harris DJ, Weisleder L. Fluid pump systems for arthroscopy: a comparison of pressure control versus pressure and flow control. Arthroscopy 1995;11:591–5.
23. Bergstrom R, Gillquist J. The use of an infusion pump in arthroscopy. Arthroscopy 1986;2:41–5.
24. Walker-Santiago R, Maldonado DR, Domb BG, Lall AC. Fundamentals of arthroscopy fluid management and strategies to safely improve visualization. J Am Acad Orthop Surg 2021;29:862–71.
25. Tuijthof GJ, de Vaal MM, Sierevelt IN, Blankevoort L, van der List MP. Performance of arthroscopic irrigation systems assessed with automatic blood detection. Knee Surg Sports Traumatol Arthrosc 2011;19:1948–54.
26. Sieg R, Bear R, Machen MS, Owens BD. Comparison of operative times between pressure and flow-control pump versus pressure-control pump for ACL reconstruction. Orthopedics 2009;32:orthosupersite.com/view.asp?rID=43767.
27. Mayo M, Wolsky R, Baldini T, Vezeridis PS, Bravman JT. Gravity fluid flow more accurately reflects joint fluid pressure compared with commercial peristaltic pump systems in a cadaveric model. Arthroscopy 2018;34:3132–8.
28. Taha ME, Schneider K, Smith MM, Cunningham G, Young AA, Cass B. Accuracy of arthroscopic fluid pump systems in shoulder surgery: a comparison of 3 different pump systems. J Shoulder Elbow Surg 2020;29:2626–31.
29. Burkhart SS, Danaceau SM, Athanasiou KA. Turbulence control as a factor in improving visualization during subacromial shoulder arthroscopy. Arthroscopy 2001;17:209–12.
30. Jensen KH, Werther K, Stryger V, Schultz K, Falkenberg B. Arthroscopic shoulder surgery with epinephrine saline irrigation.


https://doi.org/10.5397/cise.2022.01291

Arthroscopy 2001;17:578–81.
31. van Montfoort DO, van Kampen PM, Huijsmans PE. Epinephrine diluted saline-irrigation fluid in arthroscopic shoulder surgery: a significant improvement of clarity of visual field and shortening of total operation time. a randomized controlled trial. Arthroscopy 2016;32:436–44.
32. Kuo LT, Chen CL, Yu PA, Hsu WH, Chi CC, Yoo JC. Epinephrine in irrigation fluid for visual clarity in arthroscopic shoulder surgery: a systematic review and meta-analysis. Int Orthop 2018;42:2881–9.
33. Avery DM 3rd, Gibson BW, Carolan GF. Surgeon-rated visualization in shoulder arthroscopy: a randomized blinded controlled trial comparing irrigation fluid with and without epinephrine. Arthroscopy 2015;31:12–8.
34. Veado MA, Teixeira BS, Castro NC, Costa LA. Is it advantageous to add epinephrine to the arthroscopic infusion solution for the treatment of rotator cuff injury. Rev Bras Ortop 2013;48:268–71.
35. Stetson WB, Morgan SA, Polinsky S, Chung B, Hung NJ. Cost effective technique of shoulder arthroscopy without the use of epinephrine in irrigation solution. Arthrosc Tech 2021;10:e411–8.
36. Chierichini A, Frassanito L, Vergari A, et al. The effect of norepinephrine versus epinephrine in irrigation fluid on the incidence of hypotensive/bradycardic events during arthroscopic rotator cuff repair with interscalene block in the sitting position. Arthroscopy 2015;31:800–6.
37. Gicquel-Schlemmer B, Beller JP, Mchalwat A, Gicquel P. Fatal Takotsubo cardiomyopathy due to epinephrine in shoulder arthroscopy. Orthop Traumatol Surg Res 2015;101:981–2.
38. Karns JL. Epinephrine-induced potentially lethal arrhythmia during arthroscopic shoulder surgery: a case report. AANA J 1999;67:419–21.
39. Gharabawy R, Pothula VR, Rubinshteyn V, Silverberg M, Gave AA. Epinephrine-induced posterior reversible encephalopathy syndrome: a case report. J Clin Anesth 2011;23:505–7.
40. Liu YF, Hong CK, Hsu KL, et al. Intravenous administration of tranexamic acid significantly improved clarity of the visual field in arthroscopic shoulder surgery. a prospective, double-blind, and randomized controlled trial. Arthroscopy 2020;36:640–7.
41. Kirsch JM, Bedi A, Horner N, et al. Tranexamic acid in shoulder arthroplasty: a systematic review and meta-analysis. JBJS Rev 2017;5:e3.
42. Gausden EB, Qudsi R, Boone MD, O'Gara B, Ruzbarsky JJ, Lorich DG. Tranexamic acid in orthopaedic trauma surgery: a meta-analysis. J Orthop Trauma 2017;31:513–9.
43. Fillingham YA, Ramkumar DB, Jevsevar DS, et al. Tranexamic acid use in total joint arthroplasty: the clinical practice guidelines endorsed by the American Association of Hip and Knee Surgeons, American Society of Regional Anesthesia and Pain Medicine, American Academy of Orthopaedic Surgeons, Hip Society, and Knee Society. J Arthroplasty 2018;33:3065–9.
44. Rahmani R, Singleton A, Fulton Z, Pederson JM, Andreshak T. Tranexamic acid dosing strategies and blood loss reduction in multilevel spine surgery: a systematic review and network meta-analysis: tranexamic acid for multilevel spine surgery. N Am Spine Soc J 2021;8:100086.
45. Hartland AW, Teoh KH, Rashid MS. Clinical effectiveness of intraoperative tranexamic acid use in shoulder surgery: a systematic review and meta-analysis. Am J Sports Med 2021;49:3145–54.
46. Belk JW, McCarty EC, Houck DA, Dragoo JL, Savoie FH, Thon SG. Tranexamic acid use in knee and shoulder arthroscopy leads to improved outcomes and fewer hemarthrosis-related complications: a systematic review of level I and II studies. Arthroscopy 2021;37:1323–33.
47. Ersin M, Demirel M, Büget Mİ, Edipoğlu İS, Atalar AC, Erşen A. The effect of intravenous tranexamic acid on visual clarity during arthroscopic rotator cuff repair: a randomized, double-blinded, placebo-controlled pilot study. Acta Orthop Traumatol Turc 2020;54:572–6.
48. Ma R, Wu M, Li Y, et al. The comparative efficacies of intravenous administration and intra-articular injection of tranexamic acid during anterior cruciate ligament reconstruction for reducing postoperative hemarthrosis: a prospective randomized study. BMC Musculoskelet Disord 2021;22:114.
49. Lin ZX, Woolf SK. Safety, efficacy, and cost-effectiveness of tranexamic acid in orthopedic surgery. Orthopedics 2016;39:119–30.
50. Ker K, Edwards P, Perel P, Shakur H, Roberts I. Effect of tranexamic acid on surgical bleeding: systematic review and cumulative meta-analysis. BMJ 2012;344:e3054.
51. Parker JD, Lim KS, Kieser DC, Woodfield TB, Hooper GJ. Is tranexamic acid toxic to articular cartilage when administered topically?: what is the safe dose. Bone Joint J 2018;100:404–12.
52. Reale D, Andriolo L, Gursoy S, Bozkurt M, Filardo G, Zaffagnini S. Complications of tranexamic acid in orthopedic lower limb surgery: a meta-analysis of randomized controlled trials. Biomed Res Int 2021;2021:6961540.
53. Bayram E, Yıldırım C, Ertürk AK, Yılmaz M, Atlıhan D. Comparison of the efficacy of irrigation with epinephrine or tranexamic acid on visual clarity during arthroscopic rotator cuff repair: a double-blind, randomized-controlled study. Jt Dis Relat Surg 2021;32:115–21.

Case Report

Clin Shoulder Elbow 2023;26(4):462-466
https://doi.org/10.5397/cise.2022.00899

CiSE
Clinics in Shoulder and Elbow

eISSN 2288-8721

# Anterior interosseous nerve palsy in the early postoperative period after open capsular release for elbow stiffness: a case report

**Christopher A. Colasanti, Michael Boin, Jacques Hacquebord, Mandeep S. Virk**

*Department of Orthopedic Surgery, New York University Langone Health, New York, NY, USA*

Surgical release of elbow contracture is associated with injury to structures traversing the elbow. To date, only one other case report has been published describing anterior interosseous nerve (AIN) palsy that developed immediately after open elbow contracture release and debridement. Here we describe the unique case of a patient that developed AIN palsy 1 week after operation, including magnetic resonance imaging and electrodiagnostic studies, to shed some light on the etiology of this rare complication.

**Keywords:** Anterior interosseous nerve palsy; Elbow; Nerve compression; Nerve injury; Basic science

Degenerative osteoarthritis of the elbow is uncommon, affecting less than 2% of the general population [1]. It can cause severe disabling symptoms such as pain, locking and stiffness [1]. Several methods of arthroscopic and open surgical treatment have been described, resulting in improvements in pain, range of motion and patient satisfaction [1]. However, while arthroscopic release is minimally invasive, there are reports of higher incidences of nerve injury compared to open capsular debridement. In a survey distributed to over 372 members of the American Society for Hand Surgery, 60% of hand surgeons described at least one peripheral nerve injury after elbow arthroscopy over a 5-year period, with nearly half requiring operative intervention [2]. In a case report, Desai et al. [2] was the first to describe a direct traumatic injury to the anterior interosseous nerve (AIN) after arthroscopic capsular debridement of an elbow.

AIN palsy is an uncommon cause of hand weakness that comprises less than 1% of all upper extremity nerve palsies [3]. AIN syndrome was first described by Parsonage-Turner and then reported as a distinctive entity by Kiloh and Nevin in 1952 [3,4]. AIN palsy after elbow contracture release is a rare occurrence compared to more common etiologies of AIN palsy including trauma, iatrogenic injury from surgery, postoperative dressings, crutches, and venipuncture [3,5]. To date, only one other case report has been published describing an AIN palsy that developed immediately after open elbow contracture release and debridement [5]. This case report describes a patient who developed delayed-onset AIN palsy approximately 1 week after open elbow release with a protracted course and partial recovery and provides a distinct injury mechanism.

Approval for this study was waived by the Institutional Review Board, and informed consent was obtained from the patient.

## CASE REPORT

### Initial Evaluation

A 42-year-old left hand-dominant male police officer presented to the office with complaints of 15 years of worsening right elbow pain and limited range of motion. His past medical history was

Received: February 28, 2022 Revised: September 6, 2022 Accepted: September 21, 2022
Correspondence to: Mandeep S. Virk
Division of Shoulder and Elbow, Department of Orthopedic Surgery, New York University Langone Health, 246 E 20th St, New York, NY 10003, USA
Tel: +1-646-356-9408, Fax: +1-646-356-9413, E-mail: mandeep.virk@nyumc.org

Copyright© 2023 Korean Shoulder and Elbow Society.
This is an Open Access article distributed under the terms of the Creative Commons Attribution Non-Commercial License (http://creativecommons.org/licenses/by-nc/4.0/) which permits unrestricted non-commercial use, distribution, and reproduction in any medium, provided the original work is properly cited.

significant for herpes simplex virus type 2 (HSV-2), which was treated with daily acyclovir. His elbow range of motion included a flexion-extension (FE) arc of 40°–100° and supination-pronation arc of 50°–70° with pain present at the terminal range of motion. There were no symptoms of ulnar neuritis and no signs of ulnar nerve instability or compression neuropathy. Radiographs and magnetic resonance imaging (MRI) of his right elbow demonstrated osteoarthritic changes with osteophyte formation at the radiocapitellar and ulnohumeral joint and evidence of multiple intra-articular loose bodies (Fig. 1). After failure of extended nonsurgical treatment, persistent elbow pain at the end ranges of motion, and mechanical symptoms (locking and catching), the patient elected to proceed with open elbow contracture release, debridement and removal of loose bodies.

### Surgery

The patient underwent open elbow contracture release under regional anesthesia. A lateral column/lateral ulnar collateral ligament sparing approach was utilized. Anterior and posterior capsulectomy, removal of loose bodies, deepening of the radial, coronoid and olecranon fossa and exostectomy of the tip of the olecranon and coronoid were performed through this surgical approach. There were no intraoperative complications and intraoperative elbow range of motion after release included FE arc of 0°–140° and supination-pronation arc of 80°–80°. Patient had a normal neurological exam after the block wore off. Supervised physical therapy was started on postoperative day (POD) 1 and consisted of active and active assisted motion exercises; edema control modalities including edema sleeve, static splinting and nighttime elevation were utilized.

### Postoperative Follow-up

On POD 7, the patient reported a sudden inability to bend the tip of his right thumb after he reflexively reached out to break a fall, causing hyperextension of his operative elbow. He reported an immediate tearing sensation along the volar aspect of his forearm, followed by tingling in his thumb. He reported considerable pain localized to his elbow, which improved with time; however, he subsequently noticed mild pain and weakness in thumb flexion. The patient was seen in the office the next day and had ecchymosis around his elbow with postoperative pain. The operative arm was sensate to light touch in the distribution of C5–T1 dermatomes but had weakness (3+/5 in thumb flexion) and tingling on the radial side of the thumb. He was able to actively flex the 3rd, 4th, and 5th digits without difficulty. On POD 12 the patient's tingling around his thumb had resolved; however, he was now experiencing tingling localized to his index finger with difficulty pinching his thumb and index finger. There were no other symptoms localized to the operative arm or in the neck.

Diagnostic and imaging studies to rule out hematoma in the elbow leading to AIN palsy versus a spontaneous rupture of flexor pollicis longus (FPL) were conducted. MRI of the elbow showed postoperative changes around the elbow without any considerable hematoma. MRI and ultrasound of the wrist demonstrated asymmetric fatty atrophy with volume loss of the right pronator quadratus (PQ) muscle compared to the left, suggestive of an anterior interosseous palsy but no lesions along the course of the AIN (Fig. 2). On MRI neurogram, there was intramuscular edema within the flexor digitorum profundus (FDP), FPL, and PQ. The AIN, posterior interosseous nerve, ulnar, radial and median nerve were all in continuity and there was no evidence of nerve thickening or neuroma. Electrodiagnostic studies (electromyography and nerve conduction studies) demonstrated abnormal sharp waves, abnormal latency, and abnormal compound motor action potentials at both the FPL and opponens pollicis (Fig. 3). Six months postoperative both his FPL and FDP to the index finger were 3/5, at which time nerve exploration of the AIN was discussed. Despite what he reported as "clumsiness" of his fingers he continued to work with both occupational and physical therapy and declined to have exploratory surgery. One-year postoperative our patient still had some weakness (4/5 FPL and FDP) but was now able to perform pinching and grasping function with index finger and thumb. On the final 2-year follow-up, the patient's elbow range of motion was from 10°–130° for FE arc and 60°–70° for supination-pronation arc with a Quick Disabilities of the Arm, Shoulder and Hand (QuickDASH) questionnaire score of 11.4. Patient had similar strength at 2 years as he did at 1 year 4/5 for FPL and FDP.

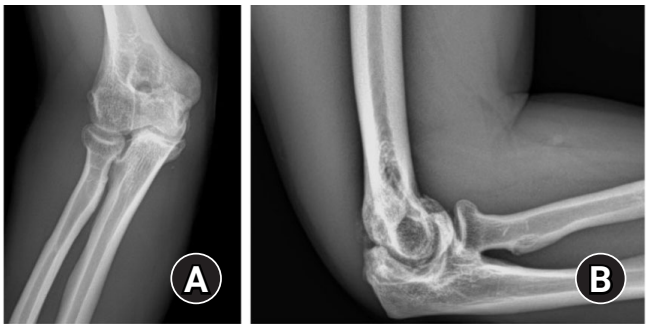


**Fig. 1.** Preoperative radiographs including (A) anteroposterior and (B) lateral of the right elbow demonstrating osteoarthritic changes with osteophyte formation at the radiocapitellar and ulnohumeral joint and evidence of multiple intra-articular loose bodies.

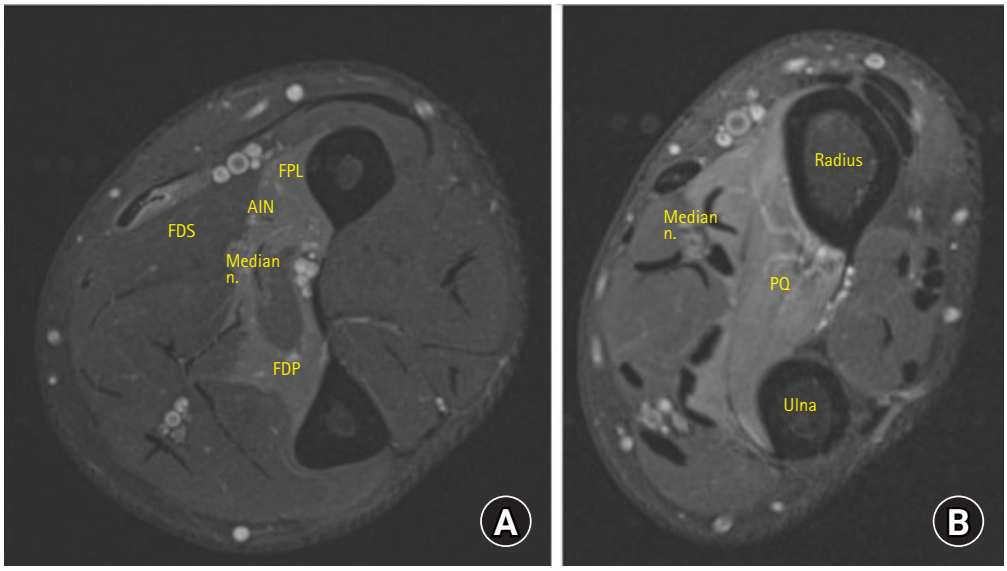


**Fig. 2.** Magnetic resonance imaging neurogram: axial cuts of the forearm and wrist demonstrating (A) intramuscular edema within the flexor digitorum profundus (FDP) and flexor pollicis longus (FPL), with both the median nerve and anterior interosseous nerve (AIN) labeled. (B) Intramuscular edema and mild fatty atrophy of the pronator quadratus (PQ). FDS: flexor digitorum superficialis.

## DISCUSSION

In this case report we present a case of AIN palsy that occurred seven days after open elbow contracture release. Although AIN palsy is rare, especially after open elbow contracture release, this case is unique in that the presentation of AIN palsy was delayed and our patient continues to have residual deficits 24 months out from the initial event. Furthermore, the utilization of advanced imaging and electrodiagnostic studies proved to be useful in identifying the location of our patient's deficit.

The AIN innervates the deep muscles of the forearm, including the FPL, the FDP to the index and middle fingers, and the PQ muscle. AIN syndrome is typically characterized by forearm pain and partial or complete dysfunction of AIN-innervated muscles [2]. AIN palsies can manifest clinically as weakness in flexion of the interphalangeal joint of the thumb, distal interphalangeal joints of the index and middle fingers, and possibly with weakness of pronation with the elbow in flexion [3]. Characteristic physical exam findings include the "O" sign (Kiloh-Nevin sign) due to inability to actively flex the interphalangeal joint of the thumb with the distal interphalangeal joint of the index finger [3]—all presenting symptoms in our patient.

The pathophysiology and etiology of AIN syndrome remain unclear and include elbow and forearm trauma, immune-mediated inflammatory neuritis, and spontaneous idiopathic cases [2,3,6,7]. Several mechanisms have been proposed to explain postoperative anterior interosseous syndrome after upper extremity surgery [5]. Peripheral neuropathy as a complication after regional anesthesia, external compression, and Parsonage Turner syndrome (PTS) [3,8] have been described as potential etiologies [3]. Our patient had two risk factors for an acute episode of PTS postoperative, which included acyclovir therapy for HSV-2 as well as suffering from an upper respiratory viral infection prior to his elbow procedure; however, an isolated AIN palsy as solitary presentation is very uncommon [4]. The part of the AIN that descends under the flexor digitorum superficialis (FDS) arch is prone to traction injury and, has limited capacity to tolerate stretch. It is likely that our patient's long standing elbow contracture, increased postoperative range of motion and the sudden eccentric stretching episode of our patient when he braced himself while falling led to a traction injury of the AIN in the transition zone. This mechanism could also potentially explain the etiology in the prior case report by Katolik and Cohen [5], where the authors proposed that intraoperative passive stretching of the elbow in extension during surgery was the most likely etiology of immediate postoperative AIN palsy.

Typically, imaging is not helpful for diagnosing AIN syndrome because imaging is usually unremarkable [2,3,9]. However, Dunn et al. [9] and Grainger et al. reported that the most reliable indicator of neuritic AIN palsy was edema within the PQ. These signal changes reflect a shift of muscle water from the intracellular to the extracellular space in the absence of a net increase in total muscle water content occurring within the first 24 hours after muscle denervation [9]. This correlates closely with our patient;


https://doi.org/10.5397/cise.2022.00899

| EMG Summary Table | | | | | | | | | | | |
|---|---|---|---|---|---|---|---|---|---|---|---|
| | | | Spontaneous | | | | | MUAP | | | Recruitment |
| Muscle | Nerve | Roots | IA | Fib | PSW | Fasc | H.F. | Amp | Dur. | PPP | Pattern |
| R. Biceps brachii | Musculocutaneous | C5-C6 | N | None | None | None | None | N | N | N | N |
| R. Triceps brachii | Radial | C6-C8 | N | None | None | None | None | N | N | N | N |
| R. Pronator teres | Median | C6-C7 | N | None | None | None | None | N | N | N | N |
| R. Flexor digitorum profundus (Median) | Median | C7-T1 | N | None | None | None | None | N | N | N | N |
| R. Flexor pollicis longus | Anterior interosseous | C7-C8 | N | 1+ | 2+ | None | None | 1- | 1- | N | Discrete |
| R. Abductor pollicis brevis | Median | C8-T1 | N | None | None | None | None | N | N | N | N |

| EMG Summary Table | | | | | | | | | | | |
|---|---|---|---|---|---|---|---|---|---|---|---|
| | | | Spontaneous | | | | | MUAP | | | Recruitment |
| Muscle | Nerve | Roots | IA | Fib | PSW | Fasc | H.F. | Amp | Dur. | PPP | Pattern |
| R. Opponens pollicis | Median | C8-T1 | 1+ | None | None | None | None | 1- | 1- | N | Reduced |
| R. Flexor carpi ulnaris | Ulnar | C7-T1 | N | None | None | None | None | N | N | N | N |

| Nerve / Sites | Muscle | Latency ms | Amplitude mV | Rel Amp % | Duration ms | Segments | Distance mm | Lat Diff ms | Velocity m/s |
|---|---|---|---|---|---|---|---|---|---|
| Wrist | ADM | 2.08 | 9.2 | 100 | 5.31 | Wrist - ADM | 70 | | |
| B.Elbow | ADM | 6.04 | 8.0 | 87.7 | 5.47 | B.Elbow - Wrist | 230 | 3.96 | 58 |
| A.Elbow | ADM | 7.97 | 6.8 | 84.7 | 5.68 | A.Elbow - B.Elbow | 60 | 1.93 | 31 |
| Axilla | ADM | 10.57 | 8.0 | 117 | 5.83 | Axilla - A.Elbow | 195 | 2.60 | 75 |
| | | | | | | A.Elbow - Wrist | | 5.89 | |

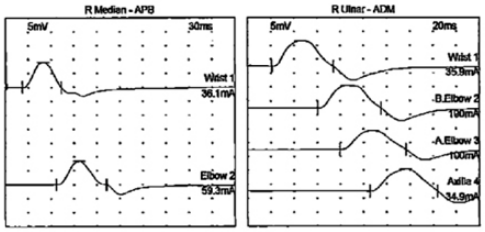


**Fig. 3.** Electrodiagnostic studies (electromyography [EMG] and nerve conduction) demonstrating abnormal sharp waves, abnormal latency, and abnormal compound motor action potentials at both the flexor pollicis longus and opponents pollicis. MUAP: motor unit action potential, IA: insertion activity, Fib: fibrillations, PSW: positive sharp waves, Fasc: fasciculations, H.F: high frequency, Amp: amplitude, Dur: durations, PPP: polyphasic potential, R: right, N: normal, B: below, A: above, ADM: abductor digiti minimi, APB: abductor pollicis brevis.

both ultrasound and MRI neurogram demonstrated intramuscular edema within the FDP, FPL, and PQ. In our patient, electromyography demonstrated abnormal sharp waves, abnormal latency, and abnormal compound motor action potentials at both the FPL and opponens pollicis allowing us to conclude that the pathology was within the transition zone, as the nerve dips below the aponeurotic arch of the FDS.

The literature about treatment of AIN palsies of all causes does not support a clear advantage to surgical exploration and decompression [5]. Furthermore, the timing of surgical exploration is controversial. In a case series of 20 patients with acute AIN syndrome, Schantz and Riegels-Nielsen [10] demonstrated satisfactory results in 11 of 15 patients (73%) treated surgically versus 2 of 5 of those treated with observation. The authors ultimately concluded that AIN exploration is the treatment of choice. However, this interpretation may be misleading, because many of the

patients treated surgically were treated before the mean recovery time of those patients who were successfully treated non-surgically. We offered the option of surgical exploration of the AIN to our patient after 6 months of nonsurgical management. Although, the prognosis for spontaneous recovery is relatively good for AIN palsy, our patient did not have any signs of recovery until 9 months after the inciting event. At the last telehealth visit at 24 months he continued to have some residual weakness of his thumb with flexion.

In a case report of two patients who underwent open elbow capsular debridement, Katolik and Cohen [5] described immediate postoperative AIN palsy in both patients. The authors attributed their patient's AIN palsy to passive stretching of the elbow in extension after surgical release to correct residual elbow extension deficit [5]. Similar to the two cases described by Katolik and Cohen [5], our patient also developed an AIN palsy after open capsular release via lateral exposure. However, what makes our case unique is the patient developed an AIN palsy 1-week postoperative after reflexively extending his right elbow in an attempt to break a fall. We believe that trauma played a role in our patient's delayed presentation, but this extent of trauma in a nonsurgical setting would not typically be sufficient to cause AIN palsy. Additionally, the two cases described by Katolik and Cohen [5] had complete resolution of their symptoms by 12 months postoperatively; however, our patient did not recover despite being close to 24 months out from surgery, thereby demonstrating that not all AIN palsies after open elbow release happen immediately after surgery or recover spontaneously. Additionally, we report findings of advanced imaging (MRI) and electrodiagnostic studies in this case report, shedding some light on the etiology of this rare complication.

In conclusion, we describe a case of delayed-onset AIN palsy developing one week after open elbow contracture release. We believe this was most likely a result of a stretch injury to the AIN nerve in the transition zone in the immediate postoperative period. Advanced imaging and electrodiagnostic studies demonstrated complete nerve continuity with no extrinsic compression. Although the overall prognosis for AIN palsy is generally good, AIN injury after elbow surgery can take a long time to recover. It is unclear, based on this single case report, if recovery would have been more rapid with surgical nerve exploration and decompression.

# NOTES

### Author contributions

Writing – original draft: CAC. Writing – review & editing: CAC, MB, JH, MSV.

### Conflict of interest

None.

### Funding

None.

### Data availability

None.

### Acknowledgments

None.

# REFERENCES

1. Guerrero EM, Bullock GS, Helmkamp JK, et al. The clinical impact of arthroscopic vs. open osteocapsular débridement for primary osteoarthritis of the elbow: a systematic review. J Shoulder Elbow Surg 2020;29:689-98.
2. Desai MJ, Mithani SK, Lodha SJ, Richard MJ, Leversedge FJ, Ruch DS. Major peripheral nerve injuries after elbow arthroscopy. Arthroscopy 2016;32:999-1002.
3. Chi Y, Harness NG. Anterior interosseous nerve syndrome. J Hand Surg Am 2010;35:2078-80.
4. Feinberg JH, Radecki J. Parsonage-turner syndrome. HSS J 2010;6:199-205.
5. Katolik LI, Cohen MS. Anterior interosseous nerve palsy after open capsular release for elbow stiffness: report of 2 cases. J Hand Surg Am 2009;34:288-91.
6. Nagano A. Spontaneous anterior interosseous nerve palsy. J Bone Joint Surg Br 2003;85:313-8.
7. Rodner CM, Tinsley BA, O'Malley MP. Pronator syndrome and anterior interosseous nerve syndrome. J Am Acad Orthop Surg 2013;21:268-75.
8. Seror P. Anterior interosseous nerve lesions: clinical and electrophysiological features. J Bone Joint Surg Br 1996;78:238-41.
9. Dunn AJ, Salonen DC, Anastakis DJ. MR imaging findings of anterior interosseous nerve lesions. Skeletal Radiol 2007;36:1155-62.
10. Schantz K, Riegels-Nielsen P. The anterior interosseous nerve syndrome. J Hand Surg Br 1992;17:510-2.


https://doi.org/10.5397/cise.2022.00899

CiSE
Clinics in Shoulder and Elbow

# Instructions to authors

Enacted from June 1, 2009
Revised on December 31, 2010
June 1, 2013
March 1, 2014
May 13, 2014
September 1, 2017
March 1, 2019
December 1, 2019
November 30, 2022
April 18, 2023

## 1. GENERAL INFORMATION

*Clinics in Shoulder and Elbow* (Clin Shoulder Elbow, CiSE) is an international, peer-reviewed journal and the official journal of Korean Shoulder and Elbow Society. It was first launched in 1998. It is published quarterly on the first day of March, June, September, and December, with articles in English, and has been published as an online-only journal since 2019.

The aims of CiSE are first to contribute to the management and education of shoulder and elbow topics; second, to share the latest scientific information among international societies; and finally to promote communications on shoulder/elbow problems and patient care. It can cover all fields of clinical and basic researches in shoulder and elbow.

Manuscripts submitted to CiSE should be prepared according to the following instructions. CiSE follows the Recommendations for the Conduct, Reporting, Editing, and Publication of Scholarly Work in Medical Journals (http://www.icmje.org/icmje-recommendations.pdf) from the International Committee of Medical Journal Editors (ICMJE).

## 2. ARTICLE PROCESSING CHARGE

There are no author fees required for manuscript processing and/or publishing materials in the journal since all cost is supported by the publisher, the Korean Shoulder and Elbow Society until there is a policy change. Therefore, it is the so-called platinum open-access journal.

## 3. RESEARCH AND PUBLICATION ETHICS

The journal adheres to the guidelines for research and publication described in the Committee on Publication Ethics (COPE) Guidelines (https://publicationethics.org/resources/guidelines), the ICMJE Recommendations (https://www.icmje.org), and the Good Publication Practice Guideline for Medical Journals (https://www.kamje.or.kr/board/view?b_name=bo_publication&bo_id=13). Furthermore, all processes addressing research and publication misconduct shall follow the flowchart of COPE (https://publicationethics.org/resources/flowcharts). Any attempts to duplicate publications or engage in plagiarism will lead to automatic rejection and may prejudice the acceptance of future submissions.

### Statement of Human and Animal Rights

Clinical research should be conducted in accordance with the World Medical Association's Declaration of Helsinki (https://www.wma.net/what-we-do/medical-ethics/declaration-of-helsinki/). Any investigations involving humans and animals should be approved by the Research Ethics Committee (REC) or the Institutional Review Board (IRB) and Animal Care Committee, respectively, of the institution where the experiment was performed. CiSE will not consider any studies involving humans or animals without appropriate approval. Such approval, the approval number, and IRB or REC institution name should be stated in the Methods section of the manuscript. Informed consent should be obtained, unless waived by the IRB, from patients who participated in clinical investigations. In the case of an animal study, a statement should be provided indicating that the experiment process, such as the breeding and the use of laboratory animals, was approved by the REC of the institution where the experiment was performed or that it does not violate the rules of the REC of the institution or the NIH Guide for the Care and Use of Laboratory Animals (Institute of Laboratory Animal Resources, Commission on Life Sciences, National Research Council). The authors should preserve raw experimental study data for at least 1 year after the publication of the paper and should present this data if required by the editorial board.

### Protection of Privacy, Confidentiality, and Written Informed Consent

The ICMJE has recommended the following statement for the protection of privacy, confidentiality, and written informed consent: The rights of patients should not be infringed without written informed consent. Identifying details (patient's names, initials, hospital numbers, dates of birth, or other personal or identifying information, protected healthcare information) should not be published in written descriptions. Images of human subjects should not be used unless the information is essential for scientific purposes and explicit permission has been given as part of the consent. Even where consent has been given, identifying details should be omitted if they are not essential. If identifying characteristics are altered to protect anonymity, authors should provide assurances that such alterations do not distort scientific meaning. If consent has not been obtained, it is generally not sufficient to anonymize a photograph simply by using eye bars or blurring the face of the individual concerned.

### Conflict of Interest

The author is responsible for disclosing any financial support or benefit that might affect the content of the manuscript or might cause a conflict of interest. When submitting the manuscript, the author must attach the letter of conflict of interest statement (http://cisejournal.org/authors/copyright_transfer_agreement.php). All authors should disclose their conflicts of interest, i.e., (1) financial relationships (such as employment, consultancies, stock ownership, honoraria, paid expert testimony), (2) personal relationship, (3) academic competition, and (4) intellectual passion. These conflicts of interest must be included as a footnote on the title page. Each author should certify the disclosure of any conflict of interest with his/her signature.

### Originality, Plagiarism, and Duplicate Publication

Redundant or duplicate publication refers to the publication of a paper that overlaps substantially with one already published. Upon receipt, submitted manuscripts are screened for possible plagiarism or duplicate publication using Crossref Similarity Check. If a paper that might be regarded as duplicate or redundant had already been published in another journal or submitted for publication, the author should notify the fact in advance at the time of submission. Under these conditions, any such work should be referred to and referenced in the new paper. The new manuscript should be submitted together with copies of the duplicate or redundant material to the editorial committee. If redundant or duplicate publication is attempted or occurs without such notification, the submitted manuscript will be rejected immediately. If the editor was not aware of the violations and of the fact that the article had already been published, the editor will announce in the journal that the submitted manuscript had already been published in a duplicate or redundant manner, without seeking the author's explanation or approval.

### Secondary Publication

It is possible to republish manuscripts if the manuscripts satisfy the conditions for secondary publication of the ICMJE Recommendations, available from: https://www.icmje.org/ as follows:

(1) Certain types of articles, such as guidelines produced by governmental agencies and professional organizations, may need to reach the widest possible audience. In such instances, editors sometimes deliberately publish material that is also published in other journals with the agreement of the authors and the editors of those journals.

(2) Secondary publication for various other reasons, in the same or another language, especially in other countries, is justifiable and can be beneficial provided that the following conditions are met. The authors have received approval from the editors of both journals (the editor concerned with secondary publication must have a photocopy, reprint, or manuscript of the primary version). The priority of the primary publication is respected by a publication interval of at least one week (unless specifically negotiated otherwise by both editors).

(3) The paper for secondary publication is intended for a different group of readers; therefore, an abbreviated version could be sufficient. The secondary version faithfully reflects the data and interpretations of the primary version. The footnote on the title page of the secondary version informs readers, peers, and documenting agencies that the paper has been published in whole or in part and states the primary reference. A suitable footnote might read: "This article is based on a study first reported in the [title of a journal, with full reference]."

### Authorship

Authorship credit should be based on one's contribution substantially to all four categories established by the International Committee of Medical Journal Editors (ICMJE): (1) substantial contributions to conception or design of the work, acquisition of data, and analysis and in-terpretation of data; (2) drafting the work or revising it critically for important intellectual content; (3) final approval of the version to be published; and (4) agreement to be accountable for all aspects of the work in ensuring that questions related to the accuracy or integrity of any part of the work are ap-

propriately investigated and resolved.

- The contributions of all authors must be described. CiSE has adopted the CRediT Taxonomy (https://credit.niso.org/) to describe each author's individual contributions to the work. The role of each author should be addressed on the title page.
- Correction of authorship: Any requests for such changes in authorship (adding author(s), removing author(s), or re-arranging the order of authors) after the initial manuscript submission and before publication should be explained in writing to the editor in a letter or e-mail from all authors. This letter must be signed by all authors of the paper. A copyright assignment must be completed by every author.
- Role of corresponding author: The corresponding author takes primary responsibility for communication with the journal during the manuscript submission, peer review, and publication process. The corresponding author typically ensures that all of the journal's administrative requirements, such as providing the details of authorship, ethics committee approval, clinical trial registration documentation, and conflict of interest forms and statements, are properly completed, although these duties may be delegated to one or more co-authors. The corresponding author should be available throughout the submission and peer review process to respond to editorial queries in a timely manner, and after publication, should be available to respond to critiques of the work and cooperate with any requests from the journal for data or additional information or questions about the article.
- Contributors: Any researcher who does not meet all four ICMJE criteria for authorship discussed above but contributes substantively to the study in terms of idea development, manuscript writing, conducting research, data analysis, and financial support should have their contributions listed in the Acknowledgments section of the article.

### Process for Managing Research and Publication Misconduct

When the journal faces suspected cases of research and publication misconduct, such as redundant (duplicate) publication, plagiarism, fraudulent or fabricated data, changes in authorship, undisclosed conflict of interest, ethical problems with a submitted manuscript, appropriation by a reviewer of an author's idea or data, and complaints against editors, the resolution process will follow the flowchart provided by COPE (http://publicationethics.org/resources/flowcharts). The discussion and decision on the suspected cases are carried out by the Editorial Board.

### Editorial Responsibilities

The Editorial Board will continuously work to monitor and safeguard publication ethics: guidelines for retracting articles; maintenance of the integrity of academic records; preclusion of business needs from compromising intellectual and ethical standards; publishing corrections, clarifications, retractions, and apologies when needed; and excluding plagiarized and fraudulent data. The editors maintain the following responsibilities: responsibility and authority to reject and accept articles; avoid any conflict of interest with respect to articles they reject or accept; promote the publication of corrections or retractions when errors are found; and preserve the anonymity of reviewers.

## 4. EDITORIAL POLICY

### Copyright

Copyright in all published material is owned by the Korean Shoulder and Elbow Society. Authors must agree to transfer copyright (http://cisejournal.org/authors/copyright_transfer_agreement.php) during the submission process. The corresponding author is responsible for submitting the copyright transfer agreement to the publisher. In addition, if excerpts from other copyrighted works are included, the authors must obtain written permission from the copyright owners and credit the sources in the article.

### Open-Access License

CiSE is an open-access journal. Articles are distributed under the terms of the Creative Commons Attribution License (http://creativecommons.org/licenses/by-nc/4.0/), which permits unrestricted non-commercial use, distribution, and reproduction in any medium, provided the original work is properly cited. Author(s) do not need permission to use tables or figures published in CiSE in other journals, books, or media for scholarly and non-commercial purposes. For any commercial use of material from this open-access journal, permission must be obtained from Korean Shoulder and Elbow Society (E-mail: journal@cisejournal.org).

### Article Sharing (Author Self-Archiving) Policy

CiSE is an open-access journal, and authors who submit manuscripts to CiSE can share their research in several ways, including on preprint servers, social media platforms, at conferences, and in educational materials, in accordance with our open-access policy. However, it should be noted that submitting the same manuscript to multiple journals is strictly prohibited.

### Registration of Clinical Trial Research

It is recommended that any research that deals with a clinical trial be registered with a clinical trial registration site, such as http://

cris.nih.go.kr, or other primary national registry sites accredited by the World Health Organization (https://www.who.int/clinical-trials-registry-platform/network/primary-registries) or clinicaltrial.gov (http://clinicaltrials.gov/), a service of the United States National Institutes of Health.

### Data Sharing Policy

CiSE encourages data sharing wherever possible unless this is prevented by ethical, privacy, or confidentiality matters. Authors wishing to do so may deposit their data in a publicly accessible repository and include a link to the DOI within the text of the manuscript.

- Clinical Trials: CiSE accepts the ICMJE Recommendations for data sharing statement policy. Authors may refer to the editorial, "Data Sharing Statements for Clinical Trials: A Requirement of the International Committee of Medical Journal Editors," in the Journal of Korean Medical Science (https://dx.doi.org/10.3346/jkms.2017.32.7.1051).

### Archiving Policy

In accordance with the Korean Library Act, the full text of the CiSE can be archived in the National Library of Korea (https://seoji.nl.go.kr/archive). CiSE provides electronic archiving and preservation of access to the journal content in the event the journal is no longer published, by archiving in the National Library of Korea (https://www.nl.go.kr/archive/search.do) and the National Library of Korea can permanently preserve submitted CiSE papers.

### Preprint Policy

A preprint can be defined as a version of a scholarly paper that precedes formal peer review and publication in a peer-reviewed scholarly journal. CiSE allows authors to submit preprints to the journal. It is not treated as duplicate submission or duplicate publication publication. CiSE recommends that authors disclose the existence of a preprint with its DOI in the letter to the Editor during the submission process. Otherwise, a plagiarism check program—Similarity Check (Crosscheck) or Copy Killer—may flag the results as containing excessive duplication. A preprint submission will be processed through the same peer-review process as a usual submission. If a preprint is accepted for publication, the authors are recommended to update the information on the preprint site with a link to the published article in CiSE, including the DOI at CiSE. It is strongly recommended that authors cite the article in CiSE instead of the preprint in their next submission to journals.

## 5. MANUSCRIPT SUBMISSION AND PEER-REVIEW PROCESS

### Online Submission

All manuscripts should be submitted online via the journal's website (https://submit.cisejournal.org/) by the corresponding author. Once you have logged into your account, the online system will lead you through the submission process in a stepwise orderly process. Submission instructions are available at the website. All articles submitted to the journal must comply with these instructions. Failure to do so will result in the return of the manuscript and possible delay in publication. In case of any trouble, please contact the editorial office (E-mail: journal@cisejournal.org).

### Screening after Submission

Screening process will be conducted after submission. If the manuscript does not fit the aims and scope of the Journal or does not adhere to the Instructions to authors, it may be returned to the author immediately after receipt and without a review. Before reviewing, all submitted manuscripts are inspected by "Similarity Check powered by iThenticate (https://www.crossref.org/services/similarity-check/), a plagiarism-screening tool. If a too high a degree of similarity score is found, the Editorial Board will do a more profound content screening. The criterion for similarity rate for further screening is usually 25%; however, the excess amount of similarity in specific sentences may be also checked in every manuscript. The settings for Similarity Check screening are as follows: It excludes quotes, a bibliography, small matches of 6 words, small sources of 1%, and the Methods section.

### Peer-Review Process

All papers, including those invited by the Editor, are subject to peer review. Manuscripts will be peer-reviewed by two accredited experts in the shoulder and elbow with one additional review by prominent member from our editorial board. The editor is responsible for the final decision whether the manuscript is accepted or rejected.

- The journal uses a double-blind peer review process: the reviewers do not know the identity of the authors, and vice versa. During the peer review process, reviewers can interact directly or exchange information (e.g., via submission systems or email) with only an editor, which is known as "independent review."
- CiSE's average turnaround time from submission to decision is 4 weeks.
- Decision letter will be sent to corresponding author via registered e-mail. Reviewers can request authors to revise the con-

tent. The corresponding author must indicate the modifications made in their item-by-item response to the reviewers' comments. Failure to resubmit the revised manuscript within 4 weeks of the editorial decision is regarded as a withdrawal.

- The editorial committee has the right to revise the manuscript without the authors' consent, unless the revision substantially affects the original content.
- After review, the editorial board determines whether the manuscript is accepted for publication or not. Once rejected, the manuscript does not undergo another round of review.
- All articles in CiSE include the dates of submission, revision, acceptance, and publication on their article page. No information about the review process or editorial decision process is published on the article page.

### Submission by Editors

All manuscripts from editors, employees, or members of the editorial board are processed in the same way as other unsolicited manuscripts. During the review process, submitters will not engage in the selection of reviewers or the decision process. Editors will not handle their manuscripts even if the manuscripts are commissioned.

The conflict of interest declaration should be added as follows.

Conflicts of Interest: OOO has been an editorial board member of Clinics in Shoulder and Elbow since OOO but has no role in the decision to publish this article. No other potential conflicts of interest relevant to this article were reported.

### Feedback after Publication

If the authors or readers find any errors, or contents that should be revised, it can be requested from the Editorial Board. The Editorial Board may consider erratum, corrigendum or a retraction. If there are any revisions to the article, there will be a CrossMark description to announce the final draft. If there is a reader's opinion on the published article with the form of Letter to the editor, it will be forwarded to the authors. The authors can reply to the reader's letter. Letter to the editor and the author's reply may be also published.

### Appeals of Decisions

Any appeal against an editorial decision must be made within 2 weeks of the date of the decision letter. Authors who wish to appeal a decision should contact the Editor-in-Chief, explaining in detail the reasons for the appeal. All appeals will be discussed with at least one other associate editor. If consensus cannot be reached thereby, an appeal will be discussed at a full editorial meeting. The process of handling complaints and appeals follows the guidelines of COPE available from (https://publicationethics.org/appeals). CiSE does not consider second appeals.

## 6. MANUSCRIPT PREPARATION

Authors are required to submit their manuscripts after reading the following instructions. Any manuscript that does not conform to the following requirements will be considered inappropriate and may be returned.

### General Requirements

- All manuscripts should be written in English.
- The manuscript must be written using Microsoft Word and saved as ".doc" or ".docx" file format. The font size must be 12 points. The body text must be left-aligned, double-spaced, and presented in one column. The left, right, and bottom margins must be 3 cm, but the top margin must be 3.5 cm.
- The page numbers must be indicated in Arabic numerals in the middle of the bottom margin, starting from the abstract page.
- Neither the authors' names nor their affiliations should appear on the manuscript pages.
- Only standard abbreviations should be used. Abbreviations should be avoided in the title of the manuscript. Abbreviations should be spelled out when first used in the text and the use of abbreviations should be kept to a minimum.
- The names of manufacturers of equipment and non-generic drugs should be given.
- Authors should express all measurements in conventional units using International System (SI) units.
- P-value from statistical testing is expressed as capital P.

### Reporting Guidelines for Specific Study Designs

For the specific study design, it is recommended that authors follow the reporting guidelines, such as CONSORT (http://www.consort-statement.org) for randomized controlled trials, STROBE (http://www.strobe-statement.org) for observational studies, PRISMA (http://www.prisma-statement.org) for systematic reviews and meta-analyses, and CARE (https://www.care-statement.org) for case reports. A good source of reporting guidelines is the EQUATOR Network (https://www.equator-network.org/) and NLM (https://www.nlm.nih.gov/services/research_report_guide.html).

### Types of Manuscripts

- The manuscript types are divided into Original Articles, Review Articles, Case Reports, and other types.
- **Original Article:** Original articles should be written in the fol-

lowing order: title page, abstract(within 250 words), keywords, main body (introduction, methods, results, discussion, and conclusions), acknowledgments (if necessary), references (up to 30), tables, figure legends, and figures.

- **Review Articles:** Review articles should focus on a specific topic. The format of a review article is not limited. Publication of these articles will be decided upon by the Editorial Board.
- **Case Reports:** Case reports should be written in the following order: title page, abstract (within 200 words), keywords, main body (introduction, case report, and discussion), acknowledgments (if necessary), references (up to 10), tables, figure legends, and figures.
- **Technical Notes:** Technical notes should be written in the following order: title page, abstract (within 150 words), keywords, main body (introduction, technique, and discussion), acknowledgments (if necessary), references (up to 10), tables (if applicable), figure legends, and figures and should not exceed 1,500 words. A maximum of 3 figures and 1 table are allowed.
- **Letters to the Editor:** The journal welcomes readers' comments on articles published recently in the journal or orthopedic topics of interest. Letters to the editor should not exceed 1,000 words, excluding references, tables, and figures. A maximum of 5 references and total 4 figures or tables are allowed.
- **Editorial:** Editorials are invited by the editors and should be commentaries on articles published recently in the journal. Editorial topics could include active areas of research, fresh insights, and debates in the field of orthopedic surgery. Editorials should not exceed 1,000 words, excluding references, tables, and figures. A maximum of 10 references and total 4 figures or tables are allowed.
- **Current Concepts:** Current concepts deal with most current trends and controversies of a single topic in shoulder and elbow. Authors are recommended to update all the knowledge to most recent studies and researches.
- **Systematic Review:** Systematic review examines published material on a clearly described subject in a systematic way. There must be a description of how the evidence on this topic was tracked down, from what sources and with what inclusion and exclusion criteria.
- **Meta-analysis:** A systematic overview of studies that pools the results of two or more studies to obtain an overall answer to a question or interest. Summarizes quantitatively the evidence regarding a treatment, procedure, or association.
- **Concise Review:** Concise review is a short version of a systemic review requested to submit to the journal by the Editorial board. Usually, previous papers regarding such topics were published by the main author(s).
- Special Reports/Expert Opinions (Level V studies) of various topics on shoulder and elbow can be submitted. They are limited to 2,700 words excluding references, tables, and figures.

Recommended maximums for articles submitted to CiSE*

| Type of article | Abstract (word) | Text (word)† | References | Tables & Figures |
|---|---|---|---|---|
| Original Article | Structured, 250 | NL | 30 | NL |
| Review | Unstructured, 250 | NL | NL | NL |
| Case Report | Unstructured, 200 | 1,500 | 15 | NL |
| Technical Note | Unstructured, 150 | 1,500 | 10 | 1 Table/ 3 Figures |
| Letter to the Editor | - | 1,000 | 5 | 4 |
| Editorial | - | 1,000 | 10 | 4 |
| Current Concepts | Unstructured, 250 | NL | NL | NL |

NL, no limits.

*The requirements for the number of references, tables and figures and length of the main text can be consulted with the Editorial Office; †Not including an abstract, tables, figures, acknowledgments, and references.

## Format of Manuscript

### Title page

- The title page must include a title, the authors' names, affiliations, and corresponding authors' names and contact information. In addition, a running title must be written within up to 50 characters including spaces. The corresponding authors' contact information must include a name, addresses, e-mails, telephone numbers, and fax numbers.
- ORCID: We recommend that the open researcher and contributor ID (ORCID) of all authors be provided. To have an ORCID, authors should register in the ORCID website (http://orcid.org/).
- Author contributions: The contributions of all authors must be described using the CRediT (https://credit.niso.org/) taxonomy of author roles.
- Conflict of interest: If there are any conflicts of interest, authors should disclose them in the manuscript. If there are no conflicts of interest, authors should include the following sentence: "No potential conflict of interest relevant to this article was reported."
- Funding: All sources of funding applicable to the study should be stated here explicitly.
- Acknowledgments: Any persons that contributed to the study or the manuscript, but not meeting the requirements of authorship could be placed here. If you do not have anyone to acknowledge, please write "None" in this section.

### Abstract and keywords

Each paper should start with an abstract not exceeding 250 (original articles and reviews), 200 words (case reports), and 150 (technical notes) words. The abstract for original articles should state the background, methods, results, and conclusions in each paragraph in a brief and coherent manner. Relevant numerical data should be included. Under the abstract, keywords should be inserted (maximum 5 words). Authors are recommended to use the MeSH database to find Medical Subject Heading Terms at http://www.nlm.nih.gov/mesh/meshhome.html. The structured abstract should be into the following sections.

- Background: The rationale, importance, or objective of the study should be described briefly and concisely in one to two sentences. The objective should be consistent with that stated in the Introduction.
- Methods: The procedures conducted to achieve the study objective should be described in detail, together with relevant details concerning how data were obtained and analyzed and how research bias was adjusted.
- Results: The most important study results and analysis should be presented in a logical manner with specific experimental data.
- Conclusions: The conclusions derived from the results should be described in one to two sentences, and must match the study objective.
- Level of evidence: Author should make the final determination of the study design and level of evidence based on the Centre for Evidence Based Medicine guidelines. Authors may refer to the definitions in the Level of Evidence table (https://www.cebm.ox.ac.uk/files/levels-of-evidence/cebm-levels-of-evidence-2-1.pdf).

### Main Body

- All articles using clinical samples or data and those involving animals must include information on the IRB/IACUC approval or waiver and informed consent. An example is shown below. "We conducted this study in compliance with the principles of the Declaration of Helsinki. The study's protocol was reviewed and approved by the Institutional Review Board of OO (No. OO). Written informed consent was obtained / Informed consent was waived."
- Description of participants: Ensure the correct use of the terms "sex" (when reporting biological factors) and "gender" (identity, psychosocial, or cultural factors), and, unless inappropriate, report the sex and/or gender of study participants, the sex of animals or cells, and describe the methods used to determine sex and gender. If the study was done involving an exclusive population, for example, in only one sex, authors should justify why, except in obvious cases (e.g., ovarian cancer). Authors should define how they determined race or ethnicity and justify their relevance.
- Introduction: State the background or problem that led to the initiation of the study. Introduction is not a book review, rather it is best when the authors bring out controversies which create interest. Lead systematically to the hypothesis of the study, and finally, to a restatement of the study objective, which should match that in the Abstract. Do not include conclusions in the Introduction.
- Methods: Describe the study design (prospective or retrospective, inclusion and exclusion criteria, duration of the study) and the study population (demographics, length of follow-up). Explanations of the experimental methods should be concise, yet enable replication by a qualified investigator.
- Results: This section should include detailed reports on the data obtained during the study. All data in the text must be presented in a consistent manner throughout the manuscript. All issues which the authors brought up in the method section need to be in result section. Also, it is preferred that data be in figures or tables rather than a long list of numbers. Instead, numbers should be in tables or figures with key comments on the findings.
- Discussion: The first paragraph of the discussion should deal with the key point in this study. Do not start with an article review or general comment on the study topic. In the Discussion, data should be interpreted to demonstrate whether they affirm or refute the original hypothesis. Discuss elements related to the purpose of the study and present the rationales that support the conclusion drawn by referring to relevant literature. Discussion needs some comparison of similar papers published previously, and discuss why your study is different or similar from those papers. Care should be taken to avoid information obtained from books, historical facts, and irrelevant information. A discussion of study weaknesses and limitations should be included in the last paragraph of the discussion.
- Conclusions: Briefly state the answer to your question or hypothesis in the Introduction. Describe carefully to draw conclusions only from your results and verify that your data firmly support your conclusions. The conclusions in the text and those in the abstract must have the same content.
- References must be numbered with superscripts according to their quotation order. When more than two quotations of the same authors are indicated in the main body, a comma must be placed between a discontinuous set of numbers, whereas a dash must be placed between the first and last numerals of a continuous set of numbers: "Kim et al. [2,8,9] insisted…" and "However,

Park et al. [11-14] showed opposing research results."

- Figures and tables used in the main body must be indicated as "Fig." and "Table." For example, "Magnetic resonance imaging of the brain revealed… (Figs. 1-3).

## References

- The number of references is recommended to be 30 for original articles and 10 for case reports and technical notes.
- All references must be cited in the text. The number assigned to the reference citation is according to the first appearance in the manuscript. References in tables or figures are also numbered according to the appearance order. Reference numbers in the text, tables, and figures should in a bracket ([ ]).
- List names of all authors when six or fewer. When seven or more, list only the first three names and add et al.
- Authors should be listed by surname followed by initials.
- The journals should be abbreviated according to the style used in the list of journals indexed in the NLM Journal Catalog (http://www.ncbi.nlm.nih.gov/nlmcatalog/journals).
- The overlapped numerals between the first page and the last page must be omitted (e.g., 2025-6).
- References to unpublished material, such as personal communications and unpublished data, should be noted within the text and not cited in the References. Personal communications and unpublished data must include the individual's name, location, and date of communication.
- Examples of references are as follows:

### *Journal article*

1. Annaniemi JA, Pere J, Giordano S. Platelet-rich plasma versus corticosteroid injections for rotator cuff tendinopathy: a comparative study with up to 18-month follow-up. Clin Shoulder Elb 2022;25:28-35.
2. Kovacevic D, Fox AJ, Bedi A, et al. Calcium-phosphate matrix with or without TGF-β3 improves tendon-bone healing after rotator cuff repair. Am J Sports Med 2011;39:811-9.
3. Nord KD, Masterson JP, Mauck BM. Superior labrum anterior posterior (SLAP) repair using the Neviaser portal. Arthroscopy 2004;20 Suppl 2:129-33.
4. Rohner E, Jacob B, Bohle S, et al. Sodium hypochlorite is more effective than chlorhexidine for eradication of bacterial biofilm of staphylococci and Pseudomonas aeruginosa. Knee Surg Sports Traumatol Arthrosc 2020 Feb 7 [Epub]. https://doi.org/10.1007/s00167-020-05887-9

### *Book & book chapter*

5. Iannotti JP, Williams Jr GR. Disorders of the shoulder: diagnosis & management. 2nd ed. Lippincott Williams & Wilkins; 2007. p. 66-80.
6. Provencher MP, LeClere LE, Van Thiel GS, et al. Posterior instability of the shoulder. In: Angelo RL, Esch JC, Ryu RK, eds. AANA advanced arthroscopy the shoulder. Saunders; 2010. p. 115-23.

### *Website*

7. American Cancer Society. Cancer facts & figures 2022 [Internet]. American Cancer Society; 2020 [cited 2023 Mar 5]. Available from: https://www.cancer.org/research/cancer-facts-statistics/all-cancer-facts-figures/cancer-facts-figures-2022.html

## Figures and Figure Legends

Figures should be cited in the text and numbered using Arabic numbers in the order of their citation (e.g., Fig. 1). Figures are not embedded within the text. Each figure should be submitted as an individual file. The location of figure legends begins on the next page after the last table. Every figure has its own legend. Abbreviations and additional information for any clarification should be described within each figure legend. The description of footnotes below the figure should follow the order of that of abbreviation and then symbols. Symbols should be marked in the following order: *, †, ‡, §, ||, ¶, **, ††, ‡‡. Figure files are submitted in EPS, TIFF, or PDF formats. The requirement for minimum resolutions is dependent on figure types. For line drawings, 1,200 dpi are required. For grey color works (i.e., pictures of gel or blots), 600 dpi is required. For color or half-tone artwork, 300 dpi is required. The files are named by the figure number.

- Staining techniques used should be described. Photomicrographs with no inset scale should have the magnification of the print in the legend.
- Papers containing unclear photographic prints may be rejected.
- Remove any writing that could identify a patient.
- A previously published figure should be accompanied by a footnote acknowledging the original source and the consent of the copyright holder.

## Tables

- Tables should be numbered sequentially with Arabic numerals in the order in which they are mentioned in the text.
- If an abbreviation is used in a table, it should be defined in a footnote below the table.
- The symbols should be used in the following order: *, †, ‡, §, ||, ¶, **, ††, ‡‡. Each symbol must be defined in a footnote.
- Tables should be understandable and self-explanatory, without references to the text.

- If a table has been previously published should be accompanied by the written consent of the copyright holder and the footnote must acknowledge the original source.

## 6. MANUSCRIPT PROCESSING AFTER ACCEPTANCE

### Final Version

After the paper has been accepted for publication, the author(s) should submit the final version of the manuscript. The names and affiliations of the authors should be double-checked, and if the originally submitted image files were of poor resolution, higher-resolution image files should be submitted at this time. Symbols (e.g., circles, triangles, squares), letters (e.g., words, abbreviations), and numbers should be large enough to be legible on reduction to the journal's column widths. All symbols must be defined in the figure caption. If references, tables, or figures are moved, added, or deleted during the revision process, renumber them to reflect such changes so that all tables, references, and figures are cited in numeric order.

### Manuscript Corrections

Before publication, the manuscript editor will correct the manuscript such that it meets the standard publication format. The author(s) must respond within two days when the manuscript editor contacts the corresponding author for revisions. If the response is delayed, the manuscript's publication may be postponed to the next issue.

### Gallery Proof

The author(s) will receive the final version of the manuscript as a PDF file. Upon receipt, the author(s) must notify the editorial office (or printing office) of any errors found in the file within two days. Any errors found after this time are the responsibility of the author(s) and will have to be corrected as an erratum.

### Errata and Corrigenda

To correct errors in published articles, the corresponding author should contact the journal's Editorial Office with a detailed description of the proposed correction. Corrections that profoundly affect the interpretation or conclusions of the article will be reviewed by the editors. Corrections will be published as corrigenda (corrections of the author's errors) or errata (corrections of the publisher's errors) in a later issue of the journal.

CiSE
Clinics in Shoulder and Elbow

# Author's checklist

- ☐ Manuscript in MS-WORD (DOC, DOCX) format.
- ☐ Double-spaced typing with 10-point font.
- ☐ Sequence of title page, abstract and keywords, introduction, methods, results, discussion, conclusions, acknowledgments, references, tables, and figure legends. All pages and manuscript text with line should be numbered sequentially, starting from the abstract.
- ☐ Title page with article title, authors' full name(s) and affiliation(s), address for correspondence (including telephone number, e-mail address, and fax number), running title (less than 10 words), and acknowledgments, if any.
- ☐ Abstract in structured format up to 250 words for original articles and in unstructured format up to 200 words for case reports. Keywords (up to 5) from the MeSH list of Index Medicus.
- ☐ All table and figure numbers are found in the text.
- ☐ Figures as separate files, in JPG, GIF, or PPT format.
- ☐ References listed in proper format. All references listed in the reference section are cited in the text and vice versa.
- ☐ Covering letter signed by the corresponding author.

# Copyright transfer agreement

CiSE
Clinics in Shoulder and Elbow

*Clinics in Shoulder and Elbow* requires a formal written Copyright Transfer Form of the author(s) for each article published. We therefore ask you to complete and return this form, retaining a copy for your records. Your cooperation is essential and appreciated. Publication cannot proceed without a signed copy of this agreement. If the manuscript is not published in Clinics in Shoulder and Elbow, this agreement shall be null and void.

**Copyright Transfer Agreement.** I/we have read and agreed with the terms and conditions stated on this page of this agreement. I/we hereby confirm the transfer of all copyrights in and relating to the manuscript, in all forms and media of expression now known or developed in the future, including reprints, translations, photographic reproductions, microform, electronic form (offline, online) or any other reproductions of similar nature, to Korean Shoulder and Elbow Society, effective from the date stated below. I/we acknowledge that Korean Shoulder and Elbow Society are relying on this agreement in publishing the manuscript.

**Manuscript Title:**

**Manuscript Number (if applicable):**

**Date:**

All authors appearing in manuscript should be signed in order.

Each of the undersigned is an author of the manuscript and all authors are named on this document.

| Print Name | Signature |
|---|---|
| | |
| | |
| | |
| | |
| | |
| | |
| | |
| | |
| | |